

**PEDIATRIC UROLOGY CASE REPORTS**

ISSN 2148-2969

<http://www.pediatricurologycasereports.com>**A Case of foreign body granuloma after Plastibell® circumcision****Nirmitha Jayaratne¹, Ahmad Zaghal¹, Justin Weir², Muhammad Choudhry¹**¹*Pediatric Surgical Department, Chelsea and Westminster Hospital NHS Foundation Trust, London, UK*²*Charing Cross Hospital, Imperial College Healthcare NHS Trust, London, UK***ABSTRACT**

Male circumcision is one of the most commonly performed surgical procedures and the Plastibell® device is a popular method used to perform circumcisions in neonates and young children. We report a case of a 9-year-old otherwise healthy boy who developed foreign body granulomas following Plastibell® circumcision which was carried out in the community by a medically trained practitioner. His post-operative course was complicated by a retained Plastibell® ring and development of multiple non-healing wounds and granulomas. This patient underwent a semi-elective examination under general anesthesia, wound exploration and re-do modified circumcision. At 4 month follow up the wound was well healed without scarring and the patient reported a normal single straight stream urinary flow.

Key Words: Circumcision; Plastibell® ring; foreign body; granuloma; technique; complication.

Copyright © 2018 pediatricurologycasereports.com

*Corresponding Author: Dr. Nirmitha Jayaratne
Pediatric Surgical Department, Chelsea and Westminster Hospital NHS Foundation Trust, London, SW10 9NH, UK
E-mail: nim-1@hotmail.co.uk
Accepted for publication: 20 November 2017*

Introduction

Male circumcision is the process of surgical removal of the prepuce (foreskin), done either in whole or in part. It is one of the most common surgical procedures performed all around the world [1]. Plastibell® device is a popular method used to perform circumcisions, especially in a surgical outpatient or community setting.

We report a case of foreign body granuloma formation following Plastibell® circumcision,

a rare complication that has not previously been reported.

Foreign body granulomas are usually a reaction to exogenous materials, which have a non-immune mechanism [1]. Microscopically; foreign body granuloma to suture material (nylon, silk) contains multinucleated giant cells, with haphazardly arranged nuclei. These giant cells are fused macrophages. The foreign body is birefringent, and sometimes may be visible by polarized light in the middle of the granuloma or inside the giant cells. These granulomas are non-necrotic [2].

This case report highlights the presentation and management of this rare complication after a relatively routine and frequently performed operation.

Case report

A 9-year-old otherwise healthy male patient was seen in an outpatient clinic in the department of Pediatric Surgery, six months after undergoing Plastibell® circumcision in the community performed by his general practitioner (i.e. a medically trained practitioner) for cultural reasons.

Post-operatively, the patient experienced a retained Plastibell® ring (retained for two weeks following the procedure) and subsequently required manual removal in the community by the practitioner who initially performed the procedure. Unfortunately, he continued to have grey/yellow colored discharge with a non-healing wound and swelling despite removal of the Plastibell ring and multiple courses of antibiotics. He fortunately did not develop any urinary problems and reported having a single straight stream from the external urethral orifice.

The patient presented to our department due to persistent multiple non-healing discharging wounds on the penile skin [Fig. 1a-c]. On physical examination, patient was found to have multiple discharging sinuses adjacent/proximal to the corona with marked inflammation, tissue swelling, induration and obvious granulation tissue at the circumcision wound proximal to corona. The impression of the Plastibell® device was visible on the glans, which suggested that the Plastibell device used was too small for this child. The patient was systemically well and the rest of the genitourinary examination was unremarkable. This patient underwent a semi-elective examination under general anesthesia, wound exploration and redo modified circumcision 26 weeks post-operatively. Intra-operatively, a retained foreign body (retained thread used to tie the foreskin on the Plastibell® device) was discovered encircling the penis along with

multiple granulomas on the penile skin with multiple abscesses [Fig. 1a-c].

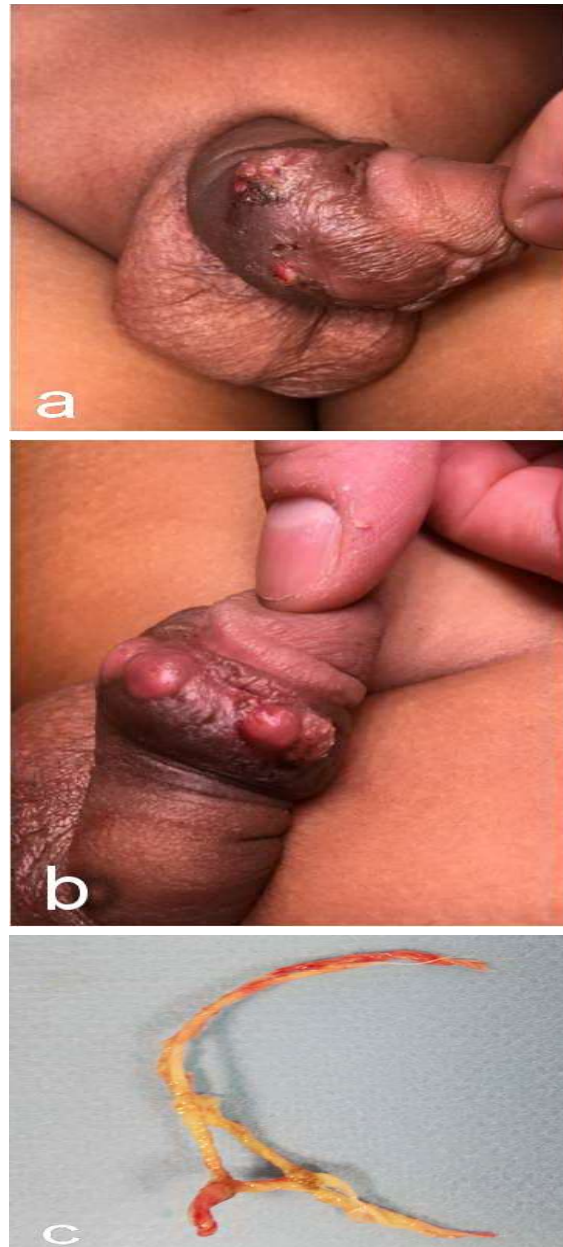


Fig. 1. a) This photograph depicts the appearance of the penis at the time of presentation to clinic 6 months following the original circumcision. There were multiple non-healing discharging wounds on the penile skin along with significant swelling. **b)** This photo clearly shows the multiple discharging sinuses adjacent to the corona with multiple granulomas and abscesses on the penile skin. **c)** Retained thread used to tie the foreskin on the Plastibell® device.

The affected skin was excised and wound was cleaned. There was slight urethral dilatation observed proximal to this encircling foreign body, however no urethral stricture was noted. The cleaned edges of the skin were sutured together using 4/0 synthetic absorbable polyglycolic suture with interrupted sutures [Fig. 2].



Figure 2: The photograph depicts the final appearance of the penis immediately post-operatively. The patient underwent a redo-modified circumcision with removal of foreign body and excision of affected skin. The cleaned edges of the skin was sutured together using 4/0 Vicryl Rapide with interrupted sutures.

The histology of the tissue [Fig. 3] showed that the nodular areas seen macroscopically consist of ulcerated epidermis and underlying granulation tissue and an active chronic inflammatory infiltrate, which extends to the deep aspect of the specimen. There was microabscess [Fig. 3a] formation with a small piece of refractile foreign body material seen within the granulation tissue [Fig. 3b,c] and scar tissue was found in the adjacent dermis. The patient was followed up 10 days post-operatively. During the review, wound was found to be dry and healing well without any

active infection and the edema had markedly reduced.

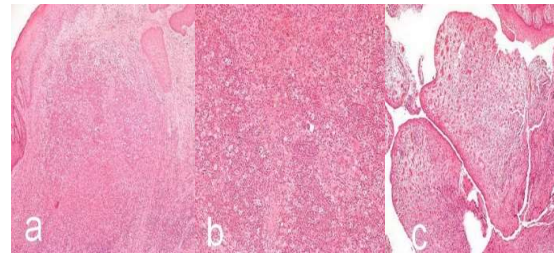


Fig. 3. Histopathology slides. **a)** Abscess. **b)** Abscess and the foreign body (the small central dark purple material). **c)** Granulation Tissue.

Urine flowmetry [Fig. 4] was carried out on the day, which showed a normal urinary flow.

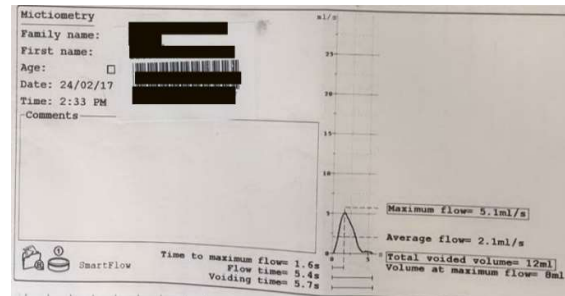


Fig. 4. Urinary Flowmetry study done 10 days post-operatively on 25/2/17.

At 4 month follow-up the wound was well healed without scarring [Fig. 5a,b] and urine flow was a single straight stream.

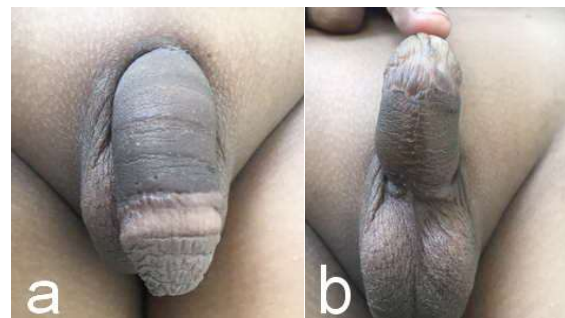


Fig. 5. At 4 month follow-up the wound was well healed without scarring.

Discussion

Circumcision is one of the oldest and most common elective surgical procedures performed with approximately one-third of males aged 15 years and over being circumcised worldwide [1,3]. Male circumcision is performed for various therapeutic indications as well as both cultural and religious reasons. Circumcisions performed for non-therapeutic reasons tend to be performed at a younger age. Incidence of male circumcision varies widely depending on the region of the world, with male circumcision being nearly universal in Islamic countries. United States also has a high prevalence of male circumcision, although recent reports show that the prevalence has been decreasing in the recent years [4]. In contrast, it is a relatively rare practice in Europe, most of Asia and Latin America [5].

The most popular methods of neonatal circumcision include the Plastibell® device, the Gomco clamp, and the Mogen clamp [1]. The Gomco and Mogen clamps work by producing crush injury to the prepuce whilst protecting the glans; the prepuce is then surgically excised. The most common technique used for neonatal circumcision in outpatient clinics is Plastibell® circumcision [1]. Plastibell® circumcision is carried out by both traditional and medically trained persons. The Plastibell® ring device is available in different sizes ranging from 1.1cm to 1.7cm in diameter and needs to be chosen according to the size of the glans of the penis. With this technique, an appropriately sized ring is chosen and applied to the glans after freeing the adhesions between the glans and prepuce. The correct ring size is one that fits two thirds of the glans comfortably. The prepuce then covers the Plastibell® ring and a string is tied firmly around the prepuce, which crushes the prepuce

against the groove in the Plastibell® causing ischaemia of the prepuce [7]. Any excess skin that is protruding beyond the ring is then trimmed off. The prepuce distal to the tied thread sloughs off after necrosis due to the compression against the underlying ring. The ring is expected to fall off along with the necrosed prepuce in 3-7 days and this completes the process of circumcision [6,8]. Common complications of Plastibell® circumcision are peri- or post-operative bleeding, wound infection, incomplete circumcision with redundant prepuce, retained Plastibell® ring and injury to the glans penis [6,9]. Incomplete/delayed separation of the ring occurs if the thread is not appropriately tightened or if the skin is too thick as in older children. If too large a ring is chosen the Plastibell® device can migrate proximally and get impacted, whereas if too small a ring size is chosen tissue necrosis can occur. Palit et al. looked at 1129 infants between 6 and 14 weeks old circumcised by trained nurses using the Plastibell® device in the UK and found that most complications involved problems with the ring [10]. Delayed or incomplete separation of the ring was seen in 2.9% of infants and 0.7% of infants experienced proximal migration of the Plastibell® ring causing herniation of the penile shaft or glans [10]. This highlights the importance of selecting the correct size ring for each individual patient. Interestingly, frequency of complications experienced with the Plastibell® device by neonates and infants are relatively less as compared to older boys [11]. Moosa et al. found that the ratio of complications of circumcision by Plastibell® is significantly higher in infants as compared to neonates and concluded that this is due to newborn babies having thin and soft skin that comes off easily

[7], which was also demonstrated by further studies [12,13]. Simpler nature of the procedure and good healing capabilities in the new born have also been suggested as reasons for low rates of complications amongst neonates. Furthermore, a systematic review looking at the complication rates among male neonates, infants and children following circumcision found that frequency of adverse events are generally higher, and complications more serious, even including penile amputation when circumcision was carried out by non-medically trained providers [11,14].

Conclusion

This case highlights a serious complication of Plastibell[®] circumcision carried out in the community by a medically trained practitioner. Our patient experienced delayed healing and infection with cosmetic consequences to the penis as a result. A potentially serious complication this patient could have experienced is urethral obstruction due to encircling foreign body around the penis. Fortunately in this case the patient was spared of any functional consequences.

This case also highlights that there is an immediate need to improve safety of the procedure through enhanced training for both traditional and medically trained providers including an emphasis on selecting the correct size of device and the most appropriate type of device according to age of the child. Although circumcision is done in a majority of cases due to religious reasons it is a medical procedure with potentially life changing complications for the child if carried out incorrectly; thus there is a definite need for formal guidelines and regulations for carrying out circumcisions to ensure both traditional and medically trained providers are regulated.

Compliance with ethical statements

Conflicts of Interest: None.

Financial disclosure: None.

Consent: All photos were taken with parental consent.

Acknowledgements

Dr Justin Weir – Consultant Histopathologist, Charing Cross Hospital, Imperial College Healthcare NHS Trust-Provision of histopathological report and pictures.

References

- [1]Hirji H, Charlton R, Sarmah S: Male circumcision: a review of the evidence. *JMHG*. 2005; 2(1): 21-30.
- [2]Danciu M, Mihailovici M, Dima A, Cucu C. Foreign Body Granuloma, *Atlas of Pathology*.
<http://www.pathologyatlas.ro/foreign-body-granuloma.php>. Accessed on 20/3/2017
- [3]World Health Organization, Department of Reproductive Health and Research and Joint United Nations Programme on HIV/AIDS (UNAIDS). Male circumcision: Global trends and determinants of prevalence, safety and acceptability. 2007. <http://www.who.int/reproductivehealth/publications/rtis/9789241596169/en/>. Accessed on 23/3/2017
- [4]United States Circumcision Incidence. The circumcision reference library. 2012. <http://www.cirp.org/library/statistics/USA/>. Accessed on 20/3/2017
- [5]Drain PK, Halperin DT, Hughes JP, Klausner JD, Bailey RC. Male circumcision, religion, and infectious diseases: an ecologic analysis of 118 developing countries. *BMC Infect Dis*. 2006; 30;6:172.

- [6]Smith AW, Hebra A, Mansfield JM, Streck CJ. Management of Plastibell circumcision ring migration and glans penis incarceration. *Journal of Pediatric Surgery Case Reports*. 2013;1(7); 186-8.
- [7]Moosa FA, Khan FW, Rao MH. Comparison of complications of circumcision by 'Plastibell device technique' in male neonates and infants. *J Pak Med Assoc*. 2010;60(8):664-7.
- [8]Morris BJ. Circumcision - The Procedure Itself
http://www.circinfo.net/the_procedure_itself.html. Accessed on 26/3/2017
- [9]al-Samarrai AY, Mofti AB, Crankson SJ, Jawad A, Haque K, al-Meshari A. A review of a Plastibell device in neonatal circumcision in 2,000 instances. *Surg Gynecol Obstet*. 1988;167(4):341-3.
- [10]Palit V, Menebhi DK, Taylor I, Young M, Elmasry Y, Shah T. A unique service in UK delivering Plastibell circumcision: review of 9-year results. *Pediatr Surg Int*. 2007;23(1):45-8.
- [11]Weiss HA, Larke N, Halperin D, Schenker I. Complications of circumcision in male neonates, infants and children: a systematic review. *BMC Urol*. 2010;16;10:2.
- [12]Jan IA. Circumcision in babies and children with Plastibell technique: an easy procedure with minimal complications- experience of 316 cases. *Pak J Med Sci*. 2004; 20(3): 175-80.
- [13]Christakis DA, Harvey E, Zerr DM, Feudtner C, Wright JA, Connell FA. A trade-off analysis of routine newborn circumcision. *Pediatrics*. 2000;105(1 Pt 3):246-9.
- [14]Ahmed A, Mbibi NH, Dawam D, Kalayi GD. Complications of traditional male circumcision. *Ann Trop Paediatr*. 1999;19(1):113-7.

