

**PEDIATRIC UROLOGY CASE REPORTS**

ISSN 2148-2969

<http://www.pediatricurologycasereports.com>**A double whammy - epididymal torsion in an undescended testis: A case report**Navyashree C¹,  Aureen DCunha², Sandeep Rai²*Department of General Surgery¹, Pediatric Surgery², K.S. Hegde Medical Academy (NITTE University), India***ABSTRACT**

Isolated epididymal torsion is a very rare cause of an acute scrotum. Anomalies of the epididymis are more commonly encountered with undescended testicles and can predispose to epididymal torsion. Management is similar to that of testicular torsion. We report the case of a 3-year-old boy who presented with an acute scrotum. Immediate surgical exploration revealed an isolated epididymal torsion in an undescended testis, only the second of its kind to be reported so far. The epididymis and testis were salvaged and the testis was fixed in the scrotum. There are multiple learning points from this case report. Firstly, that epididymal torsion is a diagnosis to be considered when exploring an acute scrotum. Secondly, that epididymal torsion even an undescended testis can result in clinical symptoms of an acute scrotum. And finally, that epididymal anomalies encountered during surgery should be tackled appropriately, to prevent retorsion.

Key Words: Acute scrotum, epididymo-testicular dissociation, epididymal torsion.© 2020 [pediatricurologycasereports.com](http://www.pediatricurologycasereports.com) *Dr. Navyashree C**Department of General Surgery, K.S. Hegde Medical Academy (NITTE University, Mangalore), India**E-mail: navya1509@gmail.com**Received: 2020-07-14 / Revisions: 2020-08-03**Accepted: 2020-08-10**Publication Date: 2020-09-01*

undescended testis which was salvaged by timely intervention. Only 6 cases of epididymal torsion have been described in literature to date, [1-4, 6] and only one of these has been in patient with an undescended testis [6].

Introduction

Acute scrotum is an often noted surgical emergency warranting immediate surgical exploration. Torsion of the epididymis is an extremely rare cause, making it an important differential diagnosis to consider. Epididymal anomalies have been found to predispose to torsion, and management is extrapolated from that of a testicular torsion. We report an isolated torsion of the epididymis in an

Case report

A 3-year-old boy presented to the Pediatric Surgical Out-patient department with left hemi-scrotal pain, vomiting and low-grade fever for two days. The parents had not noticed an undescended left testis earlier. Clinical examination revealed erythema, edema and an exquisitely tender left hemi-scrotum, with no inguinal swelling or tenderness. The right hemi-scrotum and testis were normal on

palpation. A clinical diagnosis of a testicular torsion was made and the child was taken up for an emergency scrotal exploration within an hour of presentation. Exploration via a midline scrotal raphe incision revealed edema fluid within the layers of the scrotal wall but no testis was found. Subsequently the inguinal canal was opened to reveal a torted and ischemic epididymis, with a mildly dusky testis (Fig. 1).

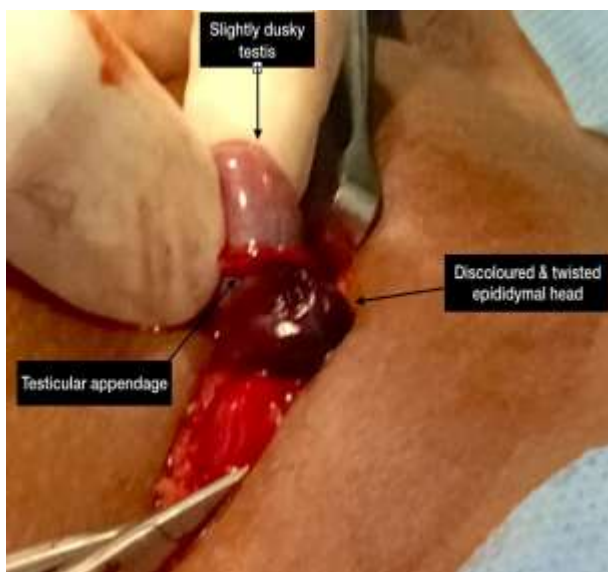


Fig. 1. Operative photograph demonstrating the torsed epididymal head, with a mildly dusky testis and normal testicular appendage.

After untwisting the epididymis, administering 100% oxygen and application of warm saline compress for 10 minutes, the testicular congestion was relieved and the epididymis regained most of its color (Fig. 2).

Epididymo-testicular dissociation (ETD) and a long and tortuous epididymis were noted. The hernial sac was ligated and a left orchidopexy was done. The child had an uneventful recovery and is doing well on follow up.

Discussion

A normal epididymis has its epididymal head firmly attached to the upper pole of the testis

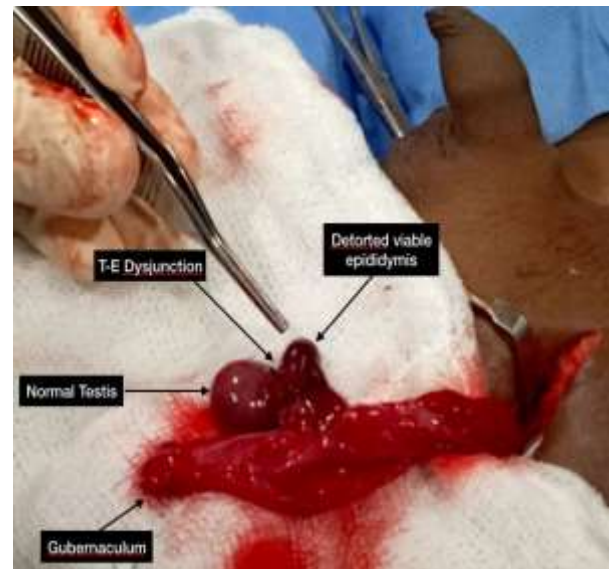


Fig. 2. Operative photograph showing a congested but viable (undescended) testis and epididymis following detorsion, warm saline compress and 100% oxygen.

by the efferent ductules [4]. Epididymal anomalies that predispose to torsion include an ETD and a long, tortuous epididymis. Although rare (0.9%) in the population with no abnormalities [3,6], they are more commonly (11-36%) seen in patients with undescended testicles [3,4]. The degree of ETD is likely to have a bearing on the severity of the torsion (Table 1).

A thickened scrotal wall and reactive hydrocele often mimic clinical signs of a testicular torsion [2], and the tenderness precludes deep palpation. As in a testicular torsion, if left untreated for more than 6-8 hours, necrosis and atrophy will ensue. Hence it is undebatable that emergent surgical exploration alone is both diagnostic and therapeutic.

The testicular congestion encountered was not surprising, as the epididymal artery arises from the testicular artery. However, it may be noted that testicular ischemia if any, is usually revertible. Following detorsion, if deemed viable, the epididymis is retained, however if

Table 1. Summary of other similar cases published in the literature together with our current case.

No.	Authors	Age (years)	Clinical Features	Sonography	Operative Findings	Surgery done
1	A Elert et al, 2002 [6]	0.5	Swelling, redness, fever	Hydrocele, Epididymal thickening, Testis hypervascular, Epididymis avascular	ETD Infarcted Epididymis Undescended testis	Epididymectomy
2	A Elert et al, 2002 [6]	18	Pain	Epididymis and testis avascular	ETD Viable after detorsion	Detorsion + Orchidopexy
3	S Ravichandran et al, 2003 [1]	9	Pain, swelling, vomiting	Not done	Tortuous epididymis (Bilateral) with band on left mesorchium Viable after detorsion	Detorsion + Orchidopexy (Bilateral)
4	Brisson P et al, 2005 [4]	11	Pain, swelling, redness	Enlarged cystic epididymis, Hypervascular epididymis and testis	Incomplete ETD Long, tortuous Epididymis Infarcted Epididymis	Epididymectomy
5	Dibilio et al, 2006 [3]	15	Pain, swelling	Hydrocele, Epididymal thickening, Epididymis avascular (head hyper vascular)	Incomplete ETD Long, tortuous Epididymis Infarcted Epididymis	Epididymectomy
6	Birkan et al, 2015 [2]	16	Pain, swelling	Enlarged Epididymis, Epididymis avascular	-	-
7	Current case	3	Left hemiscrotal pain	Not done	ETD and a long and tortuous epididymis, herni sac	Detorsion + Orchidopexy

completely infarcted, an epididymectomy is warranted while retaining the testis to maintain hormonal function [6].

It may be worthwhile to consider anchoring the epididymis to the testis in cases of complete ETD. Since our patient had an undescended testis, the adhesions following the orchidopexy were allowed to prevent any further episodes of epididymal torsion.

Table 1 is a summary of the 6 other similar cases detailed in literature. All except 1 of these [6], occurred in patients with descended testicles. Interestingly, all reported cases have occurred on the left side. Whether this has any relation to the later descent of the left testis may be studied in a larger series.

Conclusions

There are multiple learning points from this case report. Firstly, that epididymal torsion is a diagnosis to be considered when exploring an acute scrotum. Secondly, that epididymal torsion even an undescended testis can result in clinical symptoms of an acute scrotum. And finally, that epididymal anomalies encountered during surgery should be tackled appropriately as they predispose to epididymal torsion.

Compliance with ethical statements

Conflicts of Interest: None.

Financial disclosure: None.

Consent: Patient confidentiality has been maintained and written consent for the publication of patient details and clinical pictures have been obtained from the patient's father and can be furnished when required.

ORCID iD of the author (s)

Navyashree C / 0000-0003-0374-9810

Aureen DCunha / 0000-0001-7808-2091

Sandeep Rai / 0000-0002-3678-798X

References

- [1] Ravindran S, Blades RA, Watson M. Torsion of the epididymis: A rare cause of acute scrotum. *Int J Urol.* 2003;10(10):556-57.
- [2] Birkan Z, Kalayci TO, Karakeci A, et al. Untreated Isolated Torsion of the Epididymis in an Adolescent. *Urol Case Rep.* 2015;5:1-3.
- [3] Dibilio D, Serafini G, Gandolfo NG, et al. Ultrasonographic findings of isolated torsion of the epididymis. *J Ultrasound Med.* 2006;25(3):417-21.
- [4] Brisson P, Feins N, Patel H. Torsion of the epididymis. *J Pediatr Surg.* 2005;40(11):1795-97.
- [5] Dogra V, Gottlieb RH, Oka M, et al. Sonography of the scrotum. *Radiology.* 2003; 227(1):18-36.
- [6] Elert A, Hegele A, Olbert P, et al. Isolierte Nebenhodentorsion bei Hoden-Nebenhoden-Dissoziation. [Isolated epididymis torsion in testicular epididymis dissociation]. *Der Urologe.* 2002;41(4):364-65.