


**PEDIATRIC UROLOGY CASE REPORTS**

ISSN 2148-2969

<http://www.pediatricurologycasereports.com>**A foreign body in the urinary bladder leads to bladder stone and vesicorectal fistula:
A case report****Shyamendra Pratap Sharma,**  **Sarita Chowdhary, Arjdeo Upadhyay, Manoj Kumar Yadav,
Shiv Prasad Sharma***Department of Pediatric Surgery, Institute Of Medical Sciences, Banaras Hindu University, Varanasi, India***ABSTRACT**

The case in this study was presented, the features in the diagnosis and treatment of rare complications such as bladder stone and vesicorectal fistula caused by the injection needle, which is a foreign body in the bladder. A 1-year-old male child came to our outpatient department with chief complaints of straining during micturition, dribbling of urine and history of high-grade fever, chills & rigor. A kidney, ureter, and bladder (KUB) X-ray revealed an approximately 1.5 cm bladder stone with radiopaque linear foreign body. On diagnostic cystoscopy anterior, posterior urethra was normal, fecal debris, stone and a needle was seen coming out through posterior wall of bladder. Open anterior cystolithotomy was done to remove 1.5-cm stone and a foreign body described as injection needle 24 gauge surrounded with fecal debris coming out through posterior wall was also removed. Fistulous tract was present and probed with 5 Fr feeding tube. A diversion colostomy was done. Patient discharged with colostomy and in follow up after 1 month micturating cystourethrogram (MCU) and distal loopogram of colon were normal; no fistulous communication present. Colostomy was closed after 3 months. There has been many cases reported in literature about insertion of different foreign bodies in bladder but foreign body (injection needle) leading to bladder stone and vesicorectal fistula is first of its kind as far as our knowledge is concerned.

Key Words: Foreign body urinary bladder, injection needle, vesicorectal fistula, bladder stone.© 2020 [pediatricurologycasereports.com](http://www.pediatricurologycasereports.com)

✉ *Shyamendra Pratap Sharma, Mch,
Department of Pediatric Surgery, Institute Of Medical
Sciences, Banaras Hindu University, Varanasi, India
E mail: shyambrd07@gmail.com*

*Received: 2020-01-21 / Accepted: 2020-01-29**Publication Date: 2020-03-01***Introduction**

Foreign body in urinary bladder in children usually found as a result of iatrogenic injuries, self-insertion, sexual abuse, assault. A wide

variety of foreign bodies have been reported in the bladder, such as wooden sticks, thermometers, needles, pens, household batteries, parts of foley catheters, broken parts of endoscopic instruments, and knotted suprapubic catheters [1-4]. In addition, secondary bladder stones may occur following urinary stasis and infections caused by foreign bodies. Here, the foreign bodies can act as a nidus for stone development [5].

Approximately 20% of all vesicoenteric fistulas are rectovesical [6]. The common causes of acquired vesicoenteric fistula are typhoid, amoebiasis, syphilis, tuberculosis, diverticulitis, malignancy, Crohn's disease and iatrogenic [7]. It is extremely rare that the foreign body and urinary bladder stones can cause vesicorectal fistula. Here, we present a rare case of vesicorectal fistula caused by the injection needle as a foreign body in the bladder.

Case report

A 1 year old boy with a past history of recurrent urinary tract infections (UTIs) brought to the outpatient department with complaint of hematuria, dysuria, and UTI resistant to treatment with oral antibiotics. He had history of perineal insertion of a needle by a local medical practitioner 6 month back. There was no significant finding in examination. He was normocephalic, with no gross head and spine deformities. The abdomen was normal with no costovertebral angle tenderness and no suprapubic tenderness. Other systems were normal. A kidney, ureter, and bladder (KUB) X-ray showed a straight wire like radio-opaque

shadow and an irregular shaped bladder stone (1.5 cm) with its tip (Fig. 1). The renal ultrasonography was normal. Urine culture grew more than 100,000 colony-forming units/mL of *Escherichia coli*. Bladder ultrasonography showed a 1.5 cm calcified focus at the base of the bladder with a foreign body. Cystoscopy showed a stone, fecal debris in bladder and a needle emerging from posterior bladder wall (Fig. 2a, b, c).

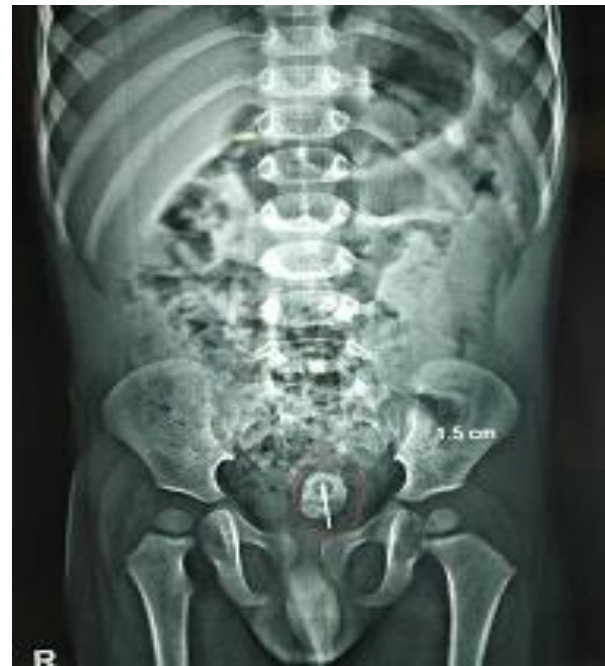

Fig. 1. X ray KUB showing bladder stone (1.5 cm) with linear foreign body.

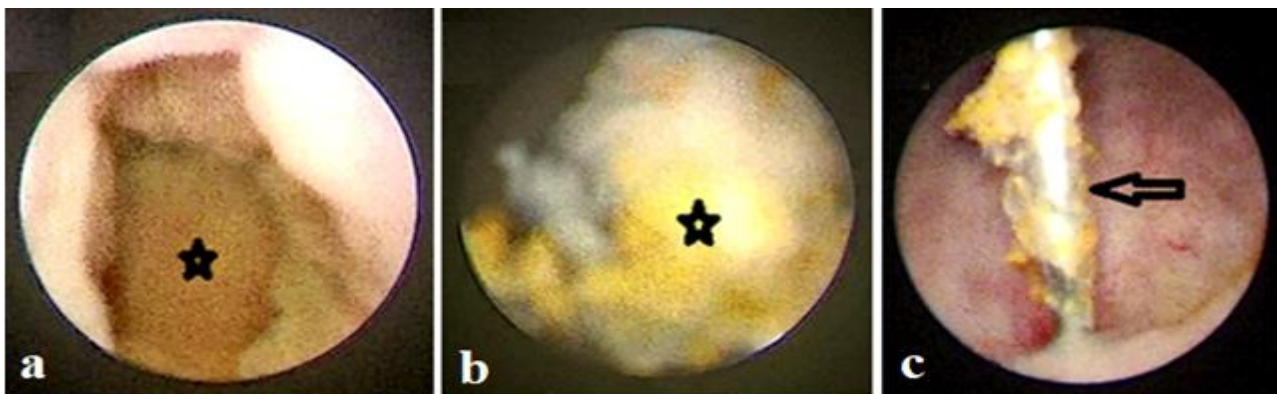


Fig. 2. The cystoscopy revealed (a) bladder stone, (b) fecal debris and (c) needle.

Open cystolithotomy was planned for the patient, and he was operated under general anesthesia. After opening the urinary bladder, a single calculus inside the lumen was seen. After extracting the stone, the urinary bladder was irrigated with normal saline. A needle emerging from posterior wall of bladder was seen and removed carefully. Fistulous tract was seen and probed with 5 fr feeding tube (Fig. 3a, b, c, d). A diversion colostomy was

performed. Patient discharged with colostomy and in follow up after 1 month micturating cystourethrogram (MCU) and distal loopogram of colon were normal no fistulous communication present (Fig. 4a and b). The colostomy was closed.

Discussion

Urinary bladder stones due to foreign bodies have been frequently reported in literature.

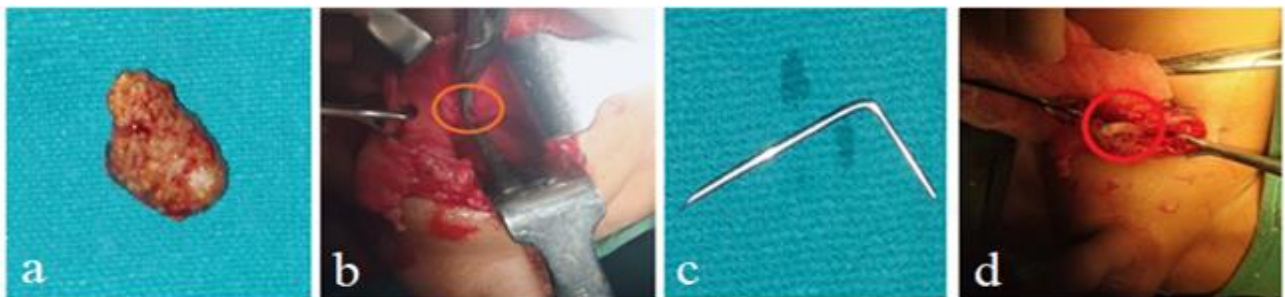


Fig. 3. The bladder stone (a), the needle in posterior wall of bladder (b), the needle after removal (c), probing of the vesicorectal fistula (d).

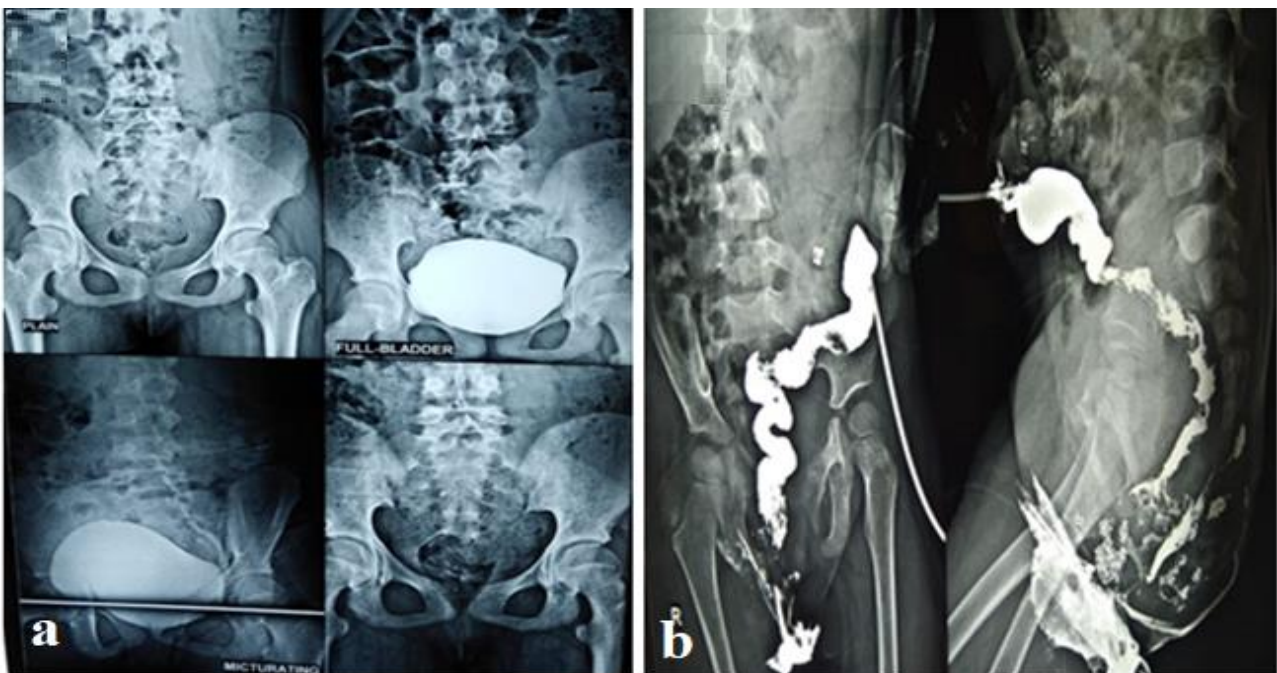


Fig. 4. (a) Normal MCU, (b) distal cologram.

done. The bladder was closed in two layers. The postoperative period was uneventful. The patient was discharged on the fifth postoperative day.

These foreign bodies may be sub-classified into iatrogenic and non-iatrogenic bodies. Iatrogenic bodies include suture material, shattered foley catheter balloons, eggshell

calcifications that form on a catheter balloon, staples, urethral stents, migrating contraceptive devices, erosions of surgical implants, and prostatic urethral stents. As in this case a needle is inserted by a local medical practitioner.

Non-iatrogenic bodies include objects pierce the anterior abdominal wall to reach the bladder and objects placed into the bladder by the patients through the urethra for recreational and various other reasons. The most common motive for self-insertion of foreign body in the lower urinary tract is different forms of sexual gratification, curiosity, autoerotic stimulation, psychiatric illness, and trauma [3, 8].

Perforation of the urinary bladder by foreign bodies from adjacent organs is extremely rare [9]. These may occur from gastrointestinal (GI) tract or female genital organ. In rare cases foreign bodies can erode the GI tract and produce enterovesical fistula [10]. The foreign bodies causing vesicointestinal fistula reported in the literature are medical mesh [12], biliary stent [13], chicken bone [14,15], gall stones [16] and ventriculoperitoneal shunt [17,18]. All such reports generated in the adult population. There is a report in which rectal impalement of a foreign body had subsequently resulted in a vesical calculus [19]. The clinical picture is more often nonspecific and related to chronic or recurrent urinary tract infection [20]. Symptoms include suprapubic pain, irritative voiding symptoms, and symptoms associated with chronic urinary tract infection. Signs include malodorous urine, debris in the urine and hematuria [20]. Specific clinical symptoms as fecaluria, pneumaturia are present in 40–70% of patients [21], and passing urine per rectum [22]. Urine analysis usually shows a full field of WBCs, bacteria and debris. Urine culture findings are most commonly interpreted as mixed flora,

predominantly *Escherichia coli* [20]. As in this case patient presented with complaint of hematuria, dysuria, and recurrent UTI resistant to treatment with oral antibiotics and urine culture grows *Escherichia coli*.

For bladder stones, cystoscopy helps in determining the exact size, number. It is a definitive diagnostic procedure [11]. In most cases, x-ray and ultrasonography of KUB is sufficient to locate and identify radio opaque bladder stone and foreign bodies, as in this case.

But the diagnosis of vesicoenteric fistula is notoriously difficult, and no single radiologic investigation has been found to be satisfactory in defining the fistulous tract [22,23]. Cystography may demonstrate contrast outside the bladder but is less likely to demonstrate a fistula [7]. Barium enema studies demonstrate only 20% to 50% of fistulas [23]; upper gastrointestinal series are not beneficial. Computed tomography (CT) scans are useful for diagnosis and are considered the primary test in some cases, although they often fail to demonstrate the fistulous tract. On the other hand, CT scans can show intravesical air, focal bladder-wall thickening, and extraluminal masses, and they can define the surrounding soft-tissue structures which can help support the diagnosis [24-27]. Cystoscopy is non-diagnostic for fistula in the majority of cases [20]. Cystoscopy findings compatible with enterovesical fistula include a papillary, tumor-like appearance due to bullous edema around the fistulous opening, or erythema and mucus-like substance over the wall of the bladder due to chronic inflammation and calcification [18,25]. Hsieh et al. [21] in a study conducted in Taiwan showed that most of these cases are diagnosed by cystography (90%), barium enema (75%) or cystoscopy (69%).

In general, most bladder stones are removed via endoscopy. However, in this case supra pubic cystostomy was planned as vesicorectal fistula was suspected. Diversion colostomy was done, fistula heals within 3 month follow-up. In case of large fistula, after repair the urinary catheter is left in place for 5–7 days or longer. The patient remains on appropriate antibiotics. A cystography can be performed to confirm healing before catheter removal [7].

To the best of our knowledge, no exact similar foreign body was reported as nidus for urinary bladder stone and vesicorectal fistula. One case has been reported of stone formation around hair pin [28] and other case formed around copper wires [29]. None of the cases complicated as acquired vesicorectal fistula. This would be the first reported case of vesicorectal fistula and bladder stone due to iatrogenic foreign body (injection needle) in a child.

Conclusion

The above-mentioned presentation is an exceptional one, where an iatrogenic body (injection needle) had manifested as a vesical calculus and vesicorectal fistula. Appropriate intervention as per the condition of the patient gives excellent results.

Compliance with ethical statements

Conflicts of Interest: None.

Financial disclosure: None.

Consent: All photos were taken with parental consent.

ORCID iD of the author (s)

Shyamendra P Sharma /0000-0003-3518-1836

Sarita Chowdhary /0000-0001-8436-7544

Manoj Kumar Yadav / 0000-0001-9146-7407

References

- [1]Eckford SD, Persad RA, Brewster SF, et al. Intravesical foreign bodies: five-year review. *Br J Urol.* 1992;69(1):41–45.
- [2]Rafique M. Intravesical foreign bodies: review and current management strategies. *Urol J.* 2008;5(4):223–31.
- [3]Tahaoglu M, Ozturk S, Ozturk H. Self-insertion of needle as urethral foreign body after sexual gratification: An unusual case report. *Pediatr Urol Case Rep.* 2014;1(5):10-14.
- [4]Thatte A, Rajendran S, Murphy L, et al. Intravesical foreign body: clinical features and diagnostic clues. *BMJ Case Rep.* 2014;2014:bcr2014204828.
- [5]Rafique M. Vesical calculus formation on permanent sutures. *J Coll Physicians Surg Pak.* 2005;15(6):373–74.
- [6]Pickhardt PJ, Bhalla S, Balfe DM. Acquired gastrointestinal fistulas: classification, etiologies, and imaging evaluation. *Radiology.* 2002;224(1):9–23.
- [7]Basler J, Kamerer A, Sresthadatta-Fenton A. Colo-vesical fistula. *Emedicine.* 15 maj 2005 [citerat 23 mar 2015]. <http://www.arabmedmag.com/issue-15-05-2005/urology/main03.htm>
- [8]Moon SJ, Kim DH, Chung JH, et al. Unusual foreign bodies in the urinary bladder and urethra due to autoerotism. *Int Neurourol J.* 2010;14(3):186-89.
- [9]Al-Heeti NH, Jasim ME, Nassar JW, et al. Foreign bodies in the urinary bladder: 10 year experience in Al-Ramadi teaching hospital. *Iraqi Postgrad Med J.* 2013;12(1):111-19.
- [10] El-Diasty TA, Shokeir AA, El-Gharib MS, et al. Bladder stone: a complication of intravesical migration of lippes loop. *Scandinavian J Urol Nephrol.* 1993;27(2):279-80.

- [11] Lin T, Chuang CK, Wong YC, et al. Gossypiboma: migration of retained surgical gauze and spontaneous transurethral protrusion. *BJU Int.* 1999;84(7):879-80.
- [12] Mukouyama H, Ogawa Y, Koyama Y. Vesicorectal fistula due to pelvic foreign body: a case report. *Hinyokika Kyo.* 2001;47(2):109–111.
- [13] Wagemakers S, Ibelings M. Enterovesicale fistel door gemigreerde galwegstent [Colovesicular fistula after migration of a biliary stent]. *Ned Tijdschr Geneesk.* 2011;155(36):A3615.
- [14] García López F, López López C, Nova Sánchez E, et al. Infrecuente agente etiológico de las fistulas vesicointestinales [An infrequent etiologic agent of vesicointestinal fistula]. *Actas Urol Esp.* 1989;13(6):454–56.
- [15] Graziotti P, Maffezzini M, Candiano G, Maugeri O. Vesicoenteric fistula created by ingested foreign body in Meckel's diverticulum. *J Urol.* 2002;168(6):2547.
- [16] Daoud F, Awwad ZM, Masad J. Colovesical fistula due to a lost gallstone following laparoscopic cholecystectomy: report of a case. *Surg Today.* 2001;31(3):255–57.
- [17] Rattan KN, Hooda R, Khursheed A, et al. Extrusion of peritoneal end of ventriculoperitoneal shunt through urethra in an infant: A rare complication. *Pediatr Urol Case Rep* 2017; 4(6):395-98.
- [18] See IV MC, Chua ME, Dy JS. A rare cause of pediatric urinary incontinence: Ventriculoperitoneal shunt with bladder perforation. *Pediatr Urol Case Rep* 2016;3(3):76-83.
- [19] Guha P, Vaze D, Rao KL. Rectal impalement presenting as bladder stones: delayed and unusual presentation. *J Pediatr Urol.* 2012;8(1):e4–e6.
- [20] Larsen A, Johansen TEB, Solheim BM, et al. Diagnosis and treatment of enterovesical fistula. *Eur Urol.* 1996;29(3):318–21.
- [21] Hsieh JH, Chen WS, Jiang JK, et al. Enterovesical fistula: 10 years experience. *Zhonghua Yi Xue Za Zhi (Taipei).* 1997;59(5):283–88.
- [22] Rodrigo E, Ruiz JC, López-Rasines G, et al. Recurrent graft pyelonephritis and pneumaturia resulting from a colovesical fistula secondary to silent diverticulitis. *Nephrol Dial Transplant.* 1998;13(4):1001-1003.
- [23] Garcea G, Majid I, Sutton CD, et al. Diagnosis and management of colovesical fistulae: six-year experience of 90 consecutive cases. *Colorectal Dis.* 2006;8(4):347-52.
- [24] Raymond PL, Gibler WB. Detection of colovesical fistula in the emergency department: report of a case. *Am J Emerg Med.* 1989;7(2):191-95.
- [25] Chitale SV, Choudhury A, Gaches CG. Transurethral fistulography—a useful technique in investigating recurrent undiagnosed pneumaturia. *World J Urol.* 2001;19(4):259-60.
- [26] Yu NC, Raman SS, Patel M, et al. Fistulas of the genitourinary tract: a radiologic review. *Radiographics.* 2004; 24(5):1331-52.
- [27] Najjar SF, Jamal MK, Savas JF, et al. The spectrum of colovesical fistula and diagnostic paradigm. *Am J Surg.* 2004;188(5):617-21.
- [28] Ghaffar A. Chronic renal failure secondary to a large vesical calculus formed on a neglected self-introduced foreign body. *NMJ.* 2010;2.

- [29] Kamal F, Clark AT, Lavallee LT, et al.
Intravesical foreign body-induced bladder
calculi resulting in obstructive renal failure.
Can Urol Assoc J. 2008;2(5):546-48.