



A penile torsion with a fistula due to previous hypospadias surgery: A case report

¹Mustafa Rasid Toksoz, ²Furkan Erol Karabekmez, ³Ramazan Kocaaslan

¹Department of Plastic and Reconstructive Surgery Beyhekim State Hospital, Konya, Turkey

²Department of Plastic and Reconstructive Surgery, Abant Izzet Baysal University, Medical School, Bolu, Turkey.

³Department of Urology, Derince Training and Research Hospital, Kocaeli, Turkey.

Abstract We presented a case of penile torsion due to previous hypospadias surgery. A patient applied to our clinic for treatment of hypospadias fistula and accompanying penile torsion. Patient's urethral fistula was repaired first and penile torsion was corrected in the second stage due to multiple fistula tracts. Proximal based flip flap technique was used for closure of the fistula and simple degloving with release of fibrous tissue and pedicle of the previous preputial island flap was used for correction of the penile torsion. Post hypospadias surgery torsion deformity as in our case may corrected with simple degloving and dissection at the level of the buck fascia.

Key words Penile torsion; hypospadias; fistula; correction; reconstructive surgery.

Copyright © 2015 [pediatricurologycasereports.com](http://www.pediatricurologycasereports.com).

Corresponding Author: Furkan Erol Karabekmez, M.D.,

Abant Izzet Baysal University, Medical School,

Department of Plastic and Reconstructive Surgery,

Bolu, Turkey.

E mail: drfurkanerol@yahoo.com

Accepted for publication: 5 December 2014

INTRODUCTION

Penile torsion can be congenital or acquired [1]. Congenital penile torsion is also can be found in boys with or without hypospadias [2]. Acquired penile torsion may develop a result of previous hypospadias surgery.

Many techniques were presented for the treatment of the penile torsion. We would like to present a case of penile torsion with a fistula due to previous hypospadias surgery for implying all treatment options and accentuate possible surgical mistakes in the etiology and explain how to avoid them.

CASE REPORT

An 8 years old boy was applied to our clinic with voiding complaints from the ventral side of the penis. The family stated previous hypospadias surgery and the urogenital examination were revealed multiple fistula openings on the ventral side of the penis located distal shaft and corona. There was a scar line suggesting previous preputial island flap on the inner surface of the prepuce. Patient prepared for the surgery and has operated for fistula repair. Fistula tracts localized on the coronal area of the ventral penis united with excision of bridges between the fistulas after urinary catheterization. Flip flap technique was modified for united fistula closure. A proximal based skin flap based on fistula proximal border was elevated and transposed to repair urethral lining repair. Subcutaneous fibrous tissues remained from previous surgery were approximated to avoid overlapping suture lines and have additional barrier for urine flow. Volar

penile skin was undermined bilaterally to gain tension free closure of volar penile skin layer and sutured with interrupted 6-0 vicryles as previous layers. Total degloving and correction of the penile torsion was postponed to second stage due to wide urethral layer defect and necessity of urethral layer and skin connection for flip flap pedicle. No postoperative fistula seen after first surgery. After three months, patient admitted to our clinic to have a second surgery for the correction of the penile torsion (Fig. 1).

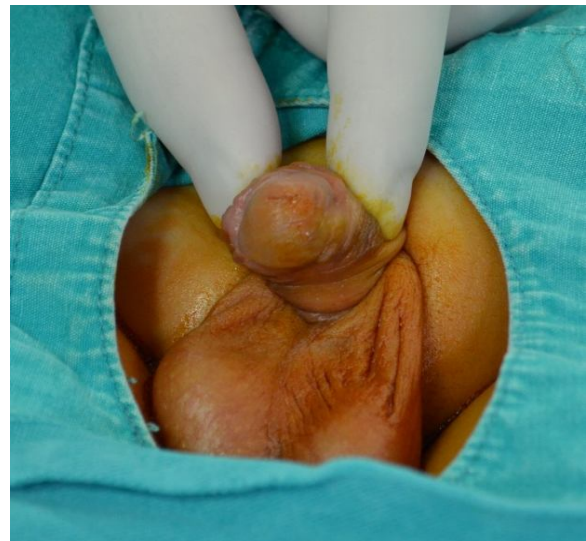

Fig. 1. Patient admitted with penile torsion complaint.

Primary concern of the patient was “urinating towards left sideway”. Patient operated under general anesthesia and artificial erection was obtained after urinary

catheterization. No obvious cordee was observed but 90 degree counterclockwise penile torsion was observed. In order to prevent possible iatrogenic fistula formation, hydro-dissection was performed in previous surgical sites and dissection was performed at the level of the Buck fascia. After total degloving, the pedicle of the previous preputial island flap and residual fibrous tissues were released to correct the penile torsion deformity and full correction established (Fig. 2).

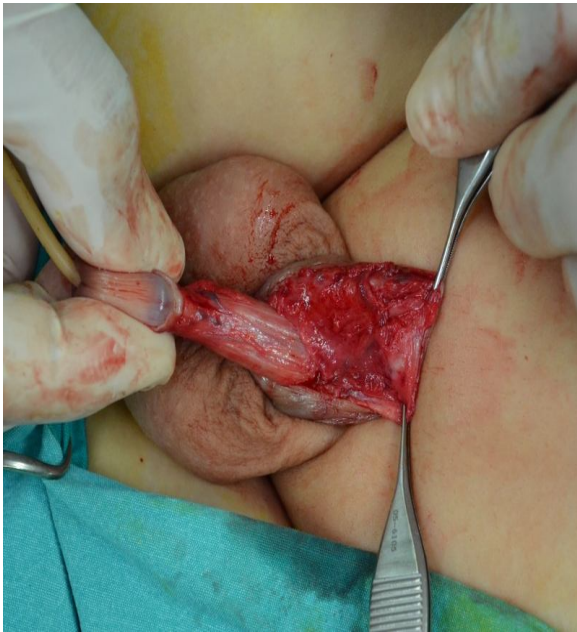

Figure 2. After degloving, fibrous tissues released to obtain proper alignment of the corpus.

No further attempt such as suturation to fascia required for correction (Fig. 3).

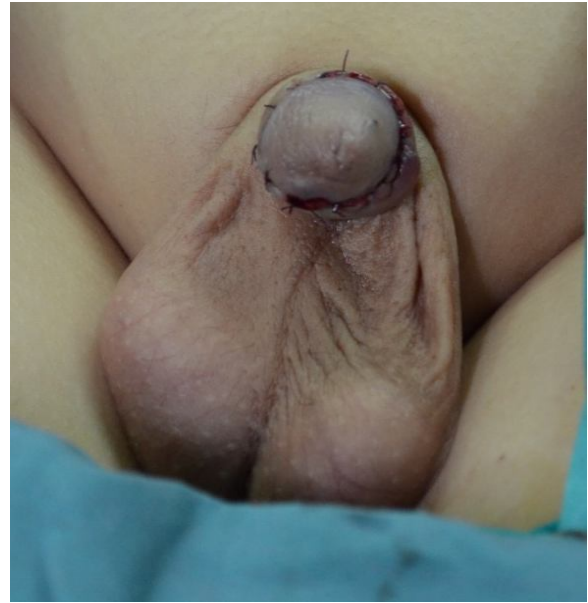


Fig. 3. Postoperative view after the second surgery.

DISCUSSION

The etiology of the congenital penile torsion is unknown and commonly present as counterclockwise rotation with associated anomalies [1].

Shaer et al. [3] revealed that 12% of their patients who admitted to infertility/sexual dysfunction clinic has penile rotation. However, none of the patients complained of sexual dysfunction and 2% of them demanded an aesthetic procedure to correct appearance of the penis.

Correction of penile torsion with associated anomalies should be done in preferably within the 1st years of life [2]. Penile degloving and realignment is suggested treatment for mild degree penile torsion

cases by Bar-Yosef et al [4]. More severe form of penile torsion cases (>90 degrees) requires dorsal dartos flap rotation technique suggested by Fisher and Park first [5]. Bauer et al. [6] presented their 25 patients who underwent repair of significant penile torsion using a dorsal dartos flap. 15 of their patients have more than 90 degree torsion. Redman and Bissadaa [7] have suggested freeing the corpora spongiosa from the corpora cavernosa for patient with 180 degree penile torsion. However current case has 90 degree torsion, and was treated with a simple penile degloving, releasing of residual pedicle tissue from the previous surgery and realignment. On the other hand, Bhat et al. [8] suggested that some of the significant penile torsion cases and curvature cases are overlapping and the treatment is also should be done simultaneously by mobilization of the urethra with spongiosum from the corpora. Zhou et al. [9] suggested lateral suturing of tunica albuginea to the pubic periosteum to repair penile torsion, Redman advocated that "Torsion most frequently is corrected by reflection of the skin and dartos tunic only. In some cases resection of Buck's fascia will provide correction" in his gross

anatomic study [10]. No fascial resection required in the current case.

Montag and Palmer [2] provided that Varying degrees of penile curvature are observed in 4-10% of males in the absence of hypospadias with various degree of cordee. Our case has hypospadias but no cordee.

Penile torsion due to previous hypospadias surgery is not a common entity. Correction of the deformity may established with a simple degloving on buck fascia level and releasing previous preputial island flap pedicle in specific cases have previous hypospadias surgery. No further intervention requires if the etiology is determined correctly by a proper history.

Acknowledgements

The author(s) declare that they have no competing interests and financial support.

REFERENCES

1. Hsieh JT, Wong WY, Chen J, Chang HJ, Liu SP. Congenital isolated penile torsion in adults: untwist with plication. *Urology*. 2002; 59(3):438-40.
2. Montag S, Palmer LS. Abnormalities of penile curvature: chordee and penile torsion. *Scientific World Journal*. 2011 28;11:1470-8.
3. Shaer O. Torsion of the penis in adults: prevalence and surgical correction. *J Sex Med*. 2008; 5(3):735-9.
4. Bar-Yosef Y, Binyamini J, Matzkin H, Ben-Chaim J. Degloving and realignment--simple repair of isolated penile torsion. *Urology*. 2007; 69(2):369-71.
5. Fisher p, C. and M. Park j. Penile torsion repair using dorsal dartos flap rotation. *J Urol*. 2004; 171(5):1903-4.
6. Bauer R, Kogan BA. Modern technique for penile torsion repair. *J Urol*. 2009; 182(1):286-90; discussion 290-1.
7. Redman JF, Bissada NK. One-stage correction of chordee and 180-degree penile torsion. *Urology*. 1976; 7(6):632-3.
8. Bhat A, Sabharwal K, Bhat M, Singla M, Kumar V, Upadhyay R. Correction of penile torsion and chordee by mobilization of urethra with spongiosum in chordee without hypospadias. *J Pediatr Urol*. 2014 July 22. pii: S1477-5131(14)00188-0.
9. Zhou L, Mei H, Hwang AH, Xie HW, Hardy BE. Penile torsion repair by suturing tunica albuginea to the pubic periosteum. *J Pediatr Surg*. 2006 ;41(1):e7-9.
10. Redman JF. Torsion of the penis: a gross anatomic study. *J Urol*. 1983; 130(2):316-8.

Access this article online

<http://pediatricurologycasereports.com>

Quick Response Code

