



PEDIATRIC UROLOGY CASE REPORTS

ISSN 2148-2969

<http://www.pediatricurologycasereports.com>**A rare case with multiple urinary anomalies associated with urethral duplication: Distal hypospadias, posterior urethral valve, left vesicoureteral reflux, and right renal agenesis****Erol Basuguy, Salih Bayram***Department of Pediatric Surgery, Dicle University, Medical School, Diyarbakir, Turkey***ABSTRACT**

Urethral duplication is a rare congenital malformation with multiple clinical manifestations. Here, we present a case involving a boy with hypospadiac urethral duplication and multiple congenital anomalies. The patient had additional anomalies including a posterior urethral valve, left vesicoureteral reflux and right renal agenesis. This case is discussed in terms of the type of urethral duplication and the importance of additional anomalies.

Key Words: Urethral duplication; hypospadias; posterior urethral valve; vesicoureteral reflux; renal agenesis.

Copyright © 2019 pediatricurologycasereports.com

Corresponding Author: Dr. Erol Basuguy.

*Department of Pediatric Surgery, Dicle University,
Medical School, Diyarbakir, Turkey.*

E mail: erbas.80@hotmail.com

ORCID ID: <https://orcid.org/0000-0002-9217-423X>

Received 2018-11-22, Accepted 2018-12-07

Publication Date 2019-01-01

Introduction

Urethral duplications are one of the rarest congenital anomalies of the urinary system and have been reported in approximately 200 cases in the literature [1]. There are several anatomic variants of urethral duplications associated with other congenital anomalies and the classification system of Effman, Lebowitz and Colodny has been widely adopted to account for these variants (Fig. 1) [2]. An anomaly mostly formed in the sagittal plane, a duplicated urethra is located in the dorsal or ventral position according to the orthotopic

urethra [3]. In addition, the ventral urethra is generally more functional and has a sphincteric mechanism [4]. To the best of our knowledge, no case involving distal hypospadias, posterior urethral valve, and left vesicoureteral reflux and right renal agenesis has been described in the literature. We therefore report the clinical and radiological features of this case in light of the literature.

Case report

A 9 month-old boy was referred to our institution with complaints of two urinary orifices noted after circumcision. Physical examination of the patient revealed that there were two urethral meata, one at the top of the glans and a second in the coronal region. These two entry orifices were catheterized. The urethra at the top of the glans was terminated blindly at a distance of 5-6 cm. The urethra at

the ventral coronal level reached the bladder and urine was observed.

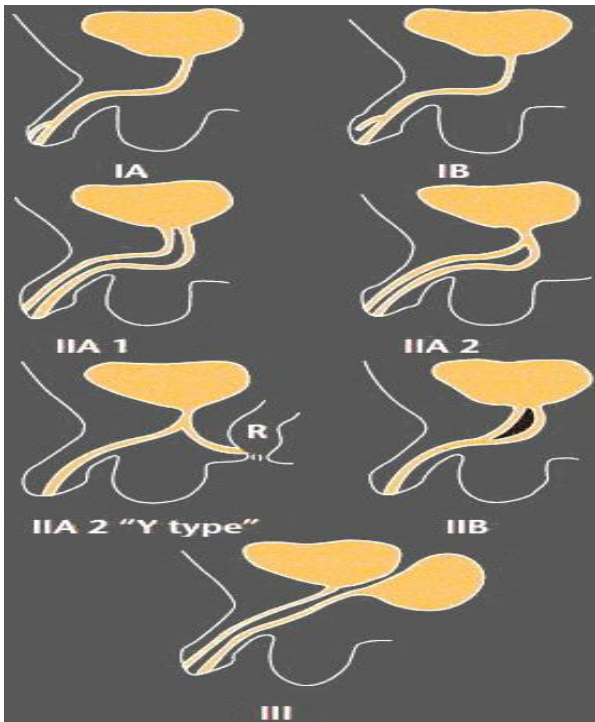


Fig. 1. Effman's Classification. Type I: Blind-ending accessory urethra (incomplete urethral duplication). IA: Distal duplicated urethras opening on the dorsal or ventral surface of the penis but not communicating with the urethra or bladder (the most common type). IB: Proximal accessory urethra opening from the urethral channel but ending blindly in the periurethral tissues (rare). Type II: Completely patent accessory urethra. It is divided into 2 parts: A (2 meatus) and B (1 meatus). Type II A1: Two non-communicating urethras arising independently from the bladder. Type II A2: Second channel arising from the first and coursing independently into a second meatus (Y-type). Type IIB: Two urethras arising from the bladder or posterior urethra and uniting into a common channel distally. Type III: Accessory urethras arising from duplicated or septated bladders.

Furthermore, the urethral tract at the ventral coronal level was catheterized and the bladder was reached (Fig. 2). Physical examination revealed no other associated congenital

abnormalities and testes were bilaterally present in the scrotum. The patient's blood counts, blood chemistry, urine analysis, and urine culture were normal.

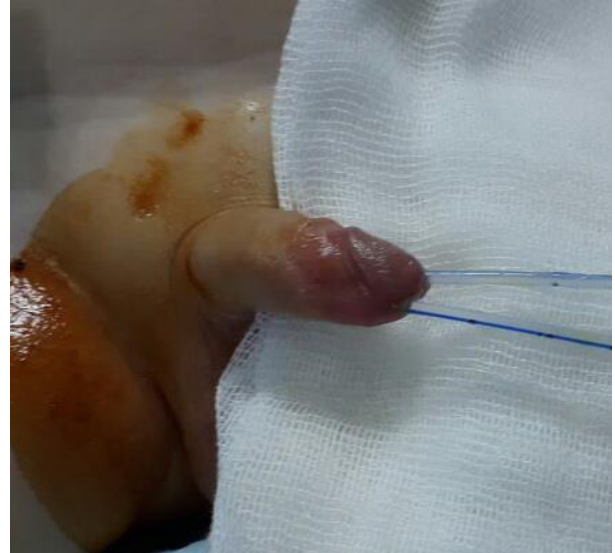

Fig. 2. Hypospadiac urethral duplication.

Examination of the urinary tract by ultrasonography revealed right renal agenesis and left Grade 2 hydronephrosis. The patient was then investigated by voiding cystourethrography and Grade 2 vesicoureteral reflux was determined (Fig. 3).

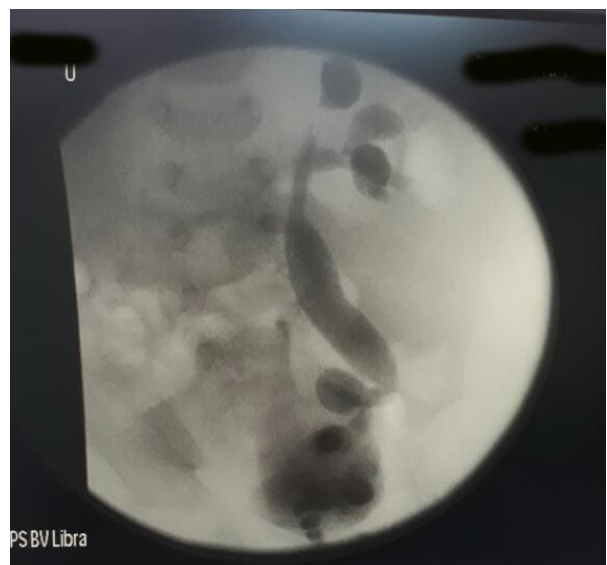

Fig. 3. Vesicoureteral reflux in voiding cystourethrography.

Cystourethroscopy through the ventral urethra revealed a Type III urethral valve (diaphragm) and this was then fulgurated. Thereafter, the patient was followed for the treatment of urethral duplication and other additional anomalies.

Discussion

Urethral duplications are the rarest congenital malformations of the urinary tract with different anatomic variations. There are several theories about the etiology of such duplications, such as failure of mesodermal fusion, abnormal Mullerian duct termination, vascular accident, an ischemic process in embryogenesis, and impaired growth of the dorso inferior wall of the urogenital sinus. However, none of these can explain all types of presentations [5]. Urethral duplication is divided into three types according to Effmann's classification [2]. The most common subtype is Type IA; it is a common distal type in which an accessory urethra opens on the dorsal or ventral penile surface but does not communicate with the urethra or bladder. We consider this case to be a variant of Effmann Type 1A. According to a new classification proposed by AbouZeid et al., the dorsal accessory of the urethra was divided into subgroups A and B [6]. In subgroup A, the ventral meatus is orthotopic and in the B subgroup the ventral meatus was associated with hypospadiac and major renal anomalies, as in our case.

A careful urogenital physical examination is critical to the diagnosis of urethral duplications. In addition, voiding cystourethrography, retrograde urethrogram and urethrocystoscopy are radiological methods that should be used when making a detailed examination. Ultrasound is a valuable

diagnostic tool for the diagnosis of other associated renal anomalies [7].

Hypospadiac urethral duplication can be explained by a discrepancy between the urogenital sinus-derived urethra and the urethra obtained from the urethral groove [3]. The definition of a functional urethra is critical to the achievement of surgical correction. Generally, a hypospadiac ectopic channel is functional; however, a normally placed urethra is hypoplastic. Surgical urethral repair is the preferred treatment [8].

Urethral duplication is often associated with other congenital anomalies such as bifid scrotum, cryptorchidism, hypospadias, megalourethra, micropenis, vesicoureteral reflux, renal agenesis and renal ectopy, dysplastic-multicystic kidney, vertebral anomalies (sacral agenesis, thoracic hemivertebra), anorectal anomalies, trachea-esophageal fistula and duplications (penile, vagina, uterus, bladder and colon) [3, 9-12].

Treatment of this anomaly depends on the duplication type and its clinical manifestations. Before any surgical decision is made, the more functional urethra must be identified. Cases with incomplete duplication, such as Type I A or I B, may be asymptomatic with no need of surgical correction [13,14]. As a result, urethral duplications have many clinical forms and are often associated with other anomalies. Therefore, patients should be investigated for additional congenital anomalies and their treatments individualized according to the type of surgical repair anomaly.

Compliance with ethical statements

Conflicts of Interest: None.

Financial disclosure: None.

Consent: All photos were taken with parental consent.

References

- [1] Macedo A Jr, da Cruz ML, Parizi JLG, Martins GMC, Liguori R, Ottoni SL, et al. An unusual presentation of urethral duplication presenting with chronic bladder retention, left scrotal transposition and left renal agenesis. *Int Braz J Urol.* 2018;44(2):409-10.
- [2] Effmann EL, Lebowitz RL, Colodny AH. Duplication of the urethra. *Radiology.* 1976;119(1):179-85.
- [3] Salle JL, Sibai H, Rosenstein D, Brzezinski AE, Corcos J. Urethral duplication in the male: review of 16 cases. *J Urol.* 2000;163(6):1936-40.
- [4] Woodhouse CR, Williams DI. Duplications of the lower urinary tract in children. *Br J Urol.* 1979;51(6):481-87.
- [5] Mane SB, Obaidah A, Dhende NP, Arlikar J, Acharya H, Thakur A, et al. Urethral duplication in children: our experience of eight cases. *J Pediatr Urol.* 2009;5(5):363-67.
- [6] AbouZeid AA, Safoury HS, Mohammad SA, El-Naggar O, Zaki AM, Hassan TA, et al. The double urethra: revisiting the surgical classification. *Ther Adv Urol.* 2015;7(2):76-84.
- [7] Ashok AJ, Basavaraju M, Zachariah N, Pavithra SK. A surprise during hypospadias repair: A rare case of urethral duplication with review of literature. *J Curr Res Sci Med.* 2017;3(2):122-24.
- [8] Podesta ML, Medel R, Castera R, Ruarte AC. Urethral duplication in children: surgical treatment and results. *J Urol.* 1998;160(5):1830-33.
- [9] Prasad N, Vivekanandhan KG, Ilangovan G, Prabakaran S. Duplication of the urethra. *Pediatr Surg Int.* 1999;15(5-6):419-21.
- [10] deVries PA, Friedland GW. Congenital "H-type" ano-urethral fistula. *Radiology.* 1974;113(2):397-407.
- [11] Kennedy HA, Steidle CP, Mitchell ME, Rink RC. Collateral urethral duplication in the frontal plane: a spectrum of cases. *J Urol.* 1988;139(2):332-34.
- [12] Savanelli A, Schiano A, Esposito C, Russo S, Dolezalova H. Congenital megalourethra associated with urethral duplication and imperforate anus. *Pediatr Surg Int.* 1998;13(8):607-9.
- [13] Lopes RI, Giron AM, Mello MF, Neto CMB, Santos JD, Moscardi PRM, et al. Urethral duplication type influences on the complications rate and number of surgical procedures. *Int Braz J Urol.* 2017;43(6):1144-51.
- [14] Parelkar SV, Sanghvi B, Gupta RK, Pawar AA. Y-type urethral duplication with posterior perineal fistula: A new variant. *Pediatr Urol Case Rep.* 2017; 4(3):315-19.

Access this article online

<http://pediatricurologycasereports.com>

Quick Response Code

