

## A rare cause of pediatric urinary incontinence: Ventriculoperitoneal shunt with bladder perforation

Manuel C See IV<sup>1</sup>, Michael E Chua<sup>1</sup>, Jun S Dy<sup>2</sup>

<sup>1</sup> St. Luke's Medical Center, Quezon City, Philippines

<sup>2</sup> St. Luke's Medical Center and Quirino Medical Center, Quezon City, Philippines

### Abstract

We present a case of 2-year-old boy with long term dysuria and intermittent incontinence, and new onset of fever and headache. Significant past medical history includes congenital hydrocephalus with a ventriculoperitoneal shunt placement two years prior to consult. On physical examination, a tubular structure was noted underneath the prepuce suspected to be the distal tip of ventriculoperitoneal shunt, which was confirmed by kidney, ureter and bladder (KUB) X-ray and CT scan. Patient was treated with a novel approach of extraperitoneal removal of ventriculoperitoneal shunt distal tip with cystorrhaphy via a low transverse pfannenstiel incision, separate left ventriculostomy tube insertion and complete removal of ventriculoperitoneal shunt from the right ventricle. This report accounts a rare pediatric case with ventriculoperitoneal shunt perforation into a normal bladder successfully treated with mini-open surgery.

### Keywords

Ventriculoperitoneal shunt; bladder perforation; child; silent bladder perforation.

Copyright © 2016 [pediatricurologycasereports.com](http://www.pediatricurologycasereports.com).

**Corresponding Author:** Jun S Dy, M.D.

CHBC ST 802-279 E. Rodriguez Sr. Blvd. Quezon City, Philippines

E-mail: [junsdy68@yahoo.com](mailto:junsdy68@yahoo.com)

Accepted for publication: 25 February 2016

### Introduction

The diversion of cerebrospinal fluid (CSF) for hydrocephalus into the peritoneal cavity

for CSF absorption in ventriculo-peritoneal shunting (VPS) was introduced in 1905 by Kausch [1]. Since then VPS is amongst the most frequently performed operations in the management of hydrocephalus [1]. VPS used in the treatment for hydrocephalus is associated with several complications with reported incidence of 85.4% of cases will

need revision in few days to 17 years post-placement [2]. Abdominal complications include: peritoneal pseudocyst, intestinal volvulus, pseudotumor of the mesentery, inguinal hernia, and migration of the catheter through the vagina, scrotum, umbilicus, and intestinal tract [3,4]. Bladder perforation in a normal bladder after VPS is a rare complication [5].

Voiding complaints in the pediatric patient is a broad topic with variable presentations and etiologies. Incontinence defined as continuous leakage of urine from the bladder was the 1<sup>st</sup> sign of the perforation of the VPS into the bladder and eventually towards the urethra months before the sign of meningitis occurred [6]. This is a rare late complication of a VPS which bladder perforation can potentially create diagnostic and therapeutic dilemma, and there are no clear guidelines on the management of this problem. We present a rare case of pediatric ventriculoperitoneal-vesical perforation complication presenting with urinary incontinence and to describe the novel technique used in its management with discussion of literature review.

### **Case report**

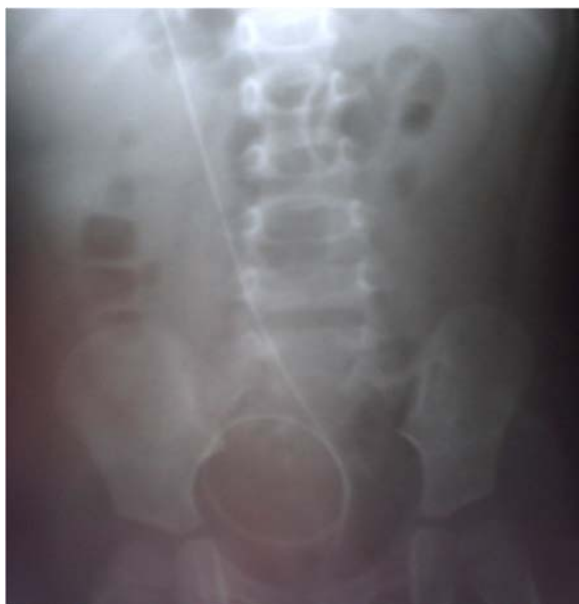A 2 year old boy presented with long term dysuria (crying episodes when urinating) and continuous urine dripping

(incontinence) noted from an uncircumcised penis. An incidence of a whitish tubular structure protruding from the patient's penile meatus was previously noted. The tubular structure was then pushed back and consult was done.

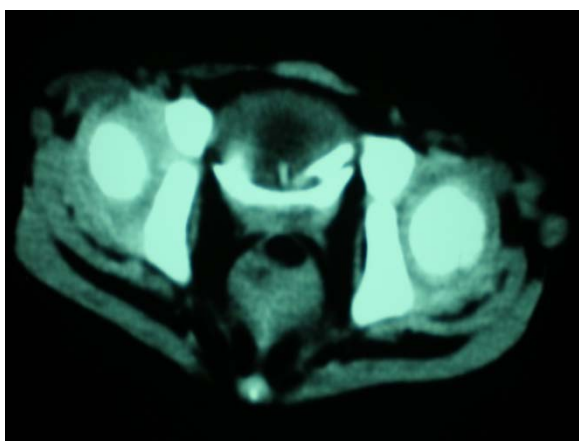
At presentation, patient already developed 3-week history of low grade fever, associated with headache and vomiting. Significant past medical and surgical history include a diagnosis of congenital hydrocephalus at 3 months of age and VPS inserted at 5 months of age. Physical examination on admission showed a bedridden, febrile, pale, asthenic, child with poor appetite. Neurological examination revealed poor sensorium and drowsy patient, arousable to pain and occasionally localize pain stimulus. Abdominal findings were soft, non-tender with no signs of peritonitis. The previous right upper quadrant surgical scar from the previous VPS insertion was noted.

Further examination and retraction of the prepucial skin noted a dirty white plastic tubular structure protruding from the urethra. Impression of possible VPS migration into the genitourinary system had been entertained. Abdominal x-ray requested noting a tubular structure consistent with the tip of the VPS to be coiled within the rims and confines of the bony pelvis. CT scan of the whole abdomen was also done

confirming the presence of the tip of the VPS to be coiled inside the urinary bladder [Fig. 1, 2]. Urinalysis showed pyuria and bacteriuria. The urine culture taken on admission showed the presence of *Klebsiella oxytica* with a growth of 120,000 colony-forming unit (CFU).

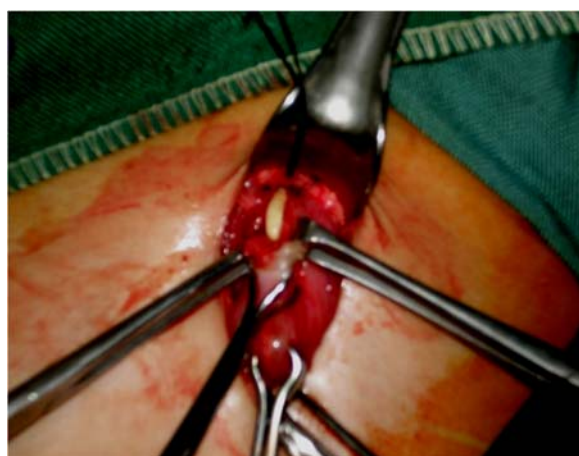

**Fig. 1.** X rays of the urinary tract showing VP shunt distal segment in the pelvic location.

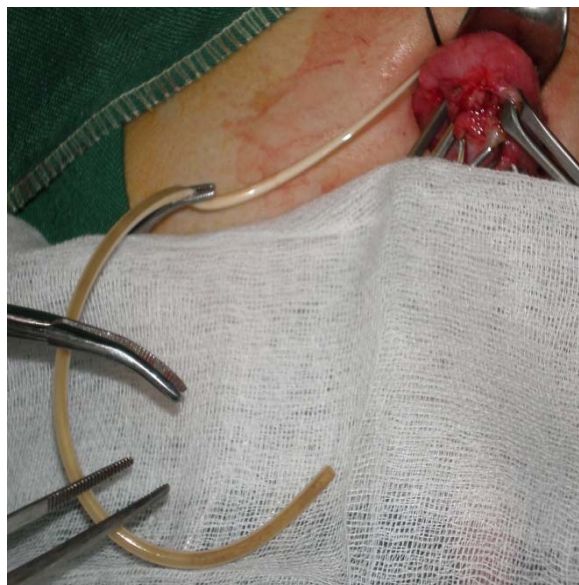


**Fig. 2.** Axial CT scan without contrast showing distal VP shunt segment with tip perforated into the bladder.

Patient was started with appropriate intravenous antibiotics and underwent emergent procedure of extra peritoneal exploration with removal of VPS, and ventriculostomy tube insertion. Conduct of surgery began with simultaneously with the neurosurgery team. A 3 cm low transverse pfannenstiel incision was done and carried down to the extra vesical space. Intra-operative abdominal findings showed the VPS was seen within the peritoneum and has created a fibrous tract that transversed down toward the bladder. It was noted to penetrate the dome of the urinary bladder (Figure 3). The length of the VPS that entered the bladder was 8cm. The distal part of the VPS was encrusted with inspissated pus [Fig. 4] and was removed successfully with ease from the urinary bladder. The bladder was closed as two layers using a 4-0 polyglycolic suture in a continuous interlocking manner.



**Fig. 3.** Intraoperative finding with the distal end of VP-shunt inserted into the bladder dome.



**Fig. 4.** VP shunt distal end extracted from bladder with mildly encrusted surface.

A Burr hole craniotomy with ventriculostomy tube inserted into the left frontal horn and exteriorized for drainage. A separate cranial incision was done at the right parietal area of the skull and the infected VPS tube was removed. The infected VPS showed intra-luminal obstruction with caked and encrusted pus impeding flow of cerebrospinal fluid and proper drainage leading to recurrence of the hydrocephalus. Specimen from the drained abscess and the VPS was sent to microbiology for culture and sensitivity. The VPS was then completely removed after the distal end was transected and removed from the urinary bladder. Patient showed immediate post-operative improvement in sensorium with spontaneous eye opening and purposeful movement of all extremities.

## Discussion

Perforation of abdominal viscera by VPS is a rare complication that often results in infection such as peritonitis and central nervous system infection [5]. Bowel perforation of VPS is a recognized complication. The relatively thin walled gastrointestinal tract would allow the spontaneous perforation and erosion of a VPS into the bowel [7]. Compared to the bowel, the bladder has a thicker wall and is a relatively more muscular organ. Generally, the bowel would be easier to perforate than the bladder. Bladder perforation by a VPS in a normal bladder is less reported in the literature as compared to perforation of the colon therefore its incidence is not known. Up to date, only 18 pediatric cases reported to have VPS bladder perforation [6]. Most often, erosions into the bladder occur after augmentation [5] or secondary to internal spring catheters that were popularly used to maintain the shape of the VPS. According to recent study by Mutlu et al 2015, VP perforation into the bladder commonly presented with urethral extrusion, with dysuria and incontinence which was commonly a neglected symptom by the caregivers for non-toilet trained kids such as our case [6]. The same review by Mutlu et al, also mentioned that the most feared associated complication were bacterial

meningitis, which in our case progressed into sensorial changes and seizures [6].

Possible mechanism to the perforation of the VPS to a normal urinary bladder includes:

1. *Iatrogenic placement or inadvertent placement/positioning of the distal end of the VPS to the bladder during VPSt insertion [6].*

2. *Continuous mechanical irritation at a fixed point on the bladder surface inducing the perforation [8];*

3. *Stiff and sharp-tipped catheters may perforate the bladder [9]; and*

4. *The thin wall in the pediatric age group may predispose these patients to viscus perforation [10]. The use of trochar in the access of the peritoneum was associated with a higher risk of viscus perforation as compared to open procedures [11, 12].*

However in our patient the VPS was inserted via an open procedure and iatrogenic injury to a viscus may it be a colon or the urinary bladder would present as peritonitis immediately. Intraoperative findings during surgery showed fibrous encasement of the distal VPS before it perforated the bladder. Initially, when the VPS tip perforated or eroded into the bladder, there was local irritation and infection inducing a local reaction and fibrous formation. This localized reaction encased the VPS preventing further spread of urine and

infection into the peritoneum. This would explain the absence of the peritoneal signs of irritation or peritonitis. Specifically, due to the long period of time the VPS is being surrounded by fibrous encasement at the perforation site thereby acting like a seal preventing subsequent peritoneal infection/peritonitis [13].

The options for the management of patients who present with protrusion of catheter from a hollow viscus include: (a) formal exploratory laparotomy and repair of perforation, (b) shunt removal and external ventricular drainage, antibiotics, followed by VPS or ventriculoatrial shunt, (c) flexible pediatric endoscopy can be used for localization of perforation site and removal of shunt [14-17]. However majority of available data is for rectal and colonic perforation of a VPS and methods for the treatment of urinary bladder perforation is very limited [18-20].

In this case, we opted to do a mini open surgery as to avoid unnecessary opening thru the peritoneum. There was no clinical evidence of peritonitis. Complete removal of the VPS and formal closure of the urinary bladder perforation was done simply with this technique. This was also done simultaneously with the neurosurgery team doing a cranial burr hole, ventriculostomy tube insertion, removal of the infected VPS

and drainage of the ventricular abscess. A definitive minimally invasive procedure in repairing the perforation was decided upon over conservative pulling out of VPS without opening up the perforation site. This is to prevent the unnecessary added morbidity in case there would be urine leakage into the abdomen from the perforation site of the VPS which might lead to further morbidity and catastrophic events.

### Conclusion

In summary, we present a 2 year old male with a previous VPS insertion that had a late symptom of urinary incontinence as a result of a perforation of the distal tip into the bladder and protruded outside the urethra. A high index of suspicion on patients with previous history of insertion of VPS presenting with distal shunt failure is needed

### References

1. Lifshutz JJ, Johnson WD. History of hydrocephalus and its treatments. *Neurosurg Focus*. 2001;11(2):E1.
2. Stone JJ, Walker CT, Jacobson M, Phillips V, Silberstein HJ. Revision rate of pediatric ventriculoperitoneal shunts after 15 years. *J Neurosurg Pediatr*. 2013;11(1):15-9.
3. Patel CD, Matloub H. Vaginal perforation as a complication of ventriculoperitoneal shunt. *J Neurosurg*. 1978;38(6):761-2.
4. Martínez Hernández-Magro P, Barrera Román C, Villanueva Sáenz E, Zavala MJ. Colonic perforation as a complication of ventriculoperitoneal shunt: a case report. *Tech Coloproctol*. 2006;10(4):353-5.
5. Mevorach RA, Hulbert WC, Merguerian PA, Rabinowitz R. Perforation and

to diagnose a possible perforation to a viscus. Subtle urologic signs of voiding complaints and disregarded presence of a tubular structure at the penile meatus months before the abscess formation by the caregiver could have prevented the neurologic sequela of this case.

### Acknowledgements

The author(s) declare that they have no competing interests and financial support.

- intravesical erosion of a ventriculoperitoneal shunt in a child with an augmentation cystoplasty. *J Urol.* 1992;147(2):433-4.
6. Mutlu M, Kader S, Aslan Y, Yazar U, Imamoglu M. An acute complication of Ventriculoperitoneal shunt with bladder perforation and extrusion through the urethra in a newborn: Case report and review of literature. *Pediatr Neurosurg* 2015;50:264–269.
  7. Mihajlović M, Tasić G, Raicević M, Mrdak M, Petrović B, Radlović V. Asymptomatic perforation of large bowel and urinary bladder as a complication of ventriculoperitoneal shunt: report of two cases. *Srp Arh Celok Lek.* 2012;140(3-4):211-5.
  8. Jamjoom AB, Rawlinson JN, Kirkpatrick JN. Passage of tube per rectum: an unusual complication of a ventriculoperitoneal shunt. *Br J Clin Pract.* 1990;44(11):525-6.
  9. Nourisamie K, Vyas P, Swanson KF. Two unusual complications of ventriculoperitoneal shunts in the same infant. *Pediatr Radiol.* 2001;31(11):814-6.
  10. Snow RB, Laryne MH, Fraser RA. Colonic perforation by ventriculoperitoneal shunt. *Surg Neurol.* 1986;25(2):173-7.
  11. Portnoy HD, Croissant PD. Two unusual complications of a ventriculoperitoneal shunt. *J Neurosurg.* 1973;39(6):775-6.
  12. Grosfeld JL, Cooney DR, Smith J, Campbell RL. Intra-abdominal complications following ventriculoperitoneal shunt procedures. *Pediatrics.* 1974;54(6):791-6.
  13. Eichel L, Allende R, Mevorach RA, Hulbert WC, Rabinowitz R. Bladder calculus formation and urinary retention secondary to perforation of a normal bladder by a ventriculoperitoneal shunt. *Urology.* 2002;60(2):344.
  14. Ramana Murthy KV, Jayaram Reddy S, Prasad DV. Perforation of the distal end of the ventriculoperitoneal shunt into the bladder with calculus formation. *Pediatr Neurosurg.* 2009;45(1):53-5.
  15. Ghritlaharey RK, Budhwani KS, Shrivastava DK, et al. Trans-anal protrusion of ventriculo-peritoneal shunt catheter with silent bowel perforation: report of ten cases in children. *Pediatr Surg Int.* 2007;23(6):575-80.
  16. Chen HS. Rectal penetration by a disconnected ventriculoperitoneal shunt tube: an unusual complication. *Chang Gung Med J* 2000;23(3):180–4.
  17. Sharma A, Pandey AK, Radhakrishnan M, et al. Endoscopic management of anal

- protrusion of ventriculo-peritoneal shunt. Indian J Gastroenterol. 2003;22(1):29-30.
18. Kataria R, Sinha VD, Chopra S, Gupta A, Vyas N. Urinary bladder perforation, intra-corporeal knotting, and per-urethral extrusion of ventriculoperitoneal shunt in a single patient: case report and review of literature. Childs Nerv Syst. 2013;29(4):693-7.
19. Butler L, Keys C, Lam JP. Bladder calculus formation on the tip of a migrated disused ventriculoperitoneal shunt. J Pediatr Surg. 2013;48(5):E1-3.
20. Chen TH, Lin MS, Kung WM, Hung KS, Chiang YH, Chen CH. Combined ventriculoperitoneal shunt blockage, viscus perforation and migration into urethra, presenting with repeated urinary tract infection. Ann R Coll Surg Engl. 2011;93(7):e151-3.

**Access this article online**

<http://pediatricurologycasereports.com>

**Quick Response Code**

