

Accessory urethra in a male infant: A case report

Parkash Mandhan, Falah Ismail, Mansour Ali

Department of Pediatric Surgery, Hamad General Hospital, Hamad Medical Corporation, Doha, Qatar

Abstract

Accessory urethra is a rare congenital anomaly and has varied presentations. Multiple surgical techniques have been described for its correction. We report a case of accessory urethra in a male infant, which was recognized incidentally. Diagnosis requires a high index of suspicion and optimal knowledge of the anomaly is mandatory for the surgical team to achieve a good outcome.

Keywords

Accessory urethra; infants; male.

Copyright © 2016 [pediatricurologycasereports.com](http://www.pediatricurologycasereports.com).

Corresponding Author: *Parkash Mandhan, M.D,*
Ph.D. Pediatric Surgeon & Urologist
Department of Pediatric Surgery, Hamad General
Hospital Hamad Medical Corporation Doha, Qatar
E-mail: kidscisurg@icloud.com
Accepted for publication: 11 May 2016

Introduction

Accessory urethra is an uncommon congenital abnormality observed in pediatric urological practice with multiple anatomical variants described [1]. The etiology is poorly understood and various theories have been suggested. Despite numerous theories proposed to explain this rare congenital anomaly, no single theory could explain all

the types of anomalies. It has been reported more common in males than female children [2]. We report a case of accessory urethra in a 10-months-old boy, which was identified incidentally. We also discuss the presentation, embryogenesis and management of accessory urethra in infants.

Case Reports

A 10-months-old boy was attended in pediatric accident & emergency section for perianal abscess. He was born full-term and since birth has been well. Routine examination of external genitalia revealed circumcised phallus and a normal looking

external urethral meatus at the tip of glans penis. On the dorsal aspect, the glans penis was bifid and close examination revealed an opening leading towards the pubis under the penile skin [Fig. 1A].

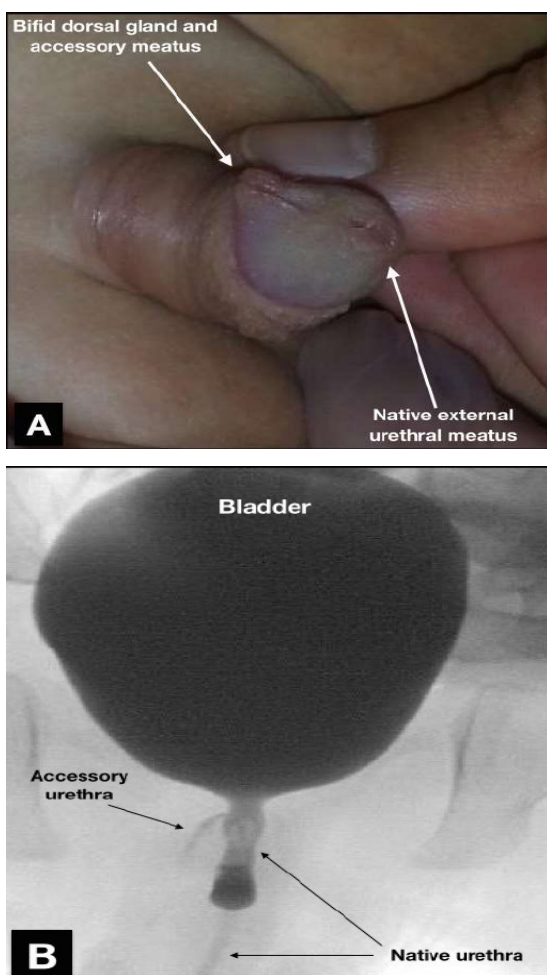


Fig. 1. Image showing circumcised phallus, bifid dorsal glans and an accessory opening dorsal to the normal urethral meatus (A) and urethrogram and contrast study through accessory meatus on dorsal glans penis showing accessory urethra communication with native urethra (B).

Parents denied for a discharge or urine from this accessory meatus. Both testes were descended, and the scrotum was normal. His perineal examination showed a perianal abscess at 7 o'clock position, which was drained. His urine was sterile and a renal ultrasound was normal. A combined urethrogram and contrast study through accessory meatus at glans revealed an accessory tube communicating with the bladder neck [Fig. 1B].

Under general anesthesia and in supine position, the accessory tube was cannulated with fine probe and a circumferential dissection was carried around it to dissect it free from penile tissues. The skin was degloved and the accessory tube was mobilized up to its origin while the neurovascular bundle had been safely guarded on either side. The accessory tube was then transfixed with vicryl 3/0 and excised [Fig 2]. The approximate length of excised tube was 3.5 cm and its proximal and distal ends were marked with sutures for histopathological identification [Fig 2]. The degloved penis was reconstructed and a urethral stent kept for 72 hrs.

Histology of the excised tube revealed urothelium lined tissue suggestive of accessory urethra. At six months of follow up, the boy has been well and voiding satisfactory.

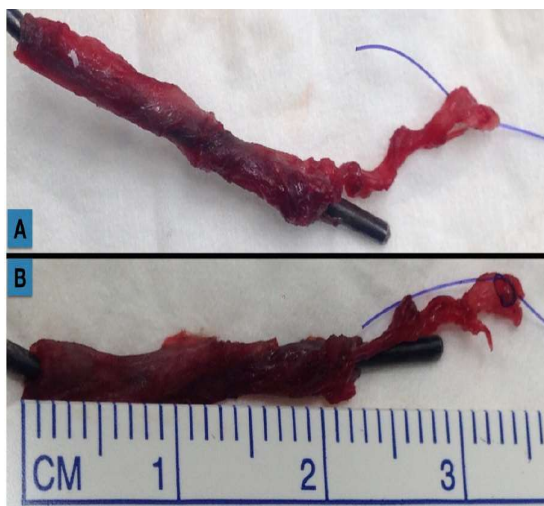

Fig. 2. After excision accessory urethra over a probe (A) and approximate length of the excised urethra was more than 2 cm. (B)

Discussion

Accessory urethra (double or triple) is a rare congenital genitourinary abnormality; the anomaly is unique to males, with few cases reported in females [1,3,4]. The embryology of this rare abnormality is poorly understood and various theories have been proposed. Das and Brosman proposed that abnormal termination of the Müllerian duct results in accessory urethra [5]. Casselman and Williams suggested a partial failure or an irregularity of growth of the lateral mesoderm between the ectodermal and endodermal layers of the cloacal membrane in the midline, which results in a dorsal epispadiac channel [6]. While Rice et al. suggested that asymmetry in the closure of the urorectal septum may have been

contributory to form an urethroperineal fistula [7].

Because of its embryological complexity various classifications have been proposed for accessory urethra, but Effmann's classification [8] is widely accepted among clinicians as it represents all the clinical aspects of accessory urethra. According to published literature, the most common variant is Effmann type 2A2 with Y-Urethral Duplication [1, 2, 9, 10], where as our patient fits into Effmann's type 2A1, which consists of accessory urethra from the bladder neck to the glans penis and it was lined with urothelium.

The diagnosis of accessory urethral is principally clinical and followed by voiding cystourethrography and retrograde urethrography for visualization of the size, shape and point of insertion or communication with native urethra or urinary bladder. In some cases, there are associated anomalies such as unilateral renal agenesis, ureteral duplication and duplicated bladder, which can be assessed by ultrasound or MRI [2]. If imaging is inconclusive then cystourethroscopy is required to assess the anatomy of accessory urethra to plan for surgical intervention. The differential diagnosis includes post circumcision urethrocutaneous fistula, congenital anterior urethrocutaneous fistula,

lacuna magna (which is a problem especially in patients with hypospadias, when the lacuna lies distal to the meatus), urethral diverticulum and dilated Cowper's gland. Surgical intervention is required due to double stream, urinary incontinence, recurrent urinary tract infections, obstructive symptoms, associated genitourinary anomalies and for cosmetic reasons. Although surgical plan varies according to anatomical type and associated genitourinary malformations, it consists of proper visualization and excision of the accessory urethra without damaging the native urethra and bladder neck. If there is an incomplete excision or a residual tract is remained, it may result into future infections.

References

1. Onofre LS, Gomes AL, Leao JQ, Leao FG, Cruz TM, Carnevale J. Urethral duplication--a wide spectrum of anomalies. *Journal of pediatric urology*. 2013;9(6Pt B):1064-71.
2. Salle JL, Sibai H, Rosenstein D, Brzezinski AE, Corcos J. Urethral duplication in the male: review of 16 cases. *The Journal of urology*. 2000;163(6):1936-40.
3. Mane SB, Obaidah A, Dhende NP, Arlikar J, Acharya H, Thakur A, et al. Urethral duplication in children: our

We emphasize the significance of high index of suspicion when a clinician examines external genitalia at time of ritual circumcision. Presence of an accessory opening at glans urethra, in penile shaft on dorsal or ventral aspect, in perineum with or without passage of urine should lead to further evaluation and management. In our case, the diagnosis was delayed even though the clinical examination was strongly suggestive.

Acknowledgements

The author(s) declare that they have no competing interests and financial support.

- experience of eight cases. *Journal of pediatric urology*. 2009;5(5):363-7.
4. Haleblian G, Kraklau D, Wilcox D, Duffy P, Ransley P, Mushtaq I. Y-type urethral duplication in the male. *BJU international*. 2006;97(3):597-602.
5. Das S, Brosman SA. Duplication of the male urethra. *The Journal of urology*. 1977;117(4):452-4.
6. Casselman J, Williams DI. Duplication of the urethra. *Acta urologica Belgica*. 1966;34(4):535-41.

7. Rice PE, Holder TM, Ashcraft KW. Congenital posterior urethral perineal fistula: a case report. *The Journal of urology*. 1978;119(3):416-7.
8. Effmann EL, Lebowitz RL, Colodny AH. Duplication of the urethra. *Radiology*. 1976;119(1):179-85.
9. Fernandez-Pineda I, Fernandez-Hurtado MA, Barrero Candau R, Garcia Merino F. Urethral duplication: case report and review of the literature]. *Actas urologicas espanolas*. 2010;34(5):480-1.
10. Arena S, Arena C, Scuderi MG, Sanges G, Arena F, Di Benedetto V. Urethral duplication in males: our experience in ten cases. *Pediatric surgery international*. 2007;23(8):789-94.

Access this article online

<http://pediatricurologycasereports.com>

Quick Response Code

