

**PEDIATRIC UROLOGY CASE REPORTS**

ISSN 2148-2969

<http://www.pediatricurologycasereports.com>**Acute bilateral ureteral obstruction following Dextranomer/hyaluronic acid polymer injection: A case report****Arnon Lavi, Sharon Tzemah, Alon Mashiah, Zvi Katz, Michael Cohen***Department of Urology, Haamek medical center, Afula, Israel***ABSTRACT**

Ureteral obstruction following bulking agent injection for treatment of vesicoureteral reflux is rare. Herein we report a case of acute bilateral ureteral obstruction following bilateral Dextranomer/hyaluronic acid polymer injection. The obstruction which manifested hours following the injection, was treated with prompt insertion of bilateral ureteral stents. The stents were removed 4 weeks later with complete resolution of the obstruction. We believe that ureteral stenting is an excellent solution for acute ureteral obstruction following Dextranomer/hyaluronic acid polymer injection.

**Key Words:** Vesicoureteral reflux; subureteral injection; Dextranomer/hyaluronic acid polymer; stent.

*Copyright © 2017 pediatricurologycasereports.com*

**Corresponding Author:** Dr. Arnon Lavi

*Urology department, Haamek medical center, Rabin Blvd. 21, Afula, Israel*

*E mail: [arnonmlavi@gmail.com](mailto:arnonmlavi@gmail.com)*

*Accepted for publication: 23 March 2017*

**Introduction**

Endoscopic correction of low grade vesicoureteral (VUR) with bulking agents has solely replaced the use of open ureteral re-implantation as first line treatment [1]. The success rate of Dextranomer/hyaluronic acid polymer (Dx/Ha) injection is excellent and reported to be as high as 84%-93% for overall treatment [2-4].

Complications are usually mild and include flank pain, postoperative cystitis, rarely pyelonephritis and de-novo contralateral VUR. Ureteral obstruction has been reported to be

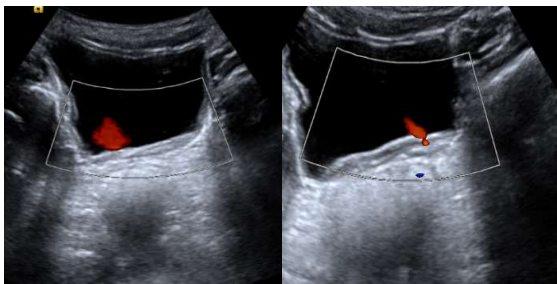
extremely rare with a reported incidence of 0.7-2.1% [5,6]. Obstruction may present in the acute or late setting. We present the first reported case of acute bilateral ureteral obstruction following bilateral Dx/Ha injection in a 6 year old girl.

**Case report**

The patient was first referred to our clinic at 32-months of age for evaluation of recurrent urinary tract infection (UTI). A voiding cystourethrogram (VCUG) revealed a bilateral grade 2 VUR. Dimercaptosuccinic acid (DMSA) scan showed differential function of 65% & 35% on the right and left kidneys, respectively with scars on the upper and lower left poles. She was scheduled for bilateral

bulking agent injection for which her parents refused and disappeared from follow-up.

During the next 3 years she continued to experience breakthrough UTI's some of which were febrile (under prophylactic cephalexin treatment). A repeated DMSA scan 4 years later reveals now a worsening left kidney function (differential function of 80% to the right & 20% to the left) with a new right upper pole scar. At that time she was again referred to our clinic and a bilateral Dx/Ha injection was carried out with 1 cc and 0.8cc injected to the left and right orifices, respectively, using the hydrodistention implantation technique (HIT). Intraoperative cystoscopic results were good and a urethral catheter was left indwelling. The procedure was otherwise uneventful. In the hours following the procedure the patient was anuric despite adequate hydration and complained of bilateral flank pain. Post procedure serum creatinine rose to 2.3 mg/dl (from a baseline of 0.5 mg/dl). Bedside sonography revealed bilateral hydronephrosis. Bilateral indwelling ureteric stents were placed the following morning under general anesthesia with subsequent normal urine output and a prompt decline in serum creatinine to baseline. Four weeks later the stents were removed uneventfully. Eight weeks after the initial procedure ultrasonography revealed no hydronephrosis and good bilateral ureteral jets [Fig. 1].



**Fig. 1.** Bilateral ureteral jets on sonography 8 weeks post injection.

On 3 months follow-up the patient didn't develop breakthrough UTI's. A follow up VCUG is scheduled.

### Discussion

The use of Dx/Ha injection for vesicoureteral reflux is well established and is currently the preferred agent used in most centers worldwide [7]. Post procedure follow up usually consists of ultrasound and VCUG [8]. Ureteral obstruction following Dx/Ha injection is uncommon. Snodgrass reported the first case of obstruction following Dx/Ha injection in 2004 [9]. Vandersteen et al reported in their multicenter study of 745 patients with 1155 ureters injected with Dx/Ha (up to 1CC), a rate 0.7% postoperative ureteral obstruction [5]. All patients were treated with indwelling ureteral stent placement, with resolution of symptoms after placement and no recurrence upon removal in all patients. 4 of the 5 patients reported developed an acute obstruction. In their report only 1 (14%) obstructed ureter had a previously demonstrated grade 2 reflux while the others had higher grades. 80% of the children reported had reflux secondary to myelomeningocele or dysfunctional voiding. Baybikov recently reported an unpublished retrospective multicenter analysis of 4898 ureters injected with different bulking agents including Dx/Ha with a 0.7% obstruction rate. Of the 33 ureters obstructed, 12 occurred in the acute setting (first 24 hours), of them one was anuric with a single kidney. Ureteral stenting was the initial management in 6 of the acutely obstructed patients. Of these, 5 were successfully treated with stenting alone. Stenting in the late obstruction group was unsuccessful in all ureters stented [10]. It should be noted that others reported a slightly higher incidence of obstruction than 0.7% [6].

Most cases concerning ureteral obstruction have been reported in the late period following injection rather than the acute setting. The only reported case of bilateral obstruction following Dx/Ha injection was reported by Nseyo et al. but this occurred 11 months after the injection [11].

As others previously proposed, we believe that the most reasonable etiology for acute ureteral obstruction following Dx/Ha injection is transient orifice edema secondary to injection related trauma combined with the Dx/Ha mound. This is most reasonable given the standard and acceptable low volume of Dx/Ha injected.

As previously reported [5], visualization of the orifice in the acute setting is difficult when attempting stent insertion but directing the guide wire to the apex of the newly formed mound made catheterization of the orifice straightforward. We recommend that the injecting urologist be present upon stent insertion to better direct stent placement, especially when preformed in the acute setting. Ureteral obstruction following Dx/Ha injection is a serious though rare complication requiring urgent attention and treatment. Insertion of an indwelling ureteral stent is an excellent management option in the acute setting with good results.

#### Acknowledgements

The author(s) declare that they have no competing interest and financial support.

#### References

[1] Moliterno JA, Scherz HC, Kirsch AJ. Endoscopic treatment of vesicoureteral reflux using dextranomer hyaluronic acid copolymer. *J Pediatr Urol*. 2008;4(3):221-8.

- [2] Biočić M, Todorčić J, Budimir D et al. Endoscopic treatment of vesicoureteral reflux in children with subureteral dextranomer/hyaluronic acid injection: a single-centre, 7-year experience. *Can J Surg*. 2012; 55(5): 301–6.
- [3] Pinto KJ, Pugach J, Saalfeld J. Lack of usefulness of positioned instillation of contrast cystogram after injection of dextranomer/hyaluronic acid. *J Urol*. 2006;176 (6 Pt 1):2654–6.
- [4] Yu RN, Roth DR. Treatment of vesicoureteral reflux using endoscopic injection of nonanimal stabilized hyaluronic acid/dextranomer gel: initial experience in pediatric patients by a single surgeon. *Pediatrics*. 2006;118(8):698–703.
- [5] Vandersteen DR, Routh JC, Kirsch AJ, et al. Postoperative ureteral obstruction after subureteral injection of dextranomer/hyaluronic acid copolymer. *J Urol*. 2006;176 (4 Pt 1):1593-5.
- [6] Scarpa AA1, Del Rossi C, Casolari E, Gatti C, Scarpa AG. Endoscopic treatment of vesicoureteric reflux in paediatric patient: results of a long-term study. *Acta Biomed*. 2011;82(2):137-45.
- [7] Khoury AE, Bagli DJ. Vesicoureteral reflux. In: Wein A; Kavoussi LR, Partin AW et al, eds. *Campbell-Walsh Urology* 11th edition. Philadelphia: Elsevier Sanders; 2015:3134-3172.
- [8] Cambareri G, Hanna M, Stock J. Practice patterns among pediatric urologists in the use of Deflux® for vesicoureteral reflux: a survey. *J Pediatr Urol*. 2013;9(6 Pt A):955-61.
- [9] Snodgrass, W. Obstruction of a dysmorphic ureter following dextranomer/hyaluronic acid copolymer. *J Urol*, 171: 395, 2004.
- [10] Baybikov R, Sizonov V, Bondarenko S et al. Treatment of uretral obstruction after

endoscopic injection in vesicouretral reflux. 26TH congress ESPU Prague, Czech Republic, 14-17th October 2015. S4-8.

- [11] Nseyo U, Mancini JG, Wiener JS. Symptomatic bilateral delayed partial ureteral obstruction after bilateral endoscopic correction of vesicoureteral reflux with dextranomer/hyaluronic acid polymer. *Urology*. 2013;81(1):184-7.

