



PEDIATRIC UROLOGY CASE REPORTS

ISSN 2148-2969

<http://www.pediatricurologycasereports.com>

An unexpected diagnosis in a girl when evaluating vesicoureteral reflux: Congenital vesicovaginal fistula

Nagihan Canturk, Esra Ozcakil, Mete Kaya

Department of Pediatric Surgery, University of Health Sciences, Yuksek Ihtisas Training and Research Hospital, Bursa, Turkey

ABSTRACT

In this case presentation, we report a case of 13-year-old girl who was referred for treatment with vesicoureteral reflux (VUR), who had complaints of frequent urinary tract infections and urinary incontinence since her birth, and was diagnosed with congenital vesicovaginal fistula (CVVF). In the fistula closure procedure, multilayer repair and ureteroneocystostomy with a transtrigonal approach was performed, and the patient did not have any complaints after the treatment. CVVF can usually be seen with other urogenital system anomalies. We aimed to present our unique case because of the challenging in diagnosis and association with VUR.

Key Words: Congenital vesicovaginal fistula, vesicoureteral reflux, bladder.

© 2020 [pediatricurologycasereports.com](http://www.pediatricurologycasereports.com)

✉ *Dr. Esra Ozcakil*

Department of Pediatric Surgery, University of Health Sciences, Yuksek Ihtisas Training and Research Hospital, Bursa, Turkey

E-mail: dr.esramermer@gmail.com

Received: 2020-08-30 / Revisions: 2020-09-27

Accepted: 2020-10-03 / Publication Date: 2020-11-01

Introduction

Although vesicovaginal fistula in children is often encountered as a complication following trauma, foreign bodies and genitourinary surgery, congenital vesicovaginal fistula (CVVF) is a very rare entity and is often associated with urogenital system anomalies [1,2]. Here, we report a case diagnosed with vesicoureteral reflux (VUR) and CVVF with frequent urinary tract infection and urinary incontinence symptoms, and we aim to discuss

the difficulties that may arise in diagnosis and to propose how such cases can be investigated and managed surgically.

Case report

A 13-year-old female patient was referred to our surgical unit for treatment of right vesicoureteral reflux (VUR). In patient's history, she had enuresis with no other symptoms since birth and voiding difficulty. She was followed up due to recurrent urinary tract infection, and had a history of multiple operations due to right congenital talipes equinovarus. There was also no previous history of vaginal, pelvic, abdominal trauma or surgery. On genitourinary examination there was no visible anomaly except the operation scars on the right foot. Laboratory tests

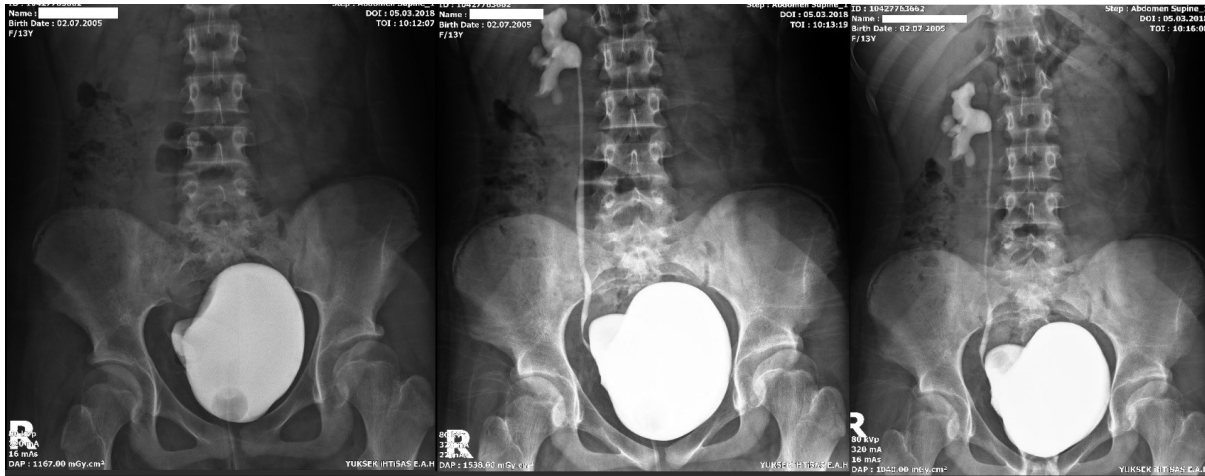


Fig. 1. Voiding cystourethrogram demonstrating grade 3 vesicoureteral reflux on the right. Vaginal contrast agent is visible on the last image.

including CBC, biochemical, and urine analysis were within normal limits. Urinary ultrasonography (US) revealed a mild right hydronephrosis. Voiding cystourethrogram (VCUG) showed a grade 3 right VUR, and vaginal reflux on micturition phase (Fig. 1). Intravenous Tc-99m dimercaptosuccinic acid renal scintigraphy (Tc-99m-DMSA) showed slightly hypoplastic right kidney, and the differential renal functions were calculated as 58% for the left kidney and 42% for the right kidney. On urodynamic study, evaluation was not optimal because of the persistent urine leakage. Cystoscopy was decided to evaluate bladder and urethra, and to treat VUR endoscopically. On cystoscopy, urethra was normal in appearance, the right ureteral orifice was not seen initially, and there was a diverticular appearance on the upper right corner of the trigon. The right ureteral orifice was barely seen when the cystoscope was inserted into the diverticular pouch, and meanwhile continuous urine leakage from the introitus was observed during the procedure. Cystoscopy was terminated, it was decided to investigate the cause of urine leakage. Magnetic resonance imaging (MRI) showed a fistula between the right posterior corner of the

bladder and the vagina (Fig. 2).

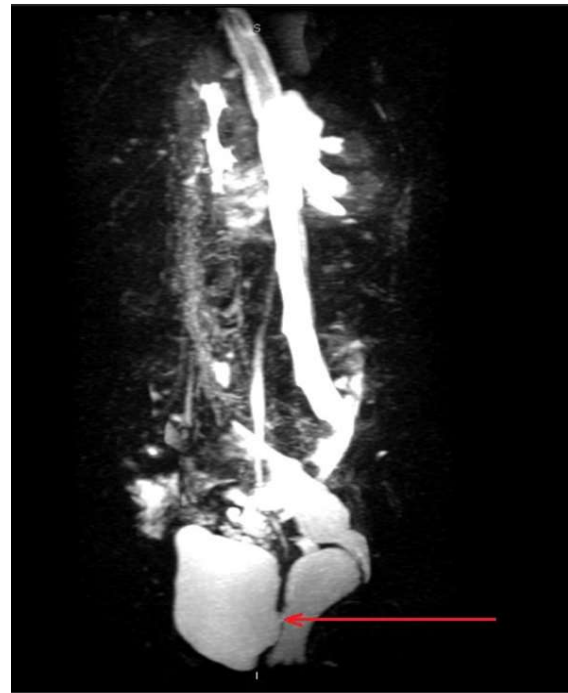


Fig. 2. Magnetic resonance imaging scan displaying the vesicovaginal fistula tract (arrow).

Elective fistula repair was planned for 3 weeks later after obtaining parental consent. Cystotomy performed with the Pfannenstiel incision, the orifice in the right ureteral orifice was catheterized, but it was seen that the

catheter came back into the bladder from the inferior opening (Fig. 3).

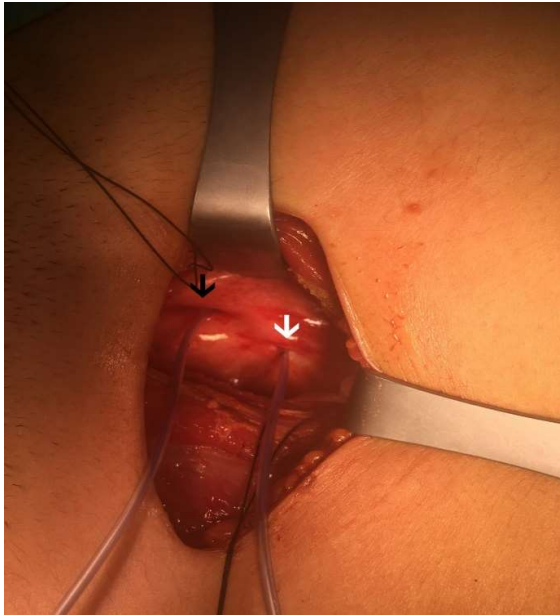


Fig. 3. Intraoperative photo showing the catheter introduced (white arrow) upper pouch of fistula and came out inferior pouch (black arrow).

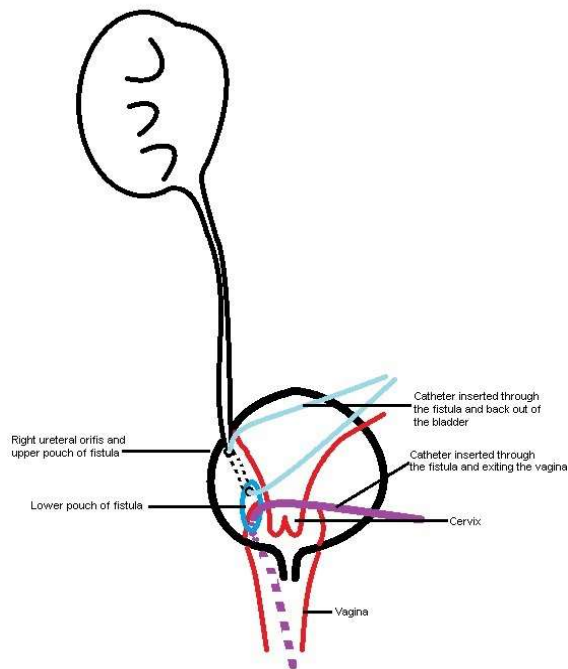


Fig. 4. Drawing shows intraoperative details.

A catheter advanced through the inferomedial opening came out of the vagina. Right ureteral orifice was found on superolateral opening. In addition, a vaginoscopy performed in the same session, the catheter was seen in the right fornix corner of the vagina, and it was confirmed the diagnosis of CVVF. Operative findings are illustrated in Fig 4. The right ureter was short and tight, and ureteroneocystostomy performed using the Politano-Leadbetter method. The fistula was repaired transtrigonally by using with 4/0 polyglactin over two layers as the vaginal and detrusor layers. Urinary and cystostomy catheters were placed.

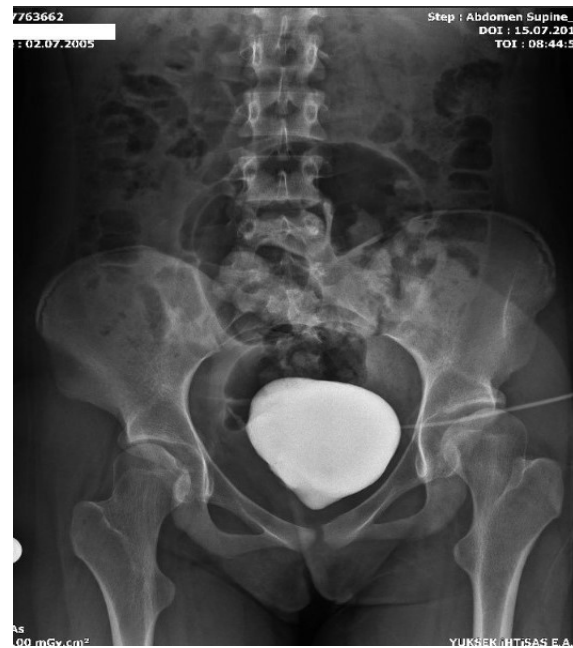

Fig. 5. A cystography revealing no fistula recurrence and vesicoureteral reflux on postoperative 15th day.

The postoperative period was uneventful, the bladder catheter was removed on the 7th postoperative day, and she was discharged when she was able to void comfortably and without leakage. Cystostomy catheter removed on postoperative day 15 after confirming no

fistula recurrence by performing cystography (Fig. 5). There was no reflux or fistula recurrence in the control VCUG on postoperative 6th month.

Discussion

CVVF is a rare condition and it can be associated with other urogenital abnormalities such as reno-ureteral malformations (renal agenesis), paramesonephric ducts (uterus didelphys, transverse vaginal septum, etc.) and skeletal (polydactyl) malformations [1,2]. Although many theories about CVVF formation are suggested, no definitive reason for embryo pathogenesis has been found. Verhoeven [3] considered CVVF as an abnormal persistence of the urogenital sinus. Singh et al. [4] concluded that CVVF occurs because of a lack of differentiation in the sinovaginal bulb. Acién and Acién [5] stated that the urogenital wedge does not progress caudally by altering urogenital sinus, leaving the embryonic vagina draining in the natural embryonic location. Martinez Escoriza et al. [1] suggested that embryologic origin of the CVVF is abnormal persistence of the urogenital sinus together with varying degrees of agenesis or hypoplasia of the entire urogenital ridge or mesonephric ducts and Mullerian ducts with corresponding reno-ureteral malformations. Suarez and Burden [6] suggested that CVVF may be the result of an abnormal fusion of the ureter bud and the caudal end of the müllerian canal with the urogenital sinus by the end of the ninth gestational week, or an incorporation of the aborted ureteral bud into a future Wolffian duct remnant. Lastly Zeineddine et al. [7] have suggested an interesting hypothesis that a VVF fistula present at birth is not—per se—the result of “faulty” embryonic development, but a result of elevated pressure due to secretions

induced by maternal estrogen. In our case, a fistula was occurred between the bladder and the vagina at the abnormal ureterovesical junction causing VUR. In fact, the close developmental relationship of paramesonephric duct and ureteral bud explains the reasons for the congenital female genital system and urinary tract anomalies to be seen together. However, coexistence of extremity anomalies and CVVF could not be associated in these cases as an embryological origin.

Although it depends on age at diagnosis and the embryopathogenic pattern, clinical symptoms in pediatric patients with CVVF are mainly urinary incontinence, urinary tract infections and hydrocolpometra, and menouria and inability to have intercourse in adults [1]. Although the CVVF is usually reported to be presented with urinary incontinence in early childhood, it has been reported that the presence of complete transverse septum may delay the diagnosis until menarche [8]. Our patient had urinary incontinence and frequent urinary tract infection since she was born. We think that the reason for the delay in the diagnosis is due to the parents focus on the foot anomaly and the staged operations she had undergone.

In published articles, US, video urodynamic studies and MRI were found to be insufficient in defining CVVF, but it was found that it is useful to examine it under anesthesia with methylene blue test and cystourethroscopy and vaginoscopy to evaluate vaginal part of fistula [9]. Since enuresis was not as the main complaint in our case, and she was referred for treatment of VUR, CVVF had been missed on VCUG, urine leakage noticed on cystoscopy, suspected on MRI, and diagnosed during surgery. When the VCUG was examined retrospectively, it was observed that the

contrast agent was dispersed in the bladder neck during the micturition phase. This overlooked condition was understood to be interpreted as urethrovaginal reflux in patients who have the symptoms of voiding dysfunction.

Since CVVF has life-limiting symptoms such as enuresis and menouria, it is an anomaly that needs to be corrected surgically. Surgical treatment can be done by transvaginal approach, transvesical approach and laparoscopic and robot assisted repair [1-10]. Surgical repair in adults and CVVFs with vaginal anomalies was mostly repaired transvaginally. The surgical technique to be chosen depends on the location of the malformation and associated anomalies. In our case, the right ureter was opening to the fistula, but there was a second fistula separated by a bridge in the inferomedial part of the superolateral fistula. Asanuma et al. [2] had reported a similar case who was diagnosed CVVF along with ectopic ureter, and transtrigonal fistula repair and ureteroneocystostomy had been performed. Although the diagnosis of CVVF was made intraoperatively in our case, it could be performed transtrigonally. In cases where the borders of the fistula could not be determined exactly, it could be performed transvaginal or abdominal route. Ureteral reimplantation was performed both because of VUR and because the ureter was opened into the fistula. Indeed, it was noticed that ureteral reimplantation was rarely added, in cases with published CCVF regardless of the presence of VUR [1]. This indicates that the fistula and ureteral orifices are too close in those cases.

Conclusion

Because of rarity, CVVF should definitely be taken into consideration in female patients

with urinary incontinence and frequent urinary tract infections. Outcome of our unique case was satisfactory, although diagnosis of our case was delayed and had two fistula connected by a bridge. Transtrigonal repair with layers may be among the treatment options in selected patients with CVVF.

Compliance with ethical statements

Conflicts of Interest: None.

Financial disclosure: None.

Consent: Patient confidentiality is maintained and written consent for the publication of patient details and clinical pictures in this journal has been obtained from the patient's parents or closest relative and can be given as required.

ORCID iD of the author (s)

Nagihan Canturk / 0000-0002-4403-6799

Esra Ozcakir / 0000-0002-0773-7430

Mete Kaya / 0000-0002-8877-5737

References

- [1] Martínez Escoriza JC, Palacios Marqués AM, López Fernández JA, et al. Congenital vesicovaginal fistula with or without menouria: a literature review. *Eur J Obstet Gynecol Reprod Biol.* 2014 ;175:38-48.
- [2] Asanuma H, Nakai H, Shishido S, et al. Congenital vesico vaginal fistula. *Int J Urol.* 2000;7(5):195-98.
- [3] Verhoeven AT. Primary menouria due to congenital vesico vaginal fistula. *Obstet Gynecol.* 1973;41(4):515-20.
- [4] Singh V, Sinha RJ, Mehrotra S. Primary menouria due to a congenital vesico-vaginal fistula with distal vaginal agenesis: a rarity. *Int Urogynecol J.* 2011;22(8):1031-1033.
- [5] Acién P, Acién MI. The history of female genital tract malformation classifications

- and proposal of an updated system. *Hum Reprod Update.* 2011;17(5):693-705.
- [6] Suarez GM, Burden JJ. Isolated congenital vesicovaginal fistula. *J Urol.* 1983;129(2):368-370.
- [7] Zeineddine HA, Nassif J, El-Hout Y, et al. Congenital vesicovaginal fistula: spontaneous or forced? Two cases and literature review. *Int Urogynecol J.* 2014;25(9):1167-172.
- [8] Kumar S, Mandal A, Acharya N, et al. Congenital vesicovaginal fistula with transverse vaginal septum and ectopic ureteropening in proximal vagina: case report and brief review. *Int Urogynecol J Pelvic Floor Dysfunct.* 2007;18(8):959-61.
- [9] Dolan LM, Easwaran SP, Hilton P. Congenital vesicovaginal fistula in association with hypoplastic kidney and uterus didelphys. *Urology.* 2004;63(1):175-77.
- [10] Wong YS, Tam YH, Pang KKY, et al. Robotic repair of congenital vesicovaginal fistula masquerading as a ureterocele in a 10-year-old girl. *Urol Case Rep.* 2018;20:48-50.