

An unusual cause of neonatal introital mass, paraurethral (Skene's duct) cysts: A case report and review of the literature

Jayalaxmi S Aihole, Narendra Babu M, Deepak J

Department of Pediatric Surgery, Indira Gandhi Institute of Child Health, Bangalore, Karnataka, India

Abstract

Paraurethral cysts or Skene's duct cysts are a rare cause of inter labial mass in a neonate. The precise etiology of paraurethral cyst is unknown. A thorough urologic evaluation was required to differentiate it from an ectopic ureterocele, urethrocele, urethral diverticula, and benign or malignant urethral and paraurethral tumors. A day 7 female baby was brought to us with history of asymptomatic introital mass noticed at day 4 of life. It was displacing urethra supero-laterally to the left and the vagina inferiorly with normal cystogenitoscopy. Simple excision of cyst was done uneventfully. Though asymptomatic, because of cosmetic and parental anxiety, and for a definitive diagnosis, simple excision of cyst was done uneventfully without recurrence.

Keywords

Newborn; para urethral cyst; Skene's duct cyst.

Copyright © 2016 pediatricurologycasereports.com.

Corresponding Author: Jayalaxmi Shripati Aihole
*Department of Pediatric Surgery, Indira Gandhi
Institute of Child Health, Bangalore, Karnataka, India*
E-mail: jayalaxmisaihole@yahoo.com
Accepted for publication: 18 April 2016

Introduction

Paraurethral cysts are a rare cause of interlabial mass in females, particularly in the neonatal period [1,2]. Incidence of paraurethral cysts is reported to be between

1/500 to 1/7000 [2]. These cysts are derived from an obstruction of Skene's glands and presents as a small, yellow or whitish inter labial mass. They are usually diagnosed by physical examination. The management of paraurethral cysts is a controversial topic. These cysts are generally asymptomatic and spontaneous regression is expected, which takes few weeks to few months, though exact period has not been specified [1-3]. The

surgical management include needle aspiration, incision and marsupialization, partial excision to total excision [1-3]. We are reporting a case of paraurethral duct cyst in a neonate which was treated by simple excision.

Case Reports

A day 7 female baby was brought to us with history of introital mass noticed at day 4 of life. Baby was born by full term normal vaginal delivery, with birth weight of 4kg. Baby's antenatal scans were unremarkable. The swelling was asymptomatic and was noticed during bathing the baby. There were no urinary or bowel disturbances.

Clinical examination revealed a 2.5 × 1.5 cm yellowish firm mass at introitus, with no clear

and red arrow indicating the tip of artery forceps in the vaginal orifice.

Baby was subjected to examination under anesthesia (EUA) after a screening abdominopelvic ultrasound which was essentially normal. EUA revealed a firm mass in the introitus; which was displacing the urethra supero-laterally and to the left, and the vagina to inferiorly. Cystogenitoscopy was normal. Simple excision of cyst was done, which contained mucous milky material. The urethral catheter was removed at the completion of the procedure [Fig. 1B].

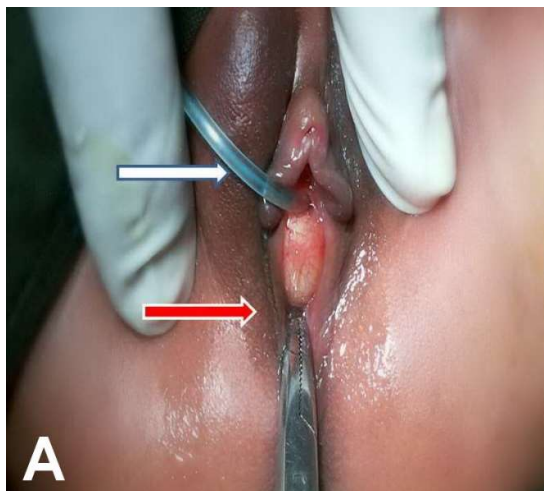


Fig. 1. (A) Per operative appearance-white arrow indicating the catheter in the urethra

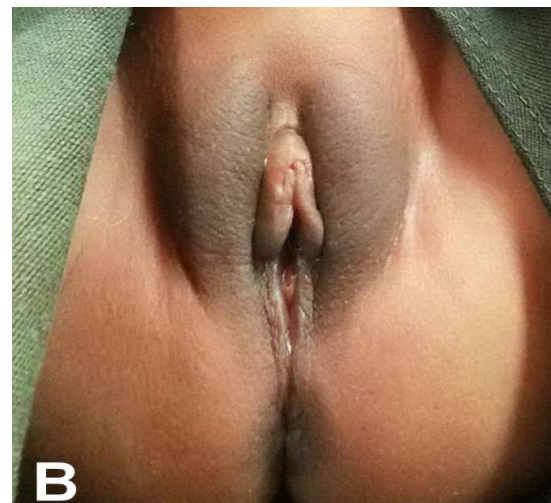


Fig. 1. (B) Postoperative appearance.

Histopathological evaluation revealed features of para urethral cyst [Fig. 2A,B]. The cyst fluid was sterile microbiologically.

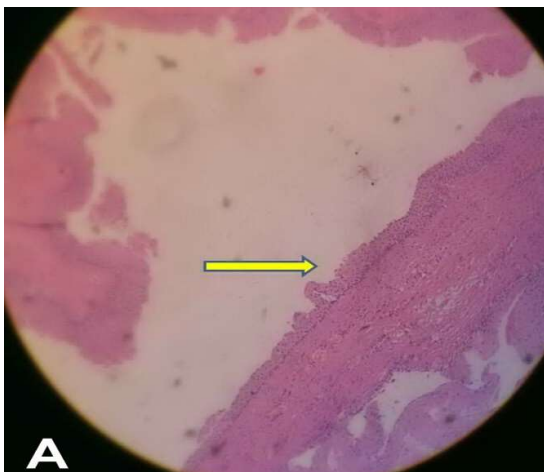


Fig. 2. (A) Yellow colored arrow indicating - Cyst wall lined by stratified squamous epithelium.

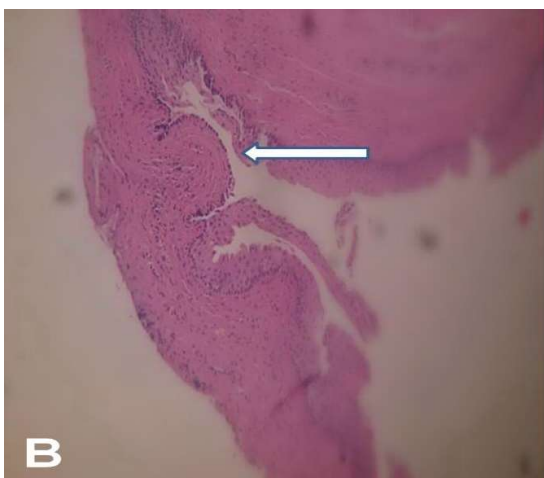


Fig. 2. (B) White colored arrow indicating - focal area of columnar epithelium.

Discussion

Skene's glands or paraurethral glands were first described by Scottish gynecologist Alexander Johnston Chalmers Skene in 1880 [1]. In an anatomic study, Huffman reported the presence 6 to 30 ducts in a normal female

infant, which represent the homologue of the male prostate gland [2,4]. After the others duct regression, the largest of these are referred as Skene's glands, which secrete little mucous material that on sexual stimulation into the distal two third of the urethra [2,5,6]. These glands and ducts may lead to cyst formation due to ductal obstruction as a result of infection or inflammation [5,7]. Only 50 neonates with paraurethral cysts have been reported in English literature to date [6].

The exact mechanism of obstruction of the Skene's gland is unclear. However, there are some theories including tissue dislocation, infection or inflammation, or maternal estrogens contributing to glandular production and subsequent blockage. In the neonate, these cysts typically appear as a solitary bulging mass (1 cm average size) with small vessels on a thin walled, yellowish-colored or whitish interlabial protrusion located adjacent to one side of the urethral meatus and often slightly distorting it [8]. The cyst wall lining can consist of columnar to transitional to cuboidal epithelial cells and the cyst is filled with milky-colored liquid [9,10]. Finding a transitional epithelium will confirm the origin to be in the urinary tract, since the distal vaginal wall, Skene's ducts, paraurethral glands and urethra all are derived from urogenital sinus [1].

Paraurethral cysts can be diagnosed on the basis of physical examination. Clinical examination in good light with relaxation under general anesthesia will be sufficient for the clinical diagnosis [11]. They are asymptomatic, non-tender, soft, cystic ovoid masse, yellowish in color and located on either side of the urethral meatus [12,13]. Paraurethral cysts are usually single, but bilateral cysts have been reported [8,14]. Paraurethral cysts are slightly more common on right side. Renal ultrasound and further urological investigation is mandatory in cases of urinary outflow obstruction [8].

The differential diagnosis of in newborns includes prolapsed ectopic ureterocele, imperforate hymen, genital prolapse, prolapsed yolk-sac tumor, and rhabdomyosarcoma (sarcoma botryoides) of vagina, Gartner duct cyst, Mullerian duct cyst, condyloma, urethral polyp, and congenital lipoma [1,2,3].

The choice of management for this lesion remains controversial because of the benign nature of paraurethral cysts and the chance of

spontaneous regression. The possible surgical procedures are excision, marsupialization and needle aspiration [2,7]. Surgical intervention is indicated only in cases of urethral obstruction or delayed regression [11]. Recent studies suggest that non-operative therapeutic approaches are more appropriate because of regression spontaneously after 3 months because of decreasing maternally acquired female hormones [1,15]. However, surgical interventions are performed in some asymptomatic neonates [11].

Though asymptomatic, because of cosmetic and parental anxiety, we treated the case of Skene's duct cyst successfully with simple excision uneventfully. However, since paraurethral cysts are asymptomatic lesions in nature and spontaneous resolution has been reported, an initial conservative approach is advisable in asymptomatic cases.

Acknowledgements

The author(s) declare that they have no competing interests and financial support.

References

1. Moralioglu S, Bosnali O, Celayir AC, Sahin C. Paraurethral Skene's duct cyst in a newborn. *Urol Ann.* 2013(5):204-5.
2. Fujimoto T, Suwa T, Ishii N, Kabe K. Paraurethral cyst in female newborn: is surgery always advocated? *J Pediatr Surg.* 2007(2); 42:400-3.

3. Al-Abbasi BK. Symptomatic paraurethral cyst in female neonate case report and review of literature. *Ann Coll Med.* 2008; 34(2):180-2
4. Huffman JW. The detailed anatomy of the paraurethral ducts in the adult female. *Am J Obstet Gynecol.* 1948; 55(1):86-101.
5. Soyer T, Aydemir E, Atmaca E. Paraurethral cysts in female newborns: role of maternal estrogens. *J Pediatr Adolesc Gynecol.* 2007;20(4):249-51.
6. Badalyan V, Burgula S, Schwartz RH. Congenital paraurethral cysts in two newborn girls: differential diagnosis, management strategies, and spontaneous resolution. *J Pediatr Adolesc Gynecol.* 2012;25(1):e1-e4
7. Fathi K, Pinter A. Paraurethral cysts in female neonates. Case reports. *Acta Paediatr.* 2003;92(6):758-9.
8. Lee NH, Kim SY. Skene's duct cysts in female newborns. *J Pediatr Surg.* 1992; 27(1): 15-7.
9. Gillenwater J, Howards S, Grayhack J, et al, editors. *Adult and Pediatric Urology.* Philadelphia, Lippincott Williams & Wilkins, 2002, pp 2503-4.
10. Johnson CT, Millard SE, Wang MH, Ehsanipoor RM. Prenatal diagnosis of a paraurethral cyst. *J Pediatr Urol.* 2013;9(1):e91-3.
11. Nakamura E, Shintaku S, Horii M, Manabe H, Hirano Y, Muroso K. Early regression of paraurethral cyst in a neonate. *Pediatr Neonatol.* 2014; 55(3):225-7.
12. Bergner DM. Paraurethral cysts in the newborn. *South Med J.* 1985; 78(6): 749-50.
13. Blavias JG, Pais VM, Retik AB. Paraurethral cysts in female neonates. *Urology.* 1976; 7(5): 504-7.
14. Nussbaum AR, Lebowitz RL. Interlabial masses in little girls: review and imaging recommendations. *ARJ Am J Roentgenol.* 1983;141(1): 65-71.
15. Yilmaz Y, Celik IH, Dizdar EA, et al. Paraurethral cyst in two female newborns: which therapy option? *Scand J Urol Nephrol.* 2012;46(1):78-80.

Access this article online

<http://pediatricurologycasereports.com>

Quick Response Code



Pediatric Urology Case Reports is an open access journal. Articles published in this journal are licensed under the Creative Commons Attribution 4.0 International License (see <http://creativecommons.org/> and <http://creativecommons.org/licenses/by/4.0/>).