

Canal of Nuck cyst masquerading as a testicle in a neonate:

A case report and review of the literature

Lelah Grossman¹, Mark Horowitz^{1,2}, Jeremy Neuman^{3,4}, Richard Sidlow^{1,5}

¹Department of Pediatrics, Staten Island University Hospital, Staten Island, New York, USA

²Department of Urology, Cornell University, New York, New York, USA

³Department of Radiology, Staten Island University Hospital, Staten Island, New York, USA

⁴Department of Radiology, State University of New York-Health Science Center at Brooklyn, Brooklyn, New York, USA

⁵Department of Pediatrics, Hofstra Northwell School of Medicine, Hempstead, New York, USA

Abstract

Canal of Nuck cysts/hydroceles are rare occurrences in females of all age groups. We describe a case of a female neonate presenting with a labial mass which sonographically resembled a testicle. Upon surgical exploration, it was found to be a hydrocele of the canal of Nuck. We also review the literature on canal of Nuck cysts/hydroceles in the pediatric age group.

Keywords

Canal of Nuck; female hydrocele; labial mass, neonate, pediatric.

Copyright © 2016 [pediatricurologycasereports.com](http://www.pediatricurologycasereports.com).

Corresponding Author: Richard Sidlow, Staten Island University Hospital, Department of Pediatrics, 475 Seaview Avenue, Staten Island, New York, 10305, USA

E-mail: rsidlow@northwell.edu

Accepted for publication: 30 September 2016

Introduction

The canal of Nuck, also known by its Latin name *processus vaginalis peritonea femininus*, was first described by the 17th century anatomist Anton Nuck in 1691. It consists of an abnormal patency of an outpouching of parietal peritoneum that

follows the round ligament, as guided through the inguinal canal by the gubernaculum, to the labia majora. Cysts/hydroceles of this canal, also known as a female hydrocele (hydrocele muliebris), should not occur if complete obliteration of the canal is achieved. When the canal remains patent, these cysts/hydroceles can be a rare cause of inguinal or vulvar swelling in females, as well as being the source of indirect hernias [1-5]. This rare entity has been described in females of all ages, but rarely in girls under 2 years of age. We

present a case of a female neonate presenting with a right-sided labial mass which sonographically resembled a testicle which was found to be a canal of Nuck cyst upon surgical exploration.

Case Report

A full term healthy baby girl was born via repeat cesarean section to a G4P3013 mother whose pregnancy and past medical history were unremarkable. On physical exam, the only abnormality noted was asymmetric swelling of the right labia majora. Upon palpation a firm, rubbery, noncompressible mass approximately 2cm in length, 1cm in width, and 1cm in thickness was appreciated. Her external genitalia were otherwise normal.

A soft tissue ultrasound of the right labia revealed a homogeneously solid structure compatible with a normal appearing testicle measuring 1.7 cm by 0.9 cm accompanied by a normal appearing epididymis [Fig. 1-3].

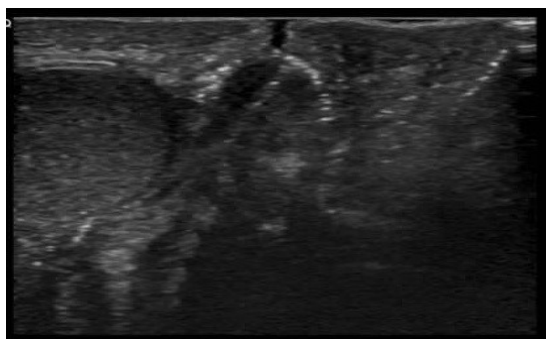


Fig. 1. Transverse sonographic image through the midline at the level of the labia demonstrates

a round structure in the right labia with homogeneous internal echoes.

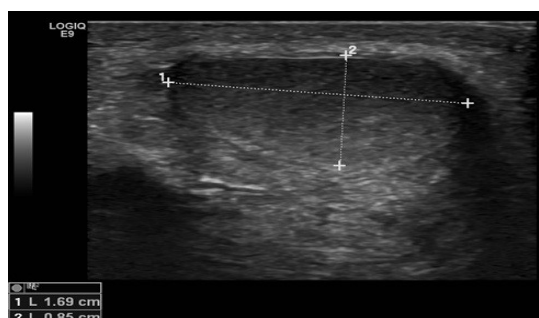


Fig. 2. Longitudinal sonographic image of the structure in the right labia again demonstrates homogeneous internal echoes with an appearance and shape typical of a testicle. Through transmission, which would be typical of a cyst, is not present.

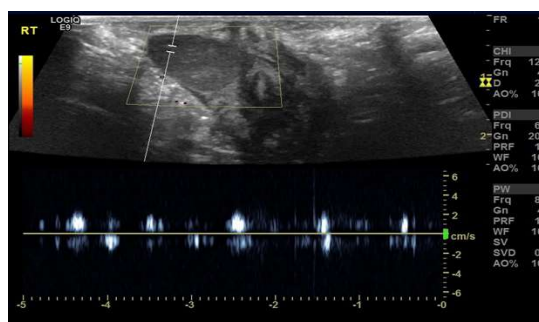


Fig. 3. Spectral Doppler waveform image appears to reveal a faint arterial waveform within the lesion.

A pelvic ultrasound and a fluoroscopic genitogram were performed. The pelvic ultrasound revealed bilateral, normal follicle-containing ovaries and a normal uterus, with the genitogram confirming the patient's normal female genitourinary anatomy without fistulous connection.

Multiple hormone levels and chromosomal studies were drawn [Table 1], with all results from this arm of the workup subsequently being consistent with a normal newborn female.

Table 1. Multiple hormone levels and chromosomal studies.

Analyte	Result	Reference Range
Leutinizing hormone	0.02 mIU/ml	None established
Follicle stimulating hormone	<0.09 mIU/ml	None established
Total serum testosterone	247.7ng/dl	None established
Dihydrotestosterone	<5ng/dl	None established
Ultra sensitive estrogen	<2pg/ml	< or= 16 pg/ml
Free serum cortisol	0.07 mcg/dl	None established
Anti-Mullerian hormone	2.74 ng/ml	None established
Dehydroepiandrosterone	312 ng/dl	None established
17-hydroxyprogesterone	76 ng/dl	11-170 ng/dl
Karyotype	46, XX	46, XX
FISH for SRY	negative	negative

The patient underwent a diagnostic laparoscopy and right groin exploration on day 3 of life. During laparoscopy a normal uterus and left ovary were visualized. The right ovary was not easily visualized, and there was tissue appearing to migrate towards the closed right internal inguinal ring from the normal location of the right ovary, consistent with an inguinal hernia. At open exploration, a cystic structure was identified in the proximal part of the inguinal canal after opening the external oblique aponeurosis. Five to ten milliliters of what proved to be sterile fluid was aspirated

from this cyst, and its walls were sent for pathologic analysis, yielding a diagnosis of an epithelial inclusion cyst consisting of benign fibrous connective tissue covered by non-keratinizing squamous mucosa.

Discussion

While hundreds of cases of canal of Nuck cysts/hydroceles exist in the literature, this rare entity only comprises 5-12% of the etiologies of all vulvar swellings in females of all ages [1,2]. Few have been reported in pediatric patients, and none to date have been reported in neonates [1,3,4,5]. In addition to its sonographic appearance, the nature and location of our patient's labial mass demanded a full workup for disordered sexual differentiation, this being due to a strong association between physical findings consistent with gubernacular malfunction (including hydroceles/cysts/hernias of the canal of Nuck) and renal or mullerian structure anomalies and agenesis (in this case, most likely XX male syndrome) [6,7]. Independent of our patient's sonographic finding, surgical exploration of the patient's labial mass was indicated since in 15-20% of patients with a hernia of the canal of Nuck contain an ovary and are at risk for ovarian torsion or incarceration [7]. Most importantly, given the questions raised by the labial sonographic findings in light of

remainder of the radiologic workup, it was deemed imperative that the nature of the labial mass be defined in order to provide the parents of this infant with a definitive gender for their child.

For the diagnosis of hydroceles of the canal of Nuck, ultrasound is the imaging modality of choice, with computed tomography and magnetic resonance imaging being used rarely. Sonographic features characteristic of a canal of Nuck finding include a well-defined, hypoechoic or anechoic mass, ranging in morphology from a “comma-shaped” lesion with its tail directed toward the inguinal canal, to a “cyst-in-cyst” appearance, or a multiseptated lesion within the labia majora or inguinal region [3,5,8,9,10]. None of these were noted in our patient. Our patient’s sonographic findings, both morphologically and in terms of blood flow pattern, were consistent with both testicular and epididymal tissue. Retrospectively, the dense proteinaceous contents of the cyst in combination with motion artifact and/or an arterial waveform detected immediately adjacent to the cyst probably contributed to the misinterpretation of the cyst as a testicle.

It was only upon surgical exploration and excision did the true nature of this lesion become clear, with its histologic findings being consistent with canal of Nuck’s

peritoneal origin, consisting of linings of cuboidal or flattened mesothelial cells and being filled with fluid.

Complications of a cyst/hydrocele of the canal of Nuck include infection, hemorrhage, or retroperitoneal extension of a large cyst. Curative treatment requires surgical excision since aspiration of the cyst has a risk of recurrence.

The most common differential diagnosis for cysts/hydroceles of the canal of Nuck is the inguinal hernia, with one third of cases being associated with indirect inguinal hernias [9]. One percent of cases suspected of being inguinal hernias in children were found to be hydroceles of the canal of Nuck [9]. The use of Valsalva maneuvers with ultrasound can be used to aid in the differentiation of canal of Nuck cysts from inguinal hernias [6].

Groin masses have a broad differential diagnosis in adults and children, including inflammatory lesions, hematomas, benign and malignant tumors, and most commonly, hernias with or without bowel or fat contents, with or without communication with the peritoneal cavity [10]. In neonates, however, the differential diagnosis includes disorders of sexual differentiation as well. This case brings to light the fact that in the process of diagnosis of groin masses in neonates, the physical exam, laboratory

tests, and radiologic workup are fraught with ambiguity: only surgical diagnosis is definitive.

References

1. De Meulder F, Wojciechowski M, Hubens G, Ramet J. Female hydrocele of the canal of Nuck: A case report. *Eur J Pediatr.* 2006; 165(3): 193-4.
2. Tubbs RS, Loukas M, Shoja MM, Salter EG, Oakes WJ. Indirect inguinal hernia of the urinary bladder through a persistent canal of Nuck: Case report. *Hernia.* 2007; 11(3): 287-8.
3. Erkok AS. A rare cause of inguinal mass in a female child: Hydrocele or cyst of the canal of Nuck. *Ped Urol Case Rep.* 2014; 1(1): 16-18.
4. Janssen K, Klinkner D, Kumar T. Encysted hydrocele of canal of Nuck: A case report with review of literature. *J Surg Tech Case Rep.* 2011; 3(2): 97-98.
5. Park SJ, Lee HK, Hong HS, et al. Hydrocele of the canal of Nuck in a girl: Ultrasound and MR appearance. *Br J Radiol.* 2014; 77(915): 243-4.
6. Pandey A, Jain S, Verma A, Madhu J, Srivastava A, Shukla RC. Hydrocele of the canal of Nuck-rare differential for vulvar swelling. *Indian J Radiol Imaging.* 2014; 24(2): 175-7.
7. Huang CS, Luo CC, Chao HC, Chu SM, Yu YJ, Yen JB. The presentation of asymptomatic palpable movable mass in female inguinal hernia. *Eur J Pediatr.* 2003; 162(7-8): 493-5.
8. Soh E, Sheah K, Ong KO. Hydrocele of the canal of Nuck: Ultrasound and MRI findings. *Rep Med Imaging.* 2011; 4(1): 15-17.
9. Ozel A, Kirdar O, Halefoglu AM, et al. Cysts of the canal of Nuck: Ultrasound and magnetic resonance imaging findings. *J Ultrasound.* 2009; 12(3): 125-7.
10. Yang DM, Kim HC, Lim JW, et al. Sonographic findings of groin masses. *J Ultrasound Med.* 2007; 26(5): 605-14.

Acknowledgements

The author(s) declare that they have no competing interests and financial support.

Access this article online

<http://pediatricurologycasereports.com>

Quick Response Code

