

**PEDIATRIC UROLOGY CASE REPORTS**

ISSN 2148-2969

<http://www.pediatricurologycasereports.com>**Case report: Conservative treatment of renal laceration in a patient with von Willebrand's disease**Durwood Neal,  Omar Hayek*Department of Surgery: Urology, Augusta University, Medical College of Georgia, Augusta, USA***ABSTRACT**

We report a case of blunt renal trauma to a pediatric patient with von Willebrand's disease. The patient was successfully treated via conservative management. Currently, there is no specific guideline regarding the treatment of blunt renal trauma in pediatric patients with clotting disorders, but our case suggests that conservative treatment remains the gold standard.

**Key Words:** Blunt renal trauma, Von Willebrand's disease, conservative management, adolescent.

© 2020 [pediatricurologycasereports.com](http://www.pediatricurologycasereports.com)

✉ *Dr. Durwood Neal*

*Department of Surgery: Urology, Augusta University,  
Medical College of Georgia, Augusta, GA 30912, USA*

*E-mail: [duneal@augusta.edu](mailto:duneal@augusta.edu)*

*Received: 2020-04-28 / Revisions: 2020-05-18*

*Accepted: 2020-06-02*

*Publication Date: 2020-07-01*

**Introduction**

The management of pediatric blunt renal trauma in a child has closely followed that of the adult patient. There is not as much literature in this area, but it most closely parallels the general adult renal trauma publications. Overall, non-operative management remains the gold standard [1]. However, there are often special situations and patients that may not always fit the classic presentations.

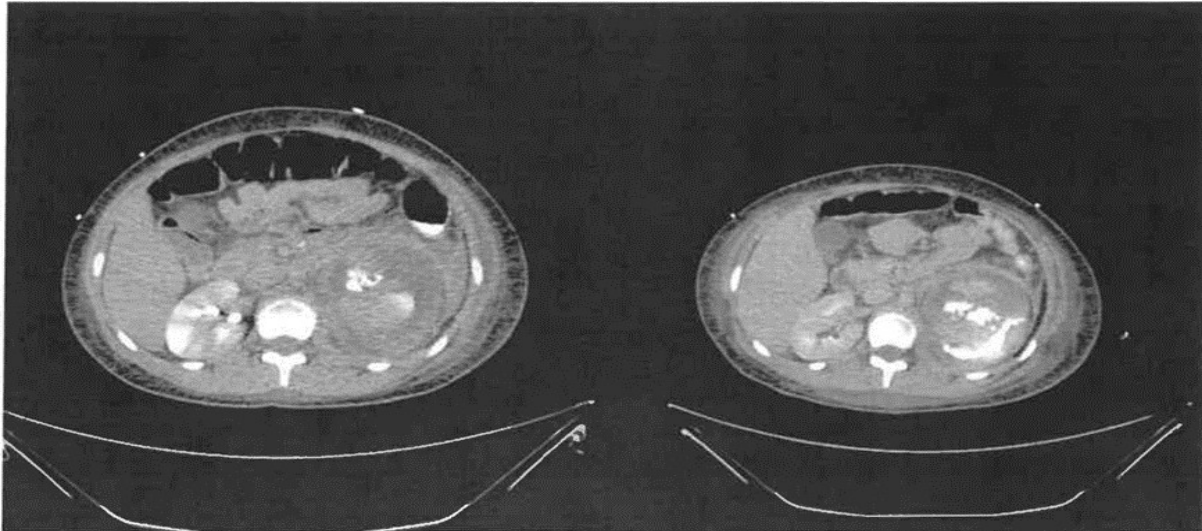
Von Willebrand's Disease (vWD) is the most common hereditary bleeding disorder. It is characterized by a decreased ability of the blood to clot primarily stemming from a

quantitative or qualitative decrease in von Willebrand Factor (vWF), a protein that helps platelets attach to sites of vascular injury and stabilizes factor VIII in the coagulation cascade [2,3]. There are at least three general types and may involve thrombocytopenia.

The current standards for patients with renal trauma focus on conservative management as long the patient is hemodynamically stable. This report describes the conservative management of renal lacerations in a patient with vWD.

**Case report**

An otherwise healthy 14-year-old female was riding an all-terrain vehicle (ATV) going 40 miles per hour when she hit a parked car and was ejected. She landed on her left flank and subsequently complained of left flank pain, left upper quadrant abdominal pain, and left inferolateral chest wall pain. The patient was



**Fig. 1.** Extravasation of contrast from patient's left kidney with subcapsular hematoma.

ambulatory after the accident and was taken home. She continued to complain of pain, had gross hematuria, and vomited several times according to her mother.

The patient's parents initially took her to the emergency room at secondary care hospital two hours after the accident. When it was discovered that the patient had hematuria as well as diagnosis of vWD, she was transferred to our academic, tertiary care hospital. Her vWD is type 1 with mild thrombocytopenia. Clearly this is a milder form of vWD, presenting with menorrhagia and epistaxis upon occasion. This patient did not have a family history of the disorder, so there is a likelihood it was spontaneous mutation. Her vital signs were normal during transport to the hospital as well as on arrival. She had a Glasgow coma score of 15. Physical exam revealed left sided chest tenderness without deformity, left flank tenderness, and abrasions on her left lower back.

Labs drawn on arrival to the emergency room showed hemoglobin of 13.0 g/dL, platelets of 112,000/mm<sup>3</sup>, PT of 12.2 seconds, INR of 1.0, and PTT of 18.1 seconds. Subsequent labs drawn over the next few days showed

hemoglobin levels descending to as low as 7.8 g/dL and PT increasing to as high as 15.2 seconds.

A computed tomography (CT) scan of the abdomen showed two separate lacerations of the left kidney: a grade 3, 2.5cm laceration of the upper pole extending into the superior renal hilum and a grade 4, 3.8cm laceration of the interpolar region extending into the hilum. There was also associated injury to the left renal collecting system with extravasation of contrast. In addition, there was a large subcapsular hematoma.

The attending urologist overseeing the patient's care decided to treat her conservatively. Although the patient did not receive any genitourinary interventions, she did undergo a splenic embolization to control bleeding.

Approximately ten days after being admitted, the patient underwent a left ureteral stent placement with the aim of improving flow from the left kidney to the bladder and reducing pain. She was discharged two days after, and her stent was removed three months after placement. The extravasation was stable by ultrasound. Renal scintigraphy and

computerized axial tomographic scanning showed near complete resolution of the injury. In the twelve months following the injury, no further bleeding occurred.

### **Discussion**

Historically, surgical intervention was considered to be the premier option for renal lacerations, often resulting in nephrectomy [4]. However, recent developments and research in the past few decades have shown that non-surgical, conservative treatments often provide better outcomes, even for grade some grade V parenchymal injuries [5]. A 2005 meta-analysis of 16 published studies found that 90% of the 324 grade IV lacerations included in the analysis could be managed conservatively [3]. Only 12.6% of these patients required delayed surgical intervention, and an even lower percentage (4.6%) required nephrectomy. Additionally, the current guidelines by the American Urological Association (AUA) state that clinicians should use non-invasive treatments in hemodynamically stable patients with renal trauma [6,7].

The patient's prior diagnosis of vWD could have complicated her treatment. Typically, patients with this disease have difficulty forming platelet plugs during the clotting process. This, in turn, makes them more susceptible to continued bleeding and delayed hemostasis upon injury.

However, since the patient remained hemodynamically stable throughout her stay in the hospital, surgical intervention was not indicated as per the AUA guidelines [7]. The patient was placed at bedrest and immobilized for two weeks after discharge and was able to resume normal activities (except ATV riding) one month later.

To date, there are have been no studies or case reports describing the specific treatment of

renal trauma in patients with vWD. Due to the risk of hemorrhage in this patient population, significant care should be taken when managing cases of trauma or laceration. It is crucial to ensure that the patient remains hemodynamically stable and that no additional bleeding develops.

### **Conclusion**

Conservative treatment of renal trauma and lacerations is widely accepted as the most suitable option for most patients. However, patients with vWD or other coagulopathies may often require more focused management due to impaired coagulation homeostasis. Specific guidelines for the treatment of these injuries in the setting of a co-morbid coagulopathy are not available, but conservative management may be safe and effective provided close observation is utilized. Blunt renal trauma in pediatric patients with vWD do not exist, but our case may indicate that conservative treatment remains the gold standard.

### **Compliance with ethical statements**

*Conflicts of Interest:* None.

*Financial disclosure:* None.

*Consent:* Informed and written consent were taken from patient and her parents to publish this case report.

### **ORCID iD of the author (s)**

*Durwood Neal / 0000-0003-0546-3365*

*Omar Hayek / 0000-0003-2308-9231*

### **References**

- [1]Hagedorn JC, Fox N, Ellison JS, et al. Pediatric blunt renal trauma practice management guidelines: Collaboration between the Eastern Association for the

- Surgery of Trauma and the Pediatric Trauma Society. *J Trauma Acute Care Surg.* 2019;86(5):916-25.
- [2]Mikhail S, Kouides P. von Willebrand disease in the pediatric and adolescent population. *J Pediatr Adolesc Gynecol.* 2010;23(6 Suppl):S3-S10.
- [3]Rodeghiero F, Castaman G, Dini E. Epidemiological investigation of the prevalence of von Willebrand's disease. *Blood.* 1987;69(2):454-59.
- [4]Carroll PR, Klosterman PW, McAninch JW. Surgical management of renal trauma: analysis of risk factors, technique, and outcome. *J Trauma.* 1988;28(7):1071-1077.
- [5]Broghammer JA, Fisher MB, Santucci RA. Conservative Management of Renal Trauma: A Review. *Urology.* 2007;70(4):623-29.
- [6]Fernández-Ibieta M. Renal Trauma in Pediatrics: A Current Review. *Urology.* 2018;113:171-78.
- [7]Morey AF, Brandes S, Dugi DD 3rd, et al. Urotrauma: AUA guideline. *J Urol.* 2014;192(2):327-35.