



Cavernous hemangioma of the glans penis: Concomitant surgical excision with circumcision in an uncircumcised patient

Mustafa Yasar Ozdamar, Kursad Zengin, Serhat Tanik, Sebahattin Albayrak, Işın Soyuer

Abstract Hemangiomas are usually superficial, localized, and commonly involve the head or neck, although up to 30% may be seen in the liver. Hemangioma involving the glans penis is extremely rare. A patient with red swelling on the glans penis was admitted for circumcision to our clinic. We performed concomitant surgical excision together with circumcision, and presented the advantages of surgical treatment in such a case.

Key Words Hemangioma; glans penis; circumcision.

© 2014 pediatricurologycasereports.com. All Rights Reserved

From the Department of Pediatric Surgery, Urology, and Pathology

Corresponding Author: Kursad Zengin-Assist Prof,

Bozok University, Medical School, Department of Urology Yozgat, Turkey. Email: kursadzengin@gmail.com

Accepted for publication 3 August 2014

INTRODUCTION

Hemangiomas are the most common benign vascular tumors, resulting from proliferation of immature capillary vessels. This disorder is rarely described in the genital organs [1].

Hemangiomas are classified as capillary, cavernous, arteriovenous, venous, and mixed subtypes. Cavernous and mixed types are the most common [2]. Because it is a rare entity, there is no gold standard treatment modality in genital hemangiomas. Most hemangiomas on penile shaft heal after conservative therapy while some require surgical excision to treat pain and/or cosmetic appearance [3].

In adults, treatment choices of hemangioma in the glans penis are surgical excision, laser therapy, sclerotherapy, electrofulguration, and cryotherapy [4,5].

CASE REPORT

A 9 years old boy with red swelling on the left side of glans penis was admitted to our clinic with the desire of circumcision. His parents had noticed a bright red spot resembling a cherry on glans penis, but instead of regressing, it had gradually increased in size and volume since his babyhood. On physical examination, there was about 7 millimeters of hemangioma on glans penis that was discolored when pressed on (Fig.1). The lesion was totally excised during circumcision under general anesthesia. There was no abnormal scarring or disfigurement at the lesion site on follow up.

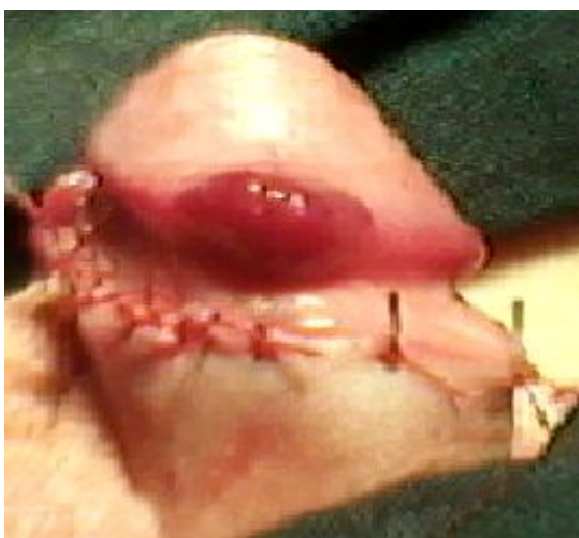

Fig.1.Hemangioma on glans of the penis

In the histopathological examination of the lesion, there were large blood vessels

enclosed within a framework of connective tissue which were consistent with cavernous hemangioma (Fig. 2).

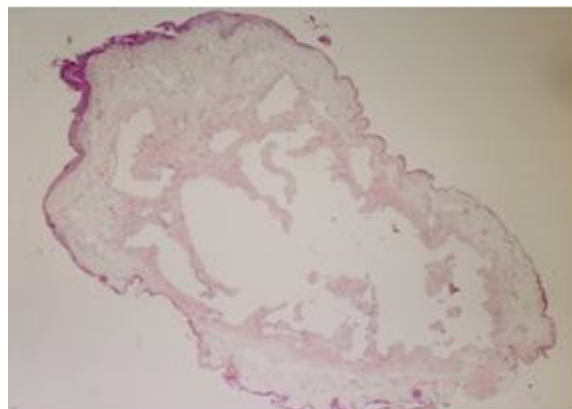


Fig.2. Histopathology of the lesion: large blood vessels enclosed within a framework of connective tissue which are consistent with cavernous hemangioma. HE x80.

DISCUSSION

Hemangiomas are characterized by 3 stages during their life cycle; the proliferating phase (0-1 year of age), the involuting phase (1 to 5 years of age), and the involuted phase (after 5 years of age) [6]. Some hemangiomas do not fully involute and might require treatment once after their final state of involution had finished [7]. Our patient was 9 years old, and hemangioma was noticed by his parents since birth. Total involution of the hemangioma had not observed despite 9 years of time.

All of the vascular lesions on glans penis in childhood including our patient are benign [7]. Treatment depends on the request of patients or their parents. Neodymium laser, sclerotherapy, or surgical excision is the treatment options for those malformations [8]. In contrast to lasers, sclerotherapy is cheaper and readily obtainable. Furthermore, it is re-applicable in case of failure. But, intralesional sclerotherapy can be related to complications such as cutaneous necrosis, ulceration, and hyperpigmentation [9,10]. Intralesional steroid injections of methylprednisolone and triamcinolone/betamethasone were reported to stimulate regression of hemangiomas in the literature, but this treatment option usually requires repeat injections in case of failure at the first time [11].

In a review of pediatric glans malformations, there were 34 vascular malformations in reported 142 cases, up to 2008 [12]. The treatment modalities are similar for pediatric

vascular glans malformations and hemangiomas on the glans penis in the pediatric age group. Since cases of pediatric vascular glans malformations are rare, treatment options are controversial. Therefore, various procedures can be used for treatment of hemangiomas, including surgical excision, laser therapy and sclerotherapy. Each patient should be evaluated individually.

Here we reported concomitant surgical excision of hemangioma with circumcision. The cosmetic results were desirable in the follow-ups. This procedure should be the choice of treatment in regions where circumcision is a religious or traditional necessity. It should be kept in mind that the definitive surgical excision and circumcision of these patients should not be performed until the involuted phase of hemangioma.

CONFLICT OF INTEREST

None declared.

REFERENCES

1. Ulker V, Esen T. Haemangioma of the glans penis treated with Nd:YAG laser. *Int Urol Nephrol.* 2005;37:95–6.
2. Dinehart SM, Kincannon J, Geronemus R. Hemangiomas: evaluation and treatment. *Dermatol Sur.* 2001;27:475–85.
3. Casale AJ, Menashe DS. Massive strawberry hemangioma of the male genitalia. *J Urol.* 1989;141:593-4.
4. Hemal AK, Aron M, Wadhwa SN. Intralesional sclerotherapy in the management of hemangiomas of the glans penis. *J Urol.* 1998;159: 415–7.
5. Angulo JC, Lopez JI, Iriarte I, et al. Angiomadelglande, a proposito de dos observaciones. *Arch Esp Urol.* 1993;46: 47–8.
6. Thorne CH. Vascular anomalies. In: Beasley RW, Aston SJ, Bartlett SP, Gurtner GC, Spear SL (eds). *Grabb and Smith's Plastic Surgery.* 6th ed. New York: Lippincott Williams & Wilkins; 2006. pp. 191-5.
7. Alter GJ, Trengove-Jones G, Horton CE Jr. Hemangioma of penis and scrotum. *Urology* 1993;42:205-8.
8. Yildirim I, Irkilata C, Sumer F, Aydur E, Ozcan A, Dayanc M. Fibroepithelial polyp originating from the glans penis in a child. *Int J Urol.* 2004;11:187-8.
9. Sharma GR. Hemangioma of glans penis. *Internet J Urol.* 2005; 3(1).
10. Savoca G, De Stefani S, Buttazzi L, Gattuccio I, Trambetta C, Belgrano E. Sclerotherapy of hemangioma of the glans penis. *Urology* 2000; 56:153.
11. Mazzola RF. Treatment of hemangiomas in children by intralesional injections of steroids. *Chir Plast.* 1978;4:161-71.
12. Papali AC, Alpert SA, Edmondson JD, et al. A review of pediatric glans malformations: A handy clinical reference. *J Urol.* 2008; 180:1737-4.