

**PEDIATRIC UROLOGY CASE REPORTS**

ISSN 2148-2969

<http://www.pediatricurologycasereports.com>**Congenital imperforate hymen with hydrocolpos and unilateral hydronephrosis in a neonate: A case report****Ali Suat Erkoc***Department of Pediatric Surgery, Metrolife Hospital, Sanliurfa, Turkey***ABSTRACT**

Imperforate hymen is very rare in the neonatal period and may be associated with urinary tract problems, such as urinary retention and hydronephrosis. This report presents a case of a 4-day-old neonate with a marked interlabial swelling causing urinary retention. Radiological imaging studies revealed hydrocolpos, hydrosalpinx, and unilateral hydronephrosis. Her symptoms resolved after hymenectomy.

Key Words: Imperforate hymen; neonate; hydrocolpos; hydronephrosis.

Copyright © 2019 pediatricurologycasereports.com

*Corresponding Author: Dr. Ali Suat Erkoc.
Department of Pediatric Surgery, Metrolife Hospital,
Sanliurfa, Turkey.
E mail: alisuat.erkoc@metrolife.com.tr
ORCID ID: <https://orcid.org/0000-0002-6413-5647>
Received 2018-12-07, Accepted 2018-12-21
Publication Date 2019-01-01*

Introduction

Congenital imperforate hymen is reported in infants with an incidence of approximately 0.1% [1]. In the embryological period, failure of canalization of the vaginal plate results in an imperforate hymen, which causes an accumulation of uterine and vaginal secretions [2]. Imperforate hymen usually presents at puberty with primary amenorrhea, abdominal pain, hematosalpinx, hematocolpos, and hemoperitoneum. In the neonatal period, however, it may present with an abdominal mass, obstructive uropathy, and hydrocolpos, which is difficult to detect [3,4]. In this report,

the case of a 4-day-old neonate who presented with unilateral hydronephrosis and a cystic mass protruding from the introitus, requiring a hymenectomy, is presented.

Case report

A 4-day-old term female neonate was referred with a large interlabial swelling, distention above the umbilicus, urinary retention, and vomiting (Fig. 1). The patient was otherwise in good condition and weighed 2.900 kg. Prenatal ultrasonography (US) examinations showed no anomaly. On admission, a 6F urethral catheter was inserted, and 30 mL of urine was drained (Fig. 2). Renal function tests were normal. US revealed hydrocolpos, hydrosalpinx (Fig. 3), and left grade 2 hydronephrosis. Magnetic resonance imaging (MRI) revealed a large hydrocolpos causing hydronephrosis. Hymenectomy was performed under general

anesthesia, and approximately 100 mL of serous fluid was drained.

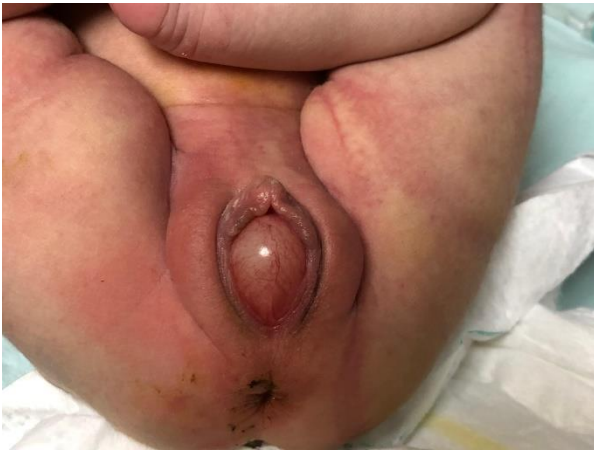

Fig. 1. Imperforate hymen as bulging mass filling the vaginal introitus.

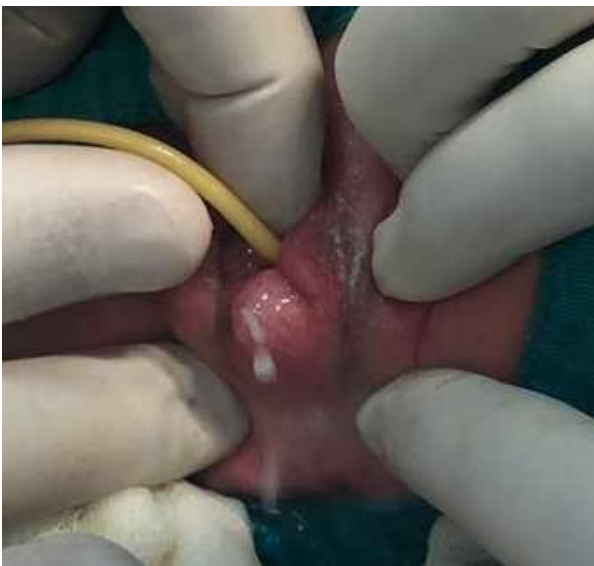

Fig. 2. Appearance of imperforate hymen and urethral foley catheter.

The hymenal orifice was then extended by excising some hymenal tissue (Fig. 4). A 10 French Foley catheter was placed in the vagina, and the balloon was inflated with 1 mL of sterile water to promote patency of the hymen. The balloon remained there for one week. The symptoms resolved, and the child was discharged. Subsequent control US imaging showed normal appearance of the uterus, vagina, and urinary tract.

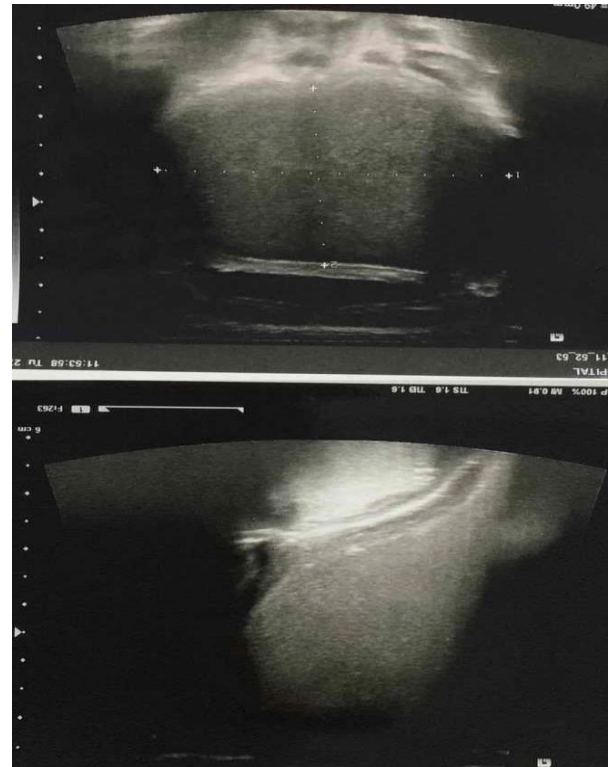


Fig. 3. US scan shows a large hypoechoic mass.

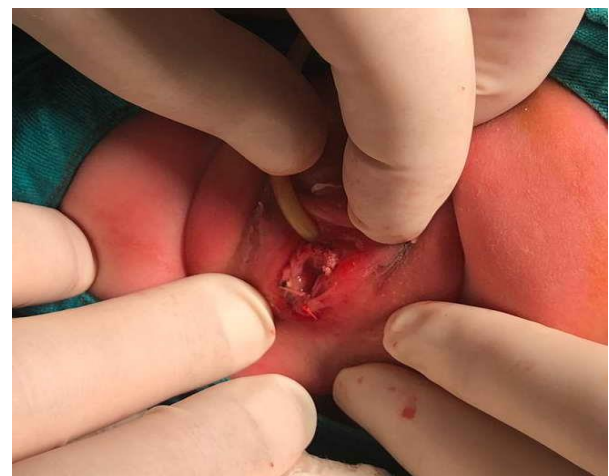

Fig. 4. After operation view of the vagina.

Discussion

Imperforate hymen is due to the failure of canalization of the vaginal plate during the eighth week of pregnancy and usually occurs as an isolated abnormality [5]. However, it may also coexist with other malformations, such as imperforate anus, bifid clitoris, and polycystic kidney [5]. Imperforate hymen usually remains asymptomatic until puberty,

but there may be a significant accumulation of cervicovaginal secretions with the effect of circulating estrogens in the fetal period [6]. In this instance, it may present as hydrocolpos or mucocolpos associated with a large interlabial swelling [6]. Neonatal hydrocolpos may cause hydronephrosis and acute renal failure due to obstructive uropathy [2,4,7].

Treatment of hydrometrocolpos caused by imperforate hymen is hymenotomy with different methods, such as simple linear, cruciate, plus hymenotomy, or resection of the membrane. Additionally, in the postoperative period, a catheter can be placed for several days or weeks [1-8].

In this case, the newborn presented with interlabial swelling, distention above the umbilicus, urinary retention, and vomiting. In addition, US examination showed grade 2 hydronephrosis in the left kidney. After hymenectomy, the patient's symptoms, including urinary, resolved. Therefore, hydrocolpos due to imperforate hymen may be the cause of hydronephrosis. It is thought that rapid diagnosis and treatment are important steps.

Compliance with ethical statements

Conflicts of Interest: None.

Financial disclosure: None.

Consent: All photos were taken with parental consent.

References

- [1]Kahn R, Duncan B, Bowes W. Spontaneous opening of congenital imperforate hymen. *J Pediatr.* 1975;87(5):768-70.
- [2]Ozturk H, Yazici B, Kucuk A, Senses DA. Congenital imperforate hymen with

bilateral hydronephrosis, polydactyly and laryngocele: A rare neonatal presentation. *Fetal Pediatr Pathol.* 2010;29(2):89-94.

- [3]Shen MC, Yang LY. Imperforate hymen complicated with pyocolpos and lobar nephronia. *J Chin Med Assoc.* 2006;69(5):224-27.
- [4]Loscalzo IL, Catapano M, Loscalzo J, Sama A. Imperforate hymen with bilateral hydronephrosis: an unusual emergency department diagnosis. *J Emerg Med.* 1995;13(3):337-39.
- [5]Vitale V, Cigliano B, Vallone G. Imperforate hymen causing congenital hydrometrocolpos. *J Ultrasound.* 2013;16(1):37-39.
- [6]Tseng JJ, Ho JY, Chen WH, Chou MM. Prenatal diagnosis of isolated fetal hydrocolpos secondary to congenital imperforate hymen. *J Chin Med Assoc.* 2008;71(6):325-28.
- [7]Aygün C, Ozkaya O, Ayyıldız S, Gungör O, Mutlu B, Kuçukoduk S. An unusual cause of acute renal failure in a newborn: hydrometrocolpos. *Pediatr Nephrol.* 2006;21(4):572-73.
- [8]Rabani SM. A rare non urologic cause for urinary retention; report of 2 cases. *Nephrourol Mon.* 2013;5(2):766-68.

Access this article online

<http://pediatricurologycasereports.com>

Quick Response Code

