



Differentiation of adrenal hemorrhage from adrenal malignancies in a neonatal case by superb microvascular imaging

Fatih Ates¹, Halil Ibrahim Sara², Mehmet Sedat Durmaz¹

¹Department of Radiology, Selcuk University, Medical Faculty, Konya, Turkey

²Department of Radiology, University of Health Sciences, Dr. Abdurrahman Yurtaslan, Ankara Oncology Training and Research Hospital, Konya, Turkey

ABSTRACT

Neonatal adrenal hemorrhages (NAH) may be encountered in cases of perinatal asphyxia. The differentiation of malignant lesions and bleeding in the adrenal gland detected in the neonatal period is very important for treatment and prognosis. Ultrasonography (US) is the first preferred imaging method in NAH because it is non-invasive and easy to apply. Vascularization is not detected in hematomas in Doppler US examination. However, conventional Doppler imaging techniques (CDIT) may not adequately show the blood flow (BF) of the lesions. Super micro-vascular imaging (SMI) is a new vascularization imaging technique that eliminates motion artifacts, provides detailed information about very slow blood flow, and allows imaging of microvascular structures. SMI can be operated in 2 modes: color SMI (cSMI) and monochrome SMI (mSMI). The cSMI mode simultaneously displays a conventional grayscale US with color-coded Doppler signals. The monochrome SMI mode improves the visibility of vascular structures by eliminating background signals and focusing only on vasculature signals. In this case report, we aimed to present a case of NAH detected by SMI in the neonatal period and we wanted to emphasize the usefulness of SMI.

Key Words: Adrenal gland disease, hemorrhage, newborn, ultrasonography, superb microvascular imaging, Doppler.

✉ Dr. Fatih Ates

Department of Radiology, Selcuk University, Medical Faculty, Konya, Turkey.

E-mail: fatih_ates81@hotmail.com

Received: 2020-09-29 / Revisions: 2020-11-28

Accepted: 2020-12-09 / Publication Date: 2021-01-01

Introduction

The widespread use of ultrasonography (US) in the neonatal period has increased the diagnosis of adrenal gland lesions [1]. However, the differential diagnosis of adrenal lesions during antenatal period may not be definite in most cases. Differential diagnosis of these region

lesions usually includes neonatal adrenal hemorrhage (NAH), neuroblastoma, adrenal and renal cortical cysts, mesoblastic nephroma, bronchogenic cyst, renoureteral duplication and extralobular pulmonary sequestrations [2]. Additionally, adrenal tumors and hemorrhage are also frequently encountered in Beckwith-Wiedemann syndrome [3]. US is the first preferred imaging method in the evaluation of fetal and neonatal adrenal masses, because it is noninvasive and easily applicable. Sonographic appearance of the mass, arterial blood supply, and additional examination and imaging

methods in the postpartum period are used in the differential diagnosis [4]. NAH may appear as a mass above the fetal kidneys and will show features ranging from hyperechoic to isoechoic and hypoechoic and eventually an anechoic cystic appearance with or without septation [5]. Color Doppler (CD) and power Doppler (PD) US will not show any intrinsic vascularity in bleeding. Therefore, conventional Doppler imaging techniques (CDIT) may be insufficient to show microvascular structures and low velocity blood flow in tissues [6-9]. Super micro-vascular imaging (SMI) is a new vascular imaging technique that allows access to microvascular structures and low velocity blood flow and to eliminate motion artifacts. SMI can be operated in 2 modes: color SMI (cSMI) and monochrome SMI (mSMI). The cSMI mode simultaneously displays a conventional grayscale US with color-coded Doppler signals. The monochrome SMI mode improves the visibility of vascular structures by eliminating the background signals and focusing only on the vasculature signals [10,11]. In this case, we aimed to differentiate neonatal NAD from adrenal tumors with cSMI and mSMI features.

Case report

35-week gravida 2 parity 1 pregnant mother was taken to emergency cesarean operation due to the decrease in heart rate and fetal distress findings while normal spontaneous vaginal delivery was planned. There was meconium contamination on the baby's skin at birth and the baby's weight was 2400 grams. In the follow-up blood analysis, a decrease of 2.3 units was found in the hemoglobin value. Abdominal and transfontanelle US examinations were performed on the newborn. No intracranial bleeding was observed in transfontanelle US scan. In the abdominal US

examination, anechoic cystic appearances were observed in the right adrenal gland. The patient was transferred to the neonatal intensive care unit of our hospital for the differentiation and clinical follow-up of adrenal carcinoma and NAH. After obtaining the patient's history presented above, an abdominal US examination was performed. There was an increase in the size of the adrenal gland and it measured 24x14 mm in diameter. (Fig. 1).

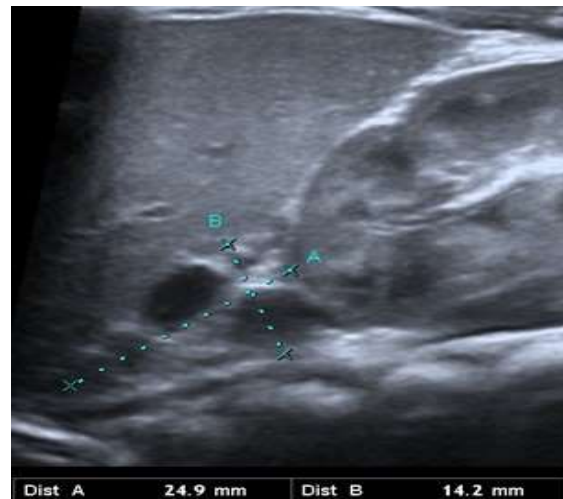

Fig. 1. Increase in the right adrenal gland size. Anechoic lesions are seen with diameters of 9 mm and 8 mm. The size of the adrenal gland 24.9x14.2 mm in diameter.

In the adrenal gland, 9 mm and 8 mm diameters of anechoic cystic lesions were detected. SMI function was activated in Canon Aplio 500 (Canon Medical System Corporation, Tokyo, Japan) US device for vascularization examination of lesions. US, cSMI and mSMI vascular examinations were performed by an experienced radiologist who worked for 15 years in the US and four years in cSMI. Images of the adrenal gland during the cSMI examination were provided by the US probe contacting the gel-coated skin. The cSMI vascular examination was performed in a magnified view for 5 seconds and then the

image was frozen. Later, the vascularizations were evaluated with the cSMI and mSMI. Vascular signal could not be obtained from the anechoic lesions (Fig. 2). The diagnosis of the patient was reported as NAH by evaluating the history, clinical and radiological findings together. On imaging follow-up of the patient, it was observed that the size of the lesion decreased and then disappeared completely. In addition, NAH was confirmed by magnetic resonance imaging (MRI).

ultrasonographic appearance of NAH depends on the age of the hematoma and this gradually improves with age. But the sonographic appearance of NAH may appear as an echogenic adrenal mass and may be difficult to distinguish from congenital neuroblastoma. Since neonatal neuroblastoma can have a cystic appearance and may be present as a solid adrenal mass in NAH, sonographic distinction of these two pathologies can be very difficult. [13]. Serial sonographic follow-up of a NAH

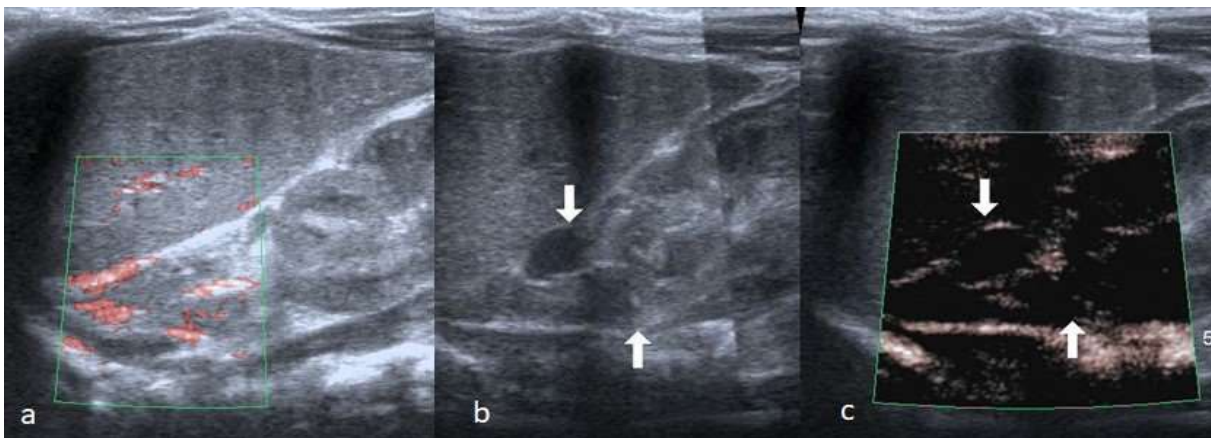


Fig. 2. In CSMI (a) and mSMI (c) examination; as indicated by arrows (b, c), vascularization was not observed in the anechoic lesions. In the follow-up, the lesions decreased in size and then disappeared completely.

Discussion

The most common predisposing causes of NAH are; birth trauma, prolonged labor, intrauterine infection, perinatal asphyxia or hypoxia, increased birth weight, septicemia, hemorrhagic disorder and hypothermia [12]. Our case also had meconium contamination and a diagnosis of NAH was made as a result of hypoxia secondary to meconium aspiration.

Differential diagnosis of NAH should be made by neonatal neuroblastoma, adrenal abscess, cystic neuroblastoma, cortical renal cyst and obstructed upper cortical renal cyst and an obstructed upper drainage pathway in duplicated kidney [2,3,5,12]. The

will show cystic transformation, gradual reduction in size and eventually an echogenic appearance before the mass disappears and calcification occurs. If there is no reduction in mass size, an underlying neuroblastoma should be considered [14]. In addition, bleeding in congenital neuroblastoma can make the distinction between NAH and neuroblastoma extremely difficult [15,16].

US is the first choice imaging method in children, especially in neonatal period. Acute bleeding appears as a predominantly hyperechogenic mass with mixed echoic structure due to blood clots within the hematoma. In the later stages, the mass gradually becomes liquid and then becomes

hypo-anechoic due to the lysis of clots. NAH does not show vascularization in CD and PD. [17,18]. However, although CDIT provides valuable data for evaluating blood flow, it does not disclose fine vessels and low velocity blood flow data. But; It is difficult to provide immobility and relaxation in babies during the neonatal period. Therefore, CDIT is associated with data loss due to motion artifacts. There are studies in the literature reporting that CDIT has important limitations in the evaluation of vascularization especially in children and neonatal period [7,9,10,19,20]. PD can provide more vascular data compared to CD. However, in the literature, PD is insufficient to show vascularity in young children [7].

SMI is a powerful and intelligent algorithm that effectively separates flow signals from overlaying tissue motion artifacts, preserving even the subtlest low-flow components with unmatched detail and definition [10,21,22]. Therefore, SMI effectively uses a new adaptive algorithm to analyze motion artifacts, separate flow signals from overlapping tissue motion artifacts, remove tissue motion, and reveal true blood flow. By achieving this goal, SMI can visualize both high speed and low speed flows. This imaging technique preserves even the smallest low-flow components with unmatched detail and definition [10]. In the literature, there are studies in which this technique is used for breast, testicular, thyroid and focal liver lesions and its effectiveness has been shown [6,7,9,20,21,23].

Detection of blood flow in lesions with suspected malignancy is very important in terms of differentiation between malignancy and hematoma. In these cases, the most common examination is US because it is an easily applicable and non-invasive imaging method. The malignancy is considered primarily in the cases which show

vascularization. This imaging is especially important in childhood [7,9]. In addition, US is preferred as the first-line imaging method because it is difficult for children to adapt to computed tomography (CT) or MRI and requires anesthesia. This is true for adrenal lesions. Since vascularization is not seen in NAHs, CDITs may be insufficient to show vascularization. Since adaptation to cross-sectional imaging methods in young children is difficult and troublesome, SMI becomes even more important in these case. mSMI is statistically superior to cSMI. SMI, especially mSMI mode, should be a part of vascular examinations, especially in pediatric patients because of its superiority to other vascularization imaging techniques [7].

As a result; the distinction between adrenal malignant lesions and hematoma is crucial as it will change the treatment. SMI can be routinely applied because it is non-invasive, easy to apply, does not require sedation and is more effective than other CDITs.

Compliance with ethical statements

Conflicts of Interest: None.

Financial disclosure: None.

Consent: Patient confidentiality has been maintained and written consent has been obtained from the patient's parents for the publication of patient information and clinical pictures and can be provided as required.

ORCID iD of the author (s)

Fatih Ates / 0000-0002-2693-4616

Halil Ibrahim Sara / 0000-0001-9075-9237

Mehmet Sedat Durmaz / 0000-0002-1340-2477

Copyrights: © 2021@ author (s).

This is an open access article distributed under the terms of the [Creative Commons Attribution License \(CC BY 4.0\)](https://creativecommons.org/licenses/by/4.0/), which permits

unrestricted use, distribution, and reproduction in any medium, provided the original author(s) and source are credited and that the original publication in this journal is cited, in accordance with accepted academic practice. No use, distribution or reproduction is permitted which does not comply with these terms.

References

- [1]Schrauder MG, Hammersen G, Siemer J, et al. Fetal adrenal haemorrhage--two-dimensional and three-dimensional imaging. *Fetal Diagn Ther.* 2008;23(1):72-75.
- [2]Harrington JL, Farley DR, van Heerden JA, et al. Adrenal tumors and pregnancy. *World J Surg.* 1999;23(2):182-86.
- [3]Merrot T, Walz J, Anastasescu R, et al. Prenatally detected cystic adrenal mass associated with Beckwith-Wiedemann syndrome. *Fetal Diagn Ther.* 2004;19(6):465-69.
- [4]Hsieh CC, Chao AS, Hsu JJ et-al. Real-time and power Doppler imaging of fetal adrenal hemorrhage. *Chang Gung Med J.* 2005;28(12): 860-65.
- [5]Vollersen E, Hof M, Gembruch U. Prenatal sonographic diagnosis of fetal adrenal gland hemorrhage. *Fetal Diagn Ther.* 1996;11 (4): 286-91.
- [6]Durmaz MS, Akyürek N, Kara T, et al. Quantitative Assessment of Thyroid Gland Vascularization With Vascularization Index Using Color Superb Microvascular Imaging in Pediatric Patients With Hashimoto Thyroiditis. *Ultrasound Q.* 2019;35(3):281-289.
- [7]Durmaz MS, Sivri M. Comparison of superb micro-vascular imaging (SMI) and conventional Doppler imaging techniques for evaluating testicular blood flow. *J Med Ultrason.* 2001;2018;45(3):443-52.
- [8]Arslan S, Karahan AY, Oncu F, et al. Diagnostic Performance of Superb Microvascular Imaging and Other Sonographic Modalities in the Assessment of Lateral Epicondylitis. *J Ultrasound Med.* 2018;37(3):585-93.
- [9]Kara T, Sara HI, Coban MS et al. Diagnostic Value of Superb Microvascular Imaging in Testicular Torsion-A Case Report. *Arch of Pediatr and Neonatol.* 2018;1(2); 14-17.
- [10]Hata J. Toshiba Medical Systems Corporation; 2014. Seeing the unseen new techniques in vascular imaging; superb micro-vascular imaging. Available at: <http://www.toshibamedicalsystems.com/library/us/index.html>. Accessed November 29, 2017.
- [11]Machado P, Forsberg F. Toshiba Medical Systems Corporation; 2014. Initial experience with a novel microvascular flow imaging technique. Medical review. Available at: <http://www.toshibamedicalsystems.com/library/us/index.html>. Accessed November 29, 2017.
- [12]Mutlu M, Karagüzel G, Aslan Y, et al. Adrenal hemorrhage in newborns: a retrospective study. *World J Pediatr.* 2011;7(4):355-57.
- [13]Deeg KH, Bettendorf U, Hofmann V. Differential diagnosis of neonatal adrenal haemorrhage and congenital neuroblastoma by colour coded Doppler sonography and power Doppler sonography. *Eur J Pediatr.* 1998;157(4):294-97.
- [14]oti MS, Ghirri P, Bartoli A, Caputo C, Laudani E, Masoni F, Mele L, Bernardini R. Adrenal hemorrhage in newborn: how, when and why- from case report to literature review. *Ital J Pediatr.* 2019 8;45(1):58.
- [15]Eklöf O, Mortensson W, Sandstedt B. Suprarenal haematoma versus

- neuroblastoma complicated by haemorrhage. A diagnostic dilemma in the newborn. *Acta Radiol Diagn (Stockh)*. 1986;27(1):3-10.
- [16] Murthy TV, Irving IM, Lister J. Massive adrenal hemorrhage in neonatal neuroblastoma. *J Pediatr Surg*. 1978;13(1):31-34.
- [17] Albano D, Agnello F, Midiri F, et al. Imaging features of adrenal masses. *Insights Imaging*. 2019;10(1):1.
- [18] Jordan E, Poder L, Courtier J, et al. Imaging of nontraumatic adrenal hemorrhage. *AJR Am J Roentgenol*. 2012;199(1):W91-98.
- [19] Dogra VS, Rubens DJ, Gottlieb RH, et al. Torsion and beyond: new twists in spectral Doppler evaluation of the scrotum. *J Ultrasound Med*. 2004;23(8):1077-85.
- [20] Karaca L, Oral A, Kantarci M, et al. Comparison of the superb microvascular imaging technique and the color Doppler techniques for evaluating children's testicular blood flow. *Eur Rev Med Pharmacol Sci*. 2016;20(10):1947-53.
- [21] Wu L, Yen HH, Soon MS. Spoke-wheel sign of focal nodular hyperplasia revealed by superb micro-vascular ultrasound imaging. *QJM*. 2015;108(8):669-70.
- [22] Zhan J, Diao XH, Jin JM, et al. Superb Microvascular Imaging-A new vascular detecting ultrasonographic technique for avascular breast masses: A preliminary study. *Eur J Radiol*. 2016;85(5):915-21.
- [23] Ma Y, Li G, Li J, et al. The Diagnostic Value of Superb Microvascular Imaging (SMI) in Detecting Blood Flow Signals of Breast Lesions: A Preliminary Study Comparing SMI to Color Doppler Flow Imaging. *Medicine (Baltimore)*. 2015;94(36):e1502.