

**PEDIATRIC UROLOGY CASE REPORTS**

ISSN 2148-2969

<http://www.pediatricurologycasereports.com>**Donated staghorn kidney stone in an HIV positive pediatric kidney transplant recipient****Babalwa Nondela<sup>1</sup>, John Lazarus<sup>1</sup>, Justin Howlett<sup>1</sup>, Mignon McCulloch<sup>2</sup>, Peter Nourse<sup>2</sup>, Glenda Moonsamy<sup>3</sup>, Cecil Levy<sup>3</sup>**<sup>1</sup>*Division of Pediatric Urology, Red Cross War Memorial Children's Hospital, University of Cape Town, South Africa*<sup>2</sup>*Division of Pediatric Nephrology, Red Cross War Memorial Children's Hospital, University of Cape Town, South Africa*<sup>3</sup>*Division of Pediatric Nephrology, Department of Pediatrics and Child Health, Charlotte Maxeke Johannesburg Academic Hospital and the University of the Witwatersrand, Johannesburg, South Africa***ABSTRACT**

We report on a case of a pediatric recipient with a well-managed HIV associated nephropathy (HIVAN) on highly active anti-retroviral therapy who underwent a successful deceased donor kidney transplantation, and was unexpectedly found to have a donated staghorn stone. Safe and effective management of the donated stone with combined Percutaneous Nephrolithotomy and Extra-Corporeal Shock Wave Lithotripsy to salvage the solitary allograft is discussed. To our knowledge this case is the first reported pediatric kidney transplant for HIVAN with a donated staghorn kidney stone in the English literature.

**Key Words:** Donated stone; kidney transplant; HIV positive.

*Copyright © 2017 pediatricurologycasereports.com*

**Corresponding Author:** Dr. Babalwa Nondela, MBChB, Division of Pediatric Surgery, Red Cross War Memorial Children's Hospital, 6th floor, ICH Building, Klipfontein Road, Rondebosch, Cape Town, South Africa

Email: [bbnondela@gmail.com](mailto:bbnondela@gmail.com)

Accepted for publication: 12 May 2017

**Introduction**

All children with end stage kidney disease warrant evaluation for kidney transplantation to improve quality of life, overall cost of treatment and most importantly survival rate. Historically, the presence of end stage kidney disease (ESKD) in a child with HIV was

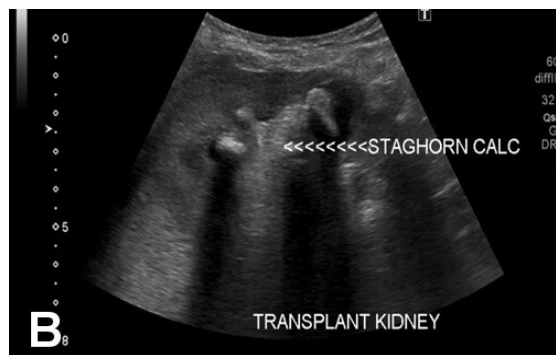
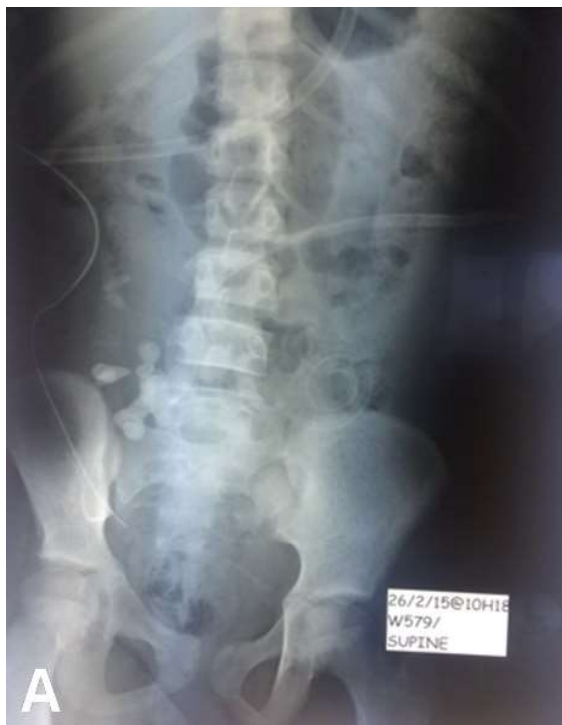considered as an absolute contra-indication to kidney transplantation, and so was the donor with kidney stone. Recent results with solid organ transplantation in highly selected HIV-infected patients have been favorable, yielding short-term results similar to those in uninfected people. Recent recommendations, with evidence from the adult literature suggest that HIV associated nephropathy (HIVAN) and donated stones be considered for transplantation. We report on a case of a pediatric recipient with a well-managed HIVAN on highly active anti-retroviral therapy (HAART) who underwent a successful

deceased donor kidney transplantation, and was unexpectedly found to have a donated staghorn stone.

### Case report

We present the case of a perinatal HIV infected 14 year old girl. She was referred from another institution having being on HAART (Abacavir, Lamivudine and Efavirenz) for 2 years. Despite good virological control she presented in end stage kidney disease. A diagnosis of HIVAN was confirmed on kidney biopsy. She received a deceased donor kidney transplant in 2015. Post-operative imaging [Fig. 1A,B] revealed a staghorn stone in the allograft which had been undiagnosed in the donor prior to transplantation.

This was initially managed conservatively but due to persistent urinary tract infections and loss of graft function she was referred to our institution, Red Cross War Memorial Children's Hospital, Cape Town, South Africa for further management.

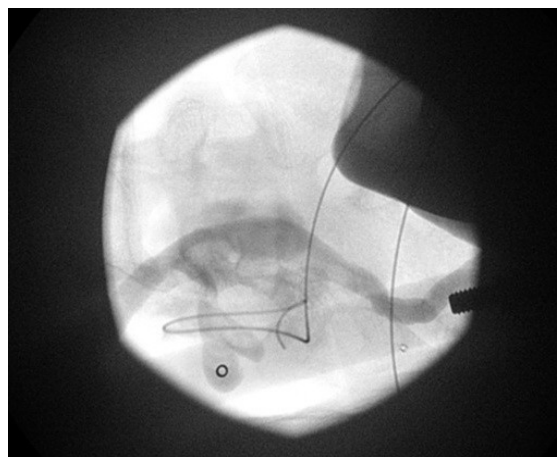


**Fig. 1.** Plain abdominal x-ray (A) and KUB ultrasound (B) taken post right kidney transplantation demonstrating a staghorn stone in the right allograft.

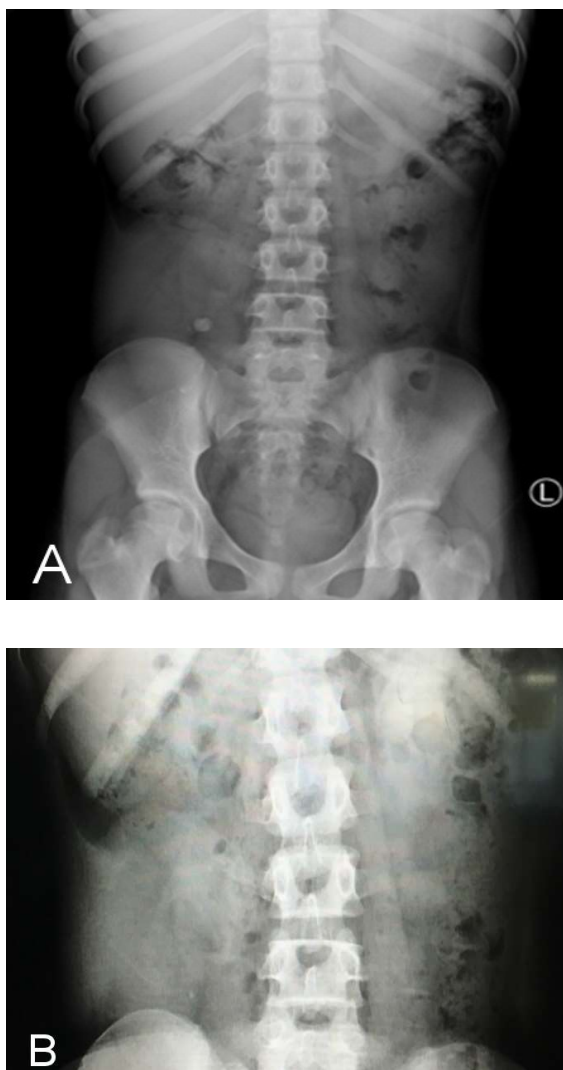
We performed a kidney biopsy that showed chronic drug toxicity, borderline acute rejection changes, chronic active pyelonephritis and obstruction.

The staghorn stone was managed by Percutaneous Nephrolithotomy (PCNL) [Fig. 2] followed by interval Extra-Corporeal Shock Wave Lithotripsy (ESWL) with good results [Fig. 3A]. Post therapy only an insignificant stone fragment remained [Fig. 3B].

Currently she is clinically well with good kidney function and no urinary infections since surgical management of her stone.



**Fig. 2.** Fluroscopy image demonstrating Percutaneous Nephrolithotomy (PCNL) using the bull's eye technique.



**Fig. 3.** Plain abdominal radiograph demonstrating the remaining stone fragment (A) post PCNL and (B) after Extracorporeal shock wave lithotripsy (ESWL).

### Discussion

Kidney transplantation in children remains the gold standard for treatment of children with end stage kidney disease (ESKD) [1]. It has proven advantages over dialysis such as better quality of life, less cost and higher survival rate [2]. ESKD is a chronic disease affecting between 5-10 children per million each year [3]. Since the conception of successful kidney transplantation by Joseph Murray and

colleagues in 1954 with the identical twins in Boston, kidney transplantation has saved many lives and the indications have been evolving. The survival of kidney allografts have improved tremendously over time in successive cohorts of pediatric recipients, regardless of whether the transplant was from a living or a deceased donor [4]. The indications for kidney transplantation are any child with ESKD with no absolute contraindication. There are few contraindications to kidney transplantation solely on the basis of the cause of ESKD. Historically, HIV has been considered as contra-indication to kidney transplantation because of the potential impact of immunosuppressive therapy on the risk of opportunistic infections and post-transplant neoplasia [5]. The current recommendation is to consider transplantation once the HIV infection is controlled and the viral load undetectable. HIV-infected patients with ESKD may be considered for kidney transplantation if they demonstrate adherence to a highly active anti-retroviral therapy (HAART) regimen, undetectable (< 50 copies/mL) HIV viral load for > 3 months, CD4 lymphocyte count > 200/mL for > 6 months, no opportunistic infections, and usual kidney transplantation eligibility criteria are met [3,6].

Recent results with solid organ transplantation in highly selected HIV-infected patients have been favorable, yielding short-term results similar to those in uninfected people, hence the reconsideration and recommendation of organ transplants in HIV-infected children [7-12]. The rising incidence of HIVAN related ESKD has stimulated initiation of HIV positive deceased donors to HIV positive recipients transplantation with promising results [6].

We report on a recipient with a well-managed HIV associated nephropathy who was

compliant on HAART. A search of the English literature reveals a slow but increasing trend in HIVAN kidney transplantation [12,13].

The presence of a kidney stone in the donor kidney has also been considered a relative contraindication to donation in the past [4,14,15]. The challenge of limited kidney donors to meet the growing demand for organs has contributed to the development of “extended criteria” whereby donors that were not initially considered for donation are now being considered [4]. The incidence of urological abnormalities without a prior history is extremely rare [16,17], thus routine urological assessment is not warranted. For those with a urological history, an evaluation by a urologist should probably be mandatory. On pre-transplantation evaluation of a living donor it is common practice to image the kidneys in evaluation of the anatomy and presence of stone. However, it poses a controversial challenge in a deceased donor to include the assessment for the presence of a probable asymptomatic stone during a crucial time constrained period pre-transplant. Also, the reported series are small with extremely low incidence 0.37% [18] of donor kidney stone. Therefore, the cost-effectiveness of routine preoperative imaging cannot be assessed.

One of the known urological complications post kidney transplantation is stone formation with an incidence of 0.9% [14]. Although cohorts report that the incidence of urinary stone disease appears to be the same in transplant recipients as in the general population [14,18-20]. Staghorn stones, as in our case, are challenging stones. Donor staghorn stones in an HIV positive child on immunosuppressive therapy are even more challenging. The kidney stone may present early and result in significant morbidity e.g.

urinary tract obstruction, UTI and even loss of renal function, as seen in our case, and therefore active management is of paramount importance for allograft salvage.

The management of the kidney stone in the kidney allograft depends on the size of the stone and whether it is symptomatic or not. Observation by means of close monitoring has been considered for small, asymptomatic stones [15], however it poses the risk of missing a silent hydronephrosis with resultant unsuspected or undetected deterioration in kidney function [21]. Surgical management options are bench ex vivo ureteroscopy [15] immediately after harvesting or in vivo after transplantation, although there is not enough evidence to support its use [21]. ESWL and PCNL are more reliable, reproducible and safe options for kidney allograft stones with reported success rates of 90% to 100% when combined together [14,21,22]. This therapy was also successful in our case with near complete resolution of the donated kidney stone. PCNL is a difficult procedure in children but an effective minimally invasive alternative to open surgery.

This child has been well with no recurrence of UTI and, going forward, she will have her routine clinical and renal function follow up as well as radiological surveillance every 6-12 months with ultrasound imaging to monitor the upper renal tracts.

### Acknowledgements

The author(s) declare that they have no competing interest and financial support.

### References

- [1] McEnery PT, Stablein DM, Arbus G, Tejani A. Renal transplantation in children. A report of the North American Pediatric

- Renal Transplant Cooperative Study. *N Engl J Med.* 1992;326(26):1727-32.
- [2] Knoll G, Cockfield S, Blydt-Hansen T, et al. Kidney Transplant Working Group of the Canadian Society of Transplantation.. Canadian Society of Transplantation: consensus guidelines on eligibility for kidney transplantation. *CMAJ.* 2005;173(10):S1-25.
- [3] Van Arendonk KJ, Boyarsky BJ, Orandi BJ, et al. National trends over 25 years in pediatric kidney transplant outcomes. *Pediatrics.* 2014;133(4):594-601.
- [4] Dharnidharka VR, Fiorina P, Harmon WE. Kidney transplantation in children. *N Engl J Med.* 2014;371(6):549-58.
- [5] Spital A. Should all human immunodeficiency virus-infected patients with end-stage renal disease be excluded from transplantation? The views of U.S. transplant centers. *Transplantation.* 1998;65(9):1187-91.
- [6] Muller E, Kahn D, Mendelson M. Renal transplantation between HIV-positive donors and recipients. *N Engl J Med.* *N Engl J Med.* *N Engl J Med.* 2010;362(24):2336-7.
- [7] Ahuja TS, Zingman B, Glicklich D. Long-term survival in an HIV-infected renal transplant recipient. *Am J Nephrol.* 1997;17(5):480-2.
- [8] Purgus R, Tamalet C, Poignard P, et al. Long-term nonprogressive human immunodeficiency virus-1 infection in a kidney allograft recipient. *Transplantation.* 1998; 66(10):1384-6.
- [9] Stock PG, Roland ME, Carlson L, et al. Kidney and liver transplantation in human immunodeficiency virus-infected patients: a pilot safety and efficacy study. *Transplantation.* 2003;76(2):370-5.
- [10] Roland ME, Stock PG. Review of solid-organ transplantation in HIV-infected patients. *Transplantation.* 2003;75(4):425-9.
- [11] Gow PJ, Pillay D, Mutimer D. Solid organ transplantation in patients with HIV infection. *Transplantation.* 2001;72(2):177-81.
- [12] McCulloch MI, Kala UK. Renal transplantation in human immunodeficiency virus (HIV)-positive children. *Pediatric Nephrology.* 2015;30(4):541-8.
- [13] Shroff RC, McCulloch M, Novelli V, et al. Successful outcome of renal transplantation in a child with HIV-associated nephropathy. *Arch Dis Child.* 2014;99(11):1026-8.
- [14] El-Mekresh M, Osman Y, Ali-El-Dein B, El-Diasty T, Ghoneim MA. Urological complications after living-donor renal transplantation. *BJU international.* 2001;87(4):295-306
- [15] Lafranca JA, Durmaz SF, Ivanovski O, et al. Donors with stone-bearing kidneys are eligible for living kidney donation: A systematic review and cohort analysis. Shifting paradigms in live kidney donation and transplantation. 2015 Nov 1:169.
- [16] Shandera KC, Rozanski TA, Jaffers G. The necessity of voiding cystourethrogram in the pre transplant urologic evaluation. *Urology.* 1996;47(2):198-200.
- [17] Glazier DB, Whang MI, Geffner SR, et al. Evaluation of voiding cystourethrography prior to renal transplantation. *Transplantation.* 1996;62(12):1762-5.
- [18] Rhee BK, Bretan PN JR, Stoller ML. Urolithiasis in renal and combined pancreas/renal transplant recipient. *J Urol.* 1999;161(5):1458-62.
- [19] Hayes JM, Streem SB, Graneto D, Hodge EE, Steinmuller DR, Novick AC. Renal transplant calculi. A reevaluation of risks



- and management. Transplantation. 1989;47(6):949-52.
- [20] Harper JM, Samuell CT, Hallson PC, Wood SM, Mansell MA. Risk factors for calculus formation in patients with renal transplants. *Br J Urol*. 1994;74(2):147-50.
- [21] Lu HF, Shekarriz B, Stoller ML. Donor-gifted allograft urolithiasis/ early percutaneous management. *Urology*. 2002;59(1):25-7.
- [22] Trivedi A, Patel S, Devra A, Rizvi J, Goel R, Modi P. Management of calculi in a donor kidney. *Transplant Proc*. 2007;39(3):761-2.

Access this article online

<http://pediatricurologycasereports.com>

Quick Response Code

