



PEDIATRIC UROLOGY CASE REPORTS

ISSN 2148-2969

Journal homepage: <http://www.pediatricurologycasereports.com>

Forgotten DJ stents with calculi in a double moiety re-implant:

A case report

Apoorva Achyut Kulkarni, Paras Kothari, Abhaya Gupta, Vishesh Dikshit

Pediatric Surgery, LTMGH, India

ABSTRACT

Calculi occurring around double J (DJ) stents is a rare occurrence. Our case was of a 12-year-old female who was operated for ureteric re-implantation of both moieties in a case of left sided double moiety with Grade IV VUR. Two DJ stents were kept in situ and patient was lost to follow-up. The stents and resultant calculi came into notice when she came with abdominal pain and dysuria. They were removed by pyelolithotomy with suprapubic cystolithotomy.

Key Words: DJ stent; calculi; pyelolithotomy; cystolithotomy.

Copyright © 2017 pediatricurologycasereports.com

*Corresponding Author Dr. Apoorva Achyut Kulkarni,
LTMGH, India*

Email: apookool@gmail.com

Accepted for publication: 24 November 2016

Introduction

Since their introduction into clinical use, Double J (DJ) ureteral stents have been an integral part of urologic surgery [1]. DJ ureteral stents are widely used to establish or improve drainage in cases of obstruction of urinary passage. They are also placed after the ureter injuries and prophylactically in urinary tract reconstructive surgeries [2]. Whatever the reason, the stents are meant to be removed after a certain amount of time. If not, they can cause a variety of problems, both for the patient as well as the surgeon, one of which is encrusted calculi. Additionally, prophylactic ureteric stenting is also associated with urinary tract

infections (UTIs), hematuria, stent migration, and forgotten stents [3]. However, there are situations, wherein patients (or their parents in case of children), fail to show up for removal of the stent, for varied reasons. The surgeon has a variety of methods up his sleeve to deal with these problems.

Here we report first case of a calculus encrusted over forgotten DJ stents within both left renal pelvis and urinary bladder in a 12-year-old female who had undergone left double ureteric re-implantation for grade IV vesicoureteral reflux 4 years earlier.

Case report

A 12-year-old female came to us with complaints of pain in lower abdomen on and off and burning micturition on and off since 3 years. The patient was a known case of left sided double moiety with Grade IV

vesicoureteral reflux. Left double ureteric re-implantation was done 4 years prior with two DJ stents kept in situ. Patient was called for follow-up for removal of DJ stents, but failed to follow up due to financial constraints. Her current complaints led to the suspicion of retained DJ stents.

Radiological investigations showed that not only were there retained DJ stents, but there were also encrusted calculi on their ends. An X-ray revealed the picture [Fig. 1].

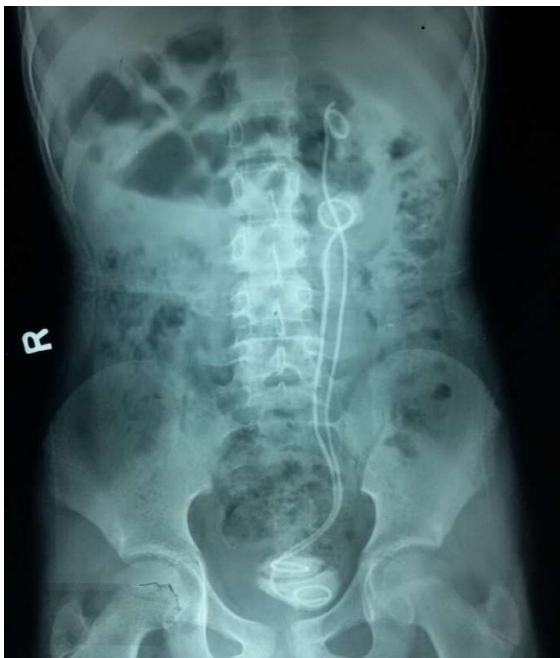

Fig. 1. Encrusted calculi on DJ stent ends.

Ultrasonography of the renal system revealed mild left sided hydronephrosis and hydroureter with two calculi in left renal pelvis and two calculi in urinary bladder. Hemoglobin 9.1g%, Total Leukocyte Count 10,200/mm³, BUN-14.7, serum creatinine 0.8 IU/L, urine a routine and microscopy (R&M)- 7-8 pus cells/hpf, urine culture and sensitivity (C&S)- no growth. Patient was operated for left pyelolithotomy along with suprapubic cystolithotomy. Both DJ stents along with all four calculi were extracted [Fig. 2].

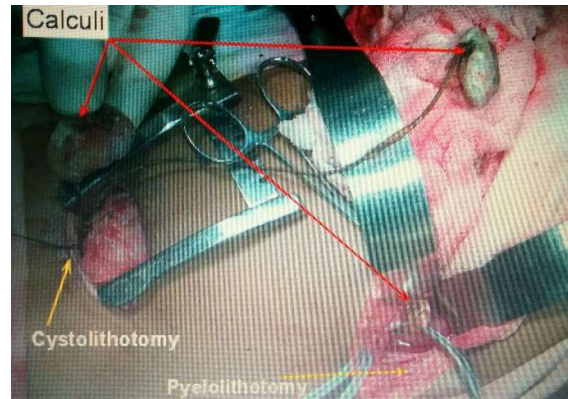


Fig. 2. View both DJ stents along with four calculi.

New DJ stents were kept in situ and it was ensured that the patient followed up their removal 6 weeks later.

Discussion

Forgotten DJ stents is a well-known complication of DJ stent placement post urological surgeries. Patients present generally with a chronic pain in lower abdomen. Some may present with urinary tract infection [4]. If presenting early, the stents have only slight encrustations over them. However, if the stents are in for a longer time, calculi can get formed, especially at the ends [5]. Most of the calculi in these cases can be removed by minimally invasive techniques, like percutaneous nephrolithotomy, cystoscopic removal with lithotripsy, extracorporeal shock wave lithotripsy (ESWL) with cystoscopy, etc [6,7]. However, for very large calculi, not amenable to removal via these methods, open surgery is undertaken. The procedure generally needed is suprapubic cystolithotomy for the bladder calculi with disconnection of stents, combined with a pyelolithotomy with stent extraction. There are also records of DJ stents being retained for as long as 7 years [8]. Not only can this be deleterious to the health of the patient and affect the urinary system in a bad way, it

can also land the surgeon in a soup legally, if there is no proper documentation of the patient being lost to follow-up. In our case, the patient came to us 4 years after the surgery when the DJ stents were placed, hence it needed open surgery to remove the stents and the stones.

There are usually no complications with short-term DJ stent urinary drainage. However, indwelling DJ stents can cause serious complications leading to incrustation calculus formation, as in our case. DJ indwelling should be as short as possible. If indwelling stenting is necessary, the DJ stent should be replaced with a new one in due time, or another kind of derivation should be performed. Careful monitoring of patients could exclude any possibility of a stent being forgotten at all. As a result, forgotten stents in children are a source of severe morbidity, additional/unnecessary hospitalization and definitely financial strain.

Acknowledgements

The author(s) declare that they have no competing interest and financial support.

References

- [1]Finney RP. Experience with new double J ureteral catheter stent. *J Urol*. 2002;167(2Pt2):1135-8.
- [2]Nerli RB, Magdum PV, Sharma V, Guntaka AK, Hiremath MB, Ghagane S. Forgotten/retained double J ureteric stents: A source of severe morbidity in children. *Afr J Paediatr Surg*. 2016;13(1):32-5.
- [3]Shohab D, Khawaja A, Atif E, Jamil I, Ali I, Akhter S. Frequency of occurrence of urinary tract infection in double j stented versus non-stented renal transplant recipients. *Saudi J Kidney Dis Transpl*. 2015;26(3):443-6.
- [4]Kelkar V, Patil, D. Cent. Management of forgotten double J stent and severe multiple large encrusted stones in the bladder and renal pelvis. *European J Urol*. 2012;65(4): 238-41.
- [5]Venkata R, Murthy K. Forgotten double J stent in the urinary bladder with calculus formation.. *IJCRI*. 2012;3(4): 45-47.
- [6]Borboroglu PG, Kane CJ. Current management of severely encrusted ureteral stents with a large associated stone burden.. *J Urol*. 2000;164;3(1):648–50.
- [7]Murthy KV, Reddy SJ, Prasad DV. Endourological management of forgotten encrusted ureteral stents. *Int Braz J: Off J Braz Soc Urol*. 2010; 36(4):420–9.
- [8]Chun-Kai Chen, Ching-Chia Li, Hung-Lung Ke, Yii-Her Chou. Double J Stent Forgotten For 7 Years: A Case Report. *The Kaohsiung Journal of Medical Sciences* 2003;19 (2):84-86

Access this article online

<http://pediatricurologycasereports.com>

Quick Response Code

