



## PEDIATRIC UROLOGY CASE REPORTS

ISSN 2148-2969

<http://www.pediatricurologycasereports.com>



### Giant congenital anterior urethral diverticulum with left side vesicoureteral reflux: A case report

Vishal Kirti Jain<sup>1</sup>, Neeraj Agarwal<sup>1</sup>, Neha Agarwal<sup>2</sup>

<sup>1</sup>Department of Urology and Renal Transplantation, SMS Medical College, Jaipur, Rajasthan, India

<sup>2</sup>Department of Pediatrics, J K Lon Hospital, Jaipur, Rajasthan, India

#### ABSTRACT

Anterior urethral diverticulum is a rare entity. A 12 year old boy presented with poor stream, recurrent urinary tract infection and fluctuant penile swelling at penoscrotal junction. Diagnosis of anterior urethral diverticulum with the left vesicoureteral reflux was made by retrograde urethrogram and micturating cystourethrogram. A giant diverticulum requires open diverticulectomy with urethral reconstruction which was done successfully without any complication in this case.

**Key Words:** Urethral diverticula; congenital urethral anomalies; vesicoureteral reflux.

*Copyright © 2018 pediatricurologycasereports.com*

*Corresponding Author: Vishal Kirti Jain*

*Department of Urology and Renal Transplantation,  
SMS medical college, Jaipur Rajasthan, India*

*E mail: [kirti\\_vishal@yahoo.co.in](mailto:kirti_vishal@yahoo.co.in)*

*ORCID ID: <https://orcid.org/0000-0002-8753-7673>*

*Accepted for publication: 14 August 2018*

#### Introduction

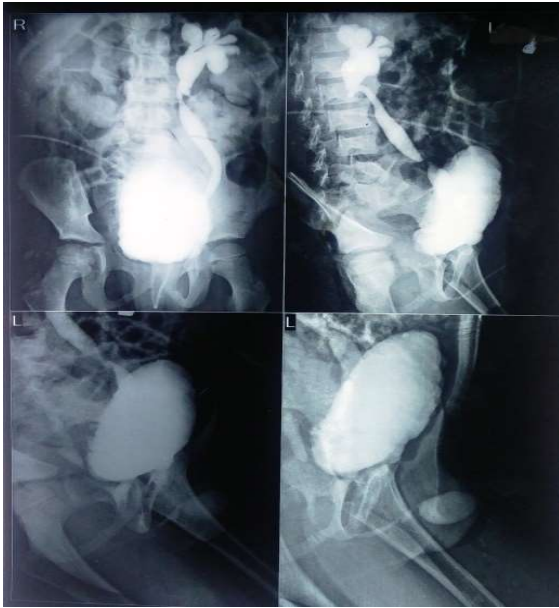Anterior urethral diverticulum is a rare but well known entity. It presents with obstructive voiding symptoms, recurrent urinary tract infection and visible swelling on penis in pediatric age group. Penoscrotal junction is the most common site, while up to one third cases present at the penile urethra [1]. Proximal changes in urinary tract may present due to obstruction [1,2]. It is diagnosed by retrograde urethrogram (RGU) and micturating cystourethrogram (MCU). It requires surgical intervention; either endoscopic or open approach. Long term follow up needed. Here we are presenting a case of anterior urethral

diverticula with left sided secondary vesicoureteral reflux (VUR).

#### Case report

A 12 year old boy presented with poor urinary stream, recurrent urinary tract infection and a visible swelling about 3 x 2cm size at penoscrotal junction. On examination swelling is non tender, fluctuant, skin is free and on compression swelling reduce with watery discharge per urethral. These are the telltale sign of anterior urethral diverticula. To confirm our diagnosis retrograde and micturating cystourethrogram were performed and study showed anterior urethral diverticula with irregular bladder wall and left sided VUR [Fig. 1]. Since it was large diverticulum, open diverticula excision was preferred. Midline exploration of penis on ventral aspect over diverticula was done and incision extended proximally and distally up to normal urethra

[Fig. 2A]. On incising the diverticula we found obstructing flap [Fig. 2B].



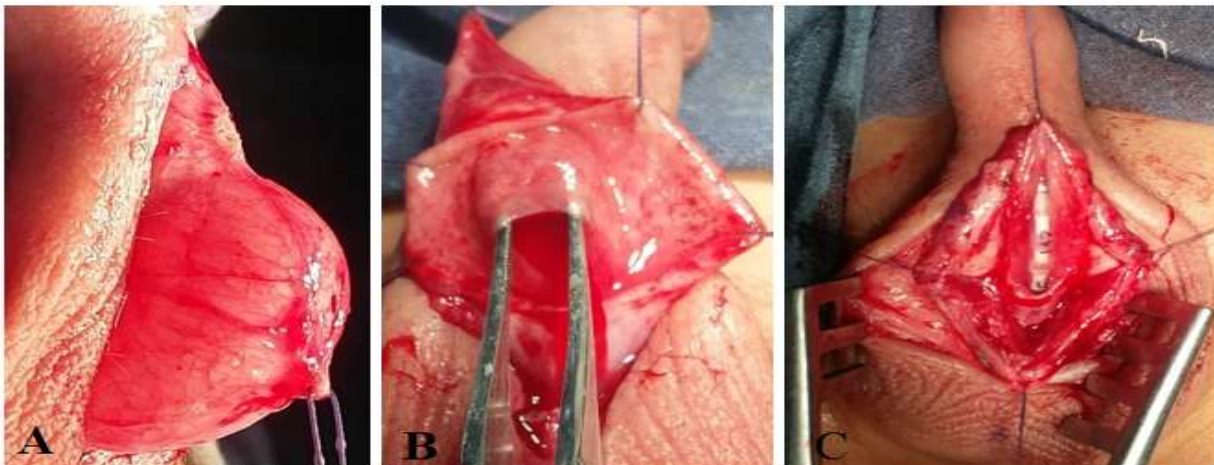
**Fig. 1.** Retrograde urethrograms and micturating cystourethrograms showing anterior urethral diverticula with the left sided vesicoureteral reflux (grade 3).

After meticulous dissection diverticula excised and urethra tubularized by PDS 6 'O' suture over 10 Fr feeding tube [Fig. 2C]. Dartos muscle placed as a barrier layer and skin closure done. Patient did well postoperatively and catheter was removed on 5th day after surgery. Patient was discharged on same day without any complication.

## Discussion

Congenital anterior urethral diverticulum is a well-known but rare entity. It present with lower urinary tract symptoms (dribbling of urine, poor urinary stream, urinary tract infection and stones) since birth with fluctuant swelling at the penile urethra. Swelling remains free from skin and non-tender. On compression fluid dribble out through urethra and swelling either reduce or disappear. Although it is congenital, yet, patients seek medical attention at any age with history of difficulty in micturition since birth [3].

It's a developmental anomaly. One hypothesis suggests it was a defect in corpora spongiosa with cystic dilatation of urethral glands [4]. Another is that they are associated with the valves of the anterior urethra. A third theory is that they are caused by the spontaneous rupture of paraurethral cysts toward the lumen of the urethra [2,4]. It has of two types; globular and saccular [5]. A saccular type diverticula may lead to urethral obstruction by a valve-like mechanism of its distal lip, which obscures the urethral lumen during filling [6,7]. Some authors believed that it was a sequel of anterior urethral valve while other says it was a separate entity. Diverticulum visualized as out pouching of urethra on ventral surface.



**Fig. 2.** A) Large anterior urethral diverticula at penoscrotal junction. B) Anterior urethral diverticula with valve (flap). C) Diverticulectomy and tubularization of urethra.

The diagnosis confirmed by micturating cystourethrogram and retrograde urethrogram. Proximal changes like megacystitis, VUR are other associated anomalies [8]. VUR present in around 20% of cases [5]. Cystourethroscopy can be both diagnostic and therapeutic for these cases. A diverticulum typically appears as an outpouching from the ventral wall of the urethra and has a proximal and distal rim [9]. Additionally, sonourethrography is now also being used as help in the diagnosis of anterior urethral diverticula [10,11]. Anterior urethral valve, dilated Cowper canal channel and posttraumatic diverticulum should be considered in differential diagnosis of anterior urethral diverticulum. [12].

The management of congenital anterior urethral diverticula depends on their type, size, and associated complications. Endoscopic and open surgery can be performed. Endoscopic incision over anterior lip is sufficient in small diverticula while large diverticulum requires open diverticulectomy and primary repair, as in our case. In infected cases marsupialization followed by staged urethroplasty is treatment of choice. If patient condition does not permit than suprapubic cystostomy or vesicostomy would help to relieve obstruction and definitive repair can be performed later [5,13,14].

In this study, a 12-year-old patient with congenital anterior urethral diverticulum and left-sided vesicoureteral reflux was presented. He had urethral diverticulum findings such as poor urine flow, recurrent urinary tract infections, and visible swelling of about 3 x 2 cm in the penoscrotal junction. Based on these findings, the patient was managed with open diverticulectomy with primary repair. The patient's symptoms disappeared after successful treatment made by open diverticulectomy and urethroplasty. These

patients require long term follow up for recurrence of diverticula, development of stricture and resolution of VUR.

### **Compliance with ethical statements**

*Conflicts of Interest: None.*

*Financial disclosure: None.*

*Consent: All photos were taken with parental consent.*

### **References**

- [1] Josep BD. Pediatric urology. Second ed. WB Saunders; 2001. p. 347.
- [2] Okur MH, Aydogdu B, Arslan S, Basuguy E. A congenital anterior urethral diverticulum associated with obstructive urinary symptoms in a 1-year-old male child: A case report and review of the literature. *Pediatr Urol Case Rep.* 2015; 2(3):25-30.
- [3] Cheong WY, Cheng HK, Tan KP. Congenital anterior urethral diverticulum. *Singapore Med J.* 1988;29(2):171-75.
- [4] Rawat J, Khan TR, Singh S, Maletha M, Kureel S. Congenital anterior urethral valves and diverticula: diagnosis and management in six cases. *Afr J Paediatr Surg.* 2009;6(2):102-5.
- [5] Zia-ul-Miraj M. Congenital anterior urethral diverticula in children. *Pediatr Surg Int.* 1999;15(8):567-69.
- [6] In: Walsh P, Retik A, Vaughan Jr E, Wei n A, eds. *Campbell's Urology*, WB Saunders Elsevier; 8th edition, 2002, pp 2225-26.
- [7] Barnewolt CE, Paltiel HJ, Lebowitz RL, Kirks DR. Genitourinary tract. In: Donald R. Kirks, N. Thorne Griscom (Eds). *Practical pediatric imaging; Diagnostic radiology of infants and children.* Philadelphia, Lippincott Raven; Third Ed. 1998, pp 1009-1170.

- [8] Silberzweig JE, Baskin BL, Becker JA. Congenital anterior urethral diverticulum. *Abdom Imaging*. 1993;18(4):396-98.
- [9] Singh SK, Ansari M. Congenital anterior urethral diverticulum. *Turk J Urol*. 2014;40(3):182-4.
- [10] Bhadury S, Parashari UC, Singh R, Kohli N. MRI in congenital duplication of urethra. *Indian J Radiol Imaging*. 2009;19(3):232-34.
- [11] Goyal M, Sharma R, Gupta DK, Sharma A, Berry M. Congenital anterior urethral diverticulum: sonographic diagnosis. *J Clin Ultrasound*. 1996;24(9):543-44.
- [12] Kadian YS, Rattan KN, Singh M, Kajal P. Congenital anterior urethral diverticulum in children: a case report and review. *ISRN Surg*. 2011;2011:120307.
- [13] Bhatnagar V, Lal R, Mitra DK. Primary reconstruction of a congenital anterior urethral diverticulum. *Pediatr Surg Int*. 1999; 15(3-4):294-95.
- [14] Gupta DK, Srinivas M. Congenital anterior urethral diverticulum in children. *Pediatr Surg Int*. 2000;16(8):565-68.

Access this article online

<http://pediatricurologycasereports.com>

Quick Response Code

