

Giant nephroblastoma in newborn: Case report and literature review

Carolina Talini¹, Letícia Alves Antunes¹, Bruna Cecília Neves de Carvalho¹, Hellen Paula de Oliveira¹, Bruna Romanelli², Giovana Paludo², César Cavalli Sabbaga¹, Maria Helena Camargo Peralta del Valle^{1,2,3}

¹Hospital Pequeno Príncipe, Curitiba/PR, Brasil

²Departamento de Medicina, Universidade Positivo, Curitiba/PR, Brasil

³Universidade Federal do Paraná, Curitiba/PR, Brasil

Abstract

Nephroblastoma in a children younger than 3 months is a very rare condition, comprising less than 2% of cases. The aim of this study is to present a case of nephroblastoma diagnosed in a newborn. Female baby, presented at the urology pediatric service with 70 days newborn. Mother reported increased abdominal volume, which was first noticed at 15 days of life with progressive worsening. CT scanning showed a giant, solid, rounded mass, with smooth margins, originating from the right kidney and displacing the kidney to a posteroinferior position. Total nephrectomy was performed and pathologic examination confirmed nephroblastoma. No neoadjuvant chemotherapy was performed and postoperative vincristin was administered. One year after surgery, patient remains in follow up with the pediatric oncology service and presented no complications or signs of recurrence. Nephroblastoma in newborn is a rare condition, their detection in neonatal period and early infancy must be stimulated and studies focused on the possibility of congenital presentations must still be made.

Keywords

Nephroblastoma; newborn; renal tumors.

Copyright © 2016 [pediatricurologycasereports.com](http://www.pediatricurologycasereports.com).

Corresponding Author: Maria Helena Camargo Peralta del Valle. Departamento de Medicina, Universidade Estadual de Ponta Grossa/PR, Brasil
E-mail: mhperalta@gmail.com
Accepted for publication: 10 Jun 2016

Introduction

Nephroblastoma, also known as Wilm's tumor, is the most frequent renal neoplasia in infancy, comprising 95% of renal tumors in children under 15 years and

approximately 7% of all pediatric neoplasms [1]. In 80% of cases it affects children under 5 years, however, their presentation in infants less than 1 year old is low and often associated with predisposing genetic diseases [1,2]. In toddlers younger than 3 months, nephroblastoma is a very rare condition, comprising less than 2% of cases [3]. This study aims to report a case of a newborn that indicated with symptoms when she was 15 days old and was diagnosed with Wilm's tumor at 70th day of life.

Case Report

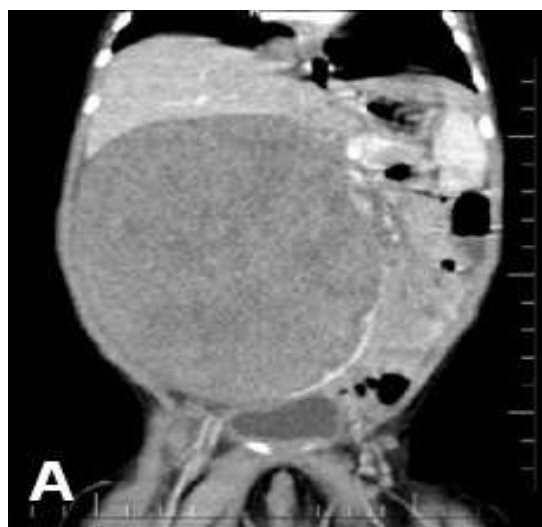
Female baby, first admitted to the pediatric urology service at 70th day of life. Pregnancy had been uneventful and birth weight was 3.400g. The mother reported that in the first 15 days of life she noticed increased abdominal size. During the first 50 days of life she noticed progressive worsening associated with eventual regurgitation that was initially treated as reflux. Around 70 days of life the baby started having respiratory distress and severe abdominal distention. Abdominal ultrasound in a community service showed a supposed abdominal cyst, and then the child was referred to our hospital for investigation. There were no similar cases in family history. During the physical examination there was an abdominal mass with well

defined limits, hardened, mobile, measuring approximately 10 cm and crossing abdominal midline [Fig. 1].

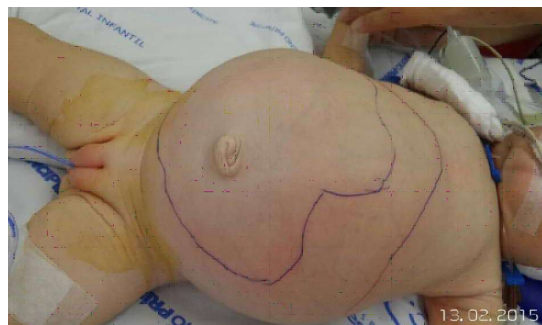

Fig. 1. Increased abdominal volume with extensive palpable mass.

A CT scan was performed and showed a solid, rounded mass with smooth margins, originating from the right kidney and displacing the kidney to a posteroinferior position. There was compression of the inferior vena cava by the mass, which measured 11,5 x 10,5 x 9,8 cm. Bladder was also compressed by the mass [Fig. 2A,B]. Chest CT scan was normal.



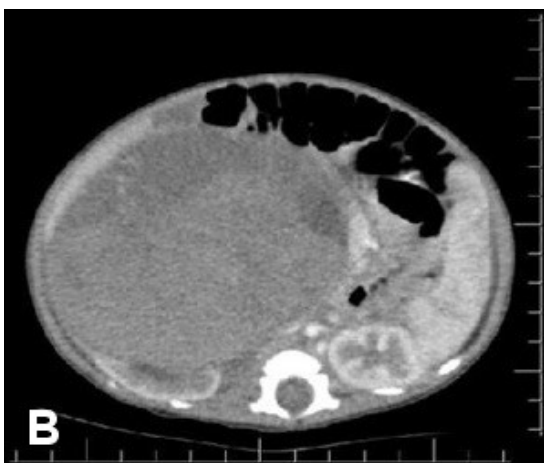


Fig. 2A,B. CT scan suggesting renal tumor.

The tumor was classified as a Stage 1 with intermediate risk. The proposed procedure surgery was total nephrectomy. Open nephrectomy was performed uneventfully, and the patient was kept in the pediatric surgical ICU for 3 days. Total length of hospital stay was 8 days. Pathologic examination demonstrated mixed-type nephroblastoma with epithelial predominance and percentage of necrosis was 25-30%. Surgical margins were negative for tumor. The protocol used for adjuvant was SIOP. As the baby was younger than 6 months, no neoadjuvant chemotherapy was performed, and 10 cycles of Vincristin were administered postoperatively. One year after surgery patient remains in follow up with the pediatric oncology service and there have been no complications or signs of recurrence.

Discussion

This case report describes a female patient diagnosed with nephroblastoma at 2 months of age. This case is different from usual nephroblastoma cases as the patient first presented symptoms with 15 days old. Generally nephroblastoma is considered as a preschool children disease with median age of 3,5 years at time of diagnosis. Despite conflicting epidemiology, this patient presented with typical symptoms like abdominal palpable mass and enlargement of abdominal girth, which are the most common presentations of renal tumors (77%) [4]. The authors believe that both regurgitation and respiratory distress most probably occurred due to mass effect of the tumor, leading to gastric compression and limitation of diaphragm movement. This is likely because tumor weight was 558g corresponding to 13% of the children's total weight. Tumor volume was estimated in 420 ml. The initial clinical presentation is an asymptomatic abdominal mass often noted by the pediatrician in routine examination or in some cases by parents [2,5]. Other symptoms are even abdominal pain, fatigue, and vomiting in about 30% of patients; hypertension, fever or hematuria in 25% and more rarely other symptoms like varicocele, hepatomegaly, ascites, congestive heart failure, and acquired von Willebrand disease

that can occur mainly as a result of the presence of intra-atrial, renal vein or inferior vena cava tumors [1,4]. During the prenatal period ultrasound investigation can detect anatomic alterations in urinary tract after 11 weeks of pregnancy, that added to the amount of amniotic liquid and renal parenchyma echogenicity can make possible the diagnose of renal diseases still in intrauterine period. In the case here reported the patient's mother referred oligohydramnios during pregnancy that can be a consequence of nonspecific renal alteration as fetal urine is the main component of amniotic liquid in the end of pregnancy [2,3]. This fact associated to the mother perception of increased abdominal volume since the baby was newborn lead the authors to consider the possibility of congenital nephroblastoma. Although the fact that morphological ultrasound during pregnancy was not performed and that there is not enough studies that correlate Wilm's tumor with oligohydramnios demonstrate insufficient data to corroborate the hypothesis. Nevertheless there are some reported cases of congenital nephroblastoma reported in literature and neonatal nephroblastoma represented 0,11% of all patients included in clinical trials of the National Wilm's Tumor Study [4].

Ultrasound usually shows a tumor mass with smooth margins, uniform echogenicity and variable size. CT scan is considered a most accurate method [3,5] showing a hipodense mass compared to surrounding tissues, and usually displacing adjacent structures.

The main differential diagnosis is with neuroblastoma, but mesoblastic nephroma, renal adenocarcinoma, rhabdomyosarcoma, hepatoblastoma, hepatocellular carcinoma, polycystic kidneys, kidney multicystic and hydronephrosis should also be considered².

Currently the initial therapeutic approach in USA and Canada, which use the Pediatric Oncology Group Protocol (COG - Children's Oncology Group), indicates immediate nephrectomy of affected kidney. However, Europe and other countries, including Brazil, follow the International Society of Pediatric Oncology Protocol (SIOP - International Society of Pediatric Oncology) [6] which advocates the use of neoadjuvant chemotherapy shortly after the clinical or imaging diagnosis. According to the SIOP there is no need for biopsy, as less than 1% of cases treated after only imaging are not neoplastic kidney diseases and less than 5% correspond to other renal tumors. This protocol aims to reduce the rates of surgical complications like tumor rupture and allows selectively performing of laparoscopic surgery [1,4,7].

The indicated surgical procedure is total nephrectomy associated with lymph nodes resection – renal hilum and periaortic, even if they do not seem affected macroscopically [4]. There is no indication of partial nephrectomy as primary treatment, due to the central location of the tumor in 90% of cases. In bilateral cases, total nephrectomy must be performed on the side of the larger tumor mass and renal parenchyma should be preserved by enucleation of the tumor mass of smaller size [4,7].

References

1. Schwartsman BG, et al. Doenças Neoplásicas da Criança e do Adolescente. In: Coleção Pediatria Instituto da Criança do Hospital das Clínicas. 1st ed. Manole; 2012. pp. 105-121.
2. UpToDate database – Wilms Tumor. 2015; Available from: <http://www.uptodate.com/contents/search?search=wilms+tumor&x=0&y=0>. Access: 15/04/2016.
3. Malkan AD, Loh A, Bahrami A, et al. An approach to renal masses in pediatrics. *Pediatrics*. 2015;135(1):142-58.
4. International Society of Paediatric Oncology – Protocol SIOP 2001. Available from: <https://www.skion.nl/workspace/uploads/Protocol-SIOP-2001.pdf>. Access: 15/04/2016.
5. Júnior DC, et al. Tratado de Pediatria da

Conclusion

Despite well-established literature, studies focused on rare presentations are still needed, especially regarding the detection of tumors in the neonatal period and early infancy, as well as studies aimed at prenatal assessment for better knowledge of possibly congenital presentations.

Acknowledgements

The author(s) declare that they have no competing interests and financial support.

Sociedade Brasileira de Pediatria. 3rd ed. Manole; 2014. pp. 2225-2230.

6. Abdullah Y, Karpelowsky J, Davidson A, et al. Management of nine cases of Wilms' tumour with intracardiac extension - a single centre experience. *J Pediatr Surg*. 2013;48(2):394-9.
7. Bhatnagar S. Management of Wilm's tumor: NWTS vs SIOP. *J Indian Assoc Pediatr Surg*. 2009; 14 (1): 6-14.

