



## Hydronephrosis associated with a huge ovarian mature cystic teratoma in a 16-year-old girl: A case report

Sevinc Akdeniz<sup>1</sup>, Ulas Alabalik<sup>2</sup>, Mehmet Hanifi Okur<sup>3</sup>

Department of Pediatric Surgery<sup>1</sup>, Şırnak State Hospital, Şırnak, Turkey

Department of Pathology<sup>2</sup>, Pediatric Surgery<sup>3</sup>, Dicle University, School of Medicine, Diyarbakir, Turkey



### ABSTRACT

We report the case of a 16-year-old female with a huge mass (40 × 30 × 40 cm) on the left ovary, causing mild bilateral hydronephrosis. Ultrasonography and computed tomography allowed us to diagnose this condition and showed an associated uretero-hydronephrosis. A unilateral salpingo-oophorectomy was performed on the left ovary, and final pathology revealed a mature cystic teratoma. The patient did not experience any problems in the follow-up six months later, and her hydronephrotic appearance disappeared.

**Key Words:** Abdominal mass, huge ovarian cyst, teratoma, child.

© 2020 [pediatricurologycasereports.com](http://www.pediatricurologycasereports.com)

✉ Dr. Mehmet Hanifi Okur

Department of Pediatric Surgery, Dicle University,  
School of Medicine, Diyarbakir, Turkey

E-mail: [okurmh@gmail.com](mailto:okurmh@gmail.com)

Received: 2020-08-18 / Accepted: 2020-08-28

Publication Date: 2020-09-01

### Introduction

Ovarian tumors in children are rare and account for less than 2% of all tumors in females younger than 16 years old [1]. Mature cystic teratomas, often referred to as dermoid cysts, are the most common benign ovarian germ cell tumors found in adolescents and continue to challenge clinicians to determine proper treatment [2]. These cysts usually occur in the second and third decades of life. Giant ones (> 15 cm) are very rare and may be asymptomatic. Because of associated risks such as mass effect and suspicion of ovarian

malignancy, giant cysts usually require resection (mostly as oophorectomy) [3,4]. Acute or chronic abdominal pain is the most common feature in symptomatic cases, while other symptomatology is dependent on cyst location, size, and the resulting abdominal organ compression (e.g., bowel obstruction, hydronephrosis, lower extremity lymphedema) [5,6]. Here, we present the case of a giant ovarian mature cystic teratoma that filled the patient's entire abdomen, detailing features in its diagnosis, treatment and associated complications such as hydronephrosis.

### Case report

A 16-year-old female patient was admitted to an outpatient clinic with complaints of abdominal distension and pain that had increased over the last two weeks. Her medical

history has been positive for heavy menses since menarche, which started at age 12. A physical examination showed normal vital signs, and an abdominal examination revealed distension and a wide midline mass extending to the epigastrium.

In the ultrasonographic (USG) examination, a cystic mass with a diameter of 25 x 10 x 23 cm and internal echoes and echogenic septations was observed almost completely filling the pelvic area and abdomen. An abdominal and pelvic computed tomography (CT) revealed a cystic heterogeneous mass approximately 202 x 130 x 283 mm in size, starting from the midline of the pelvic region and extending to the epigastric level. The mass contained areas of fat density and thin septations accompanied by calcific and contrasting solid components. The cystic lesion described was compressing the left renal vein and vena cava posteriorly. In addition, there were mild hydronephrotic changes in both kidneys (Figs. 1A and 1B).

Tumor markers were as follows:  $\beta$ -HCG <0.1 mU/mL,  $\alpha$ -fetoprotein 0.67 mcg/L, CA-125 51,7 kU/L.

A laparotomy was performed through midline incision, revealing a huge left ovarian cyst measuring 40 x 30 x 40 cm. The cyst's wall was smooth, with no evidence of torsion or

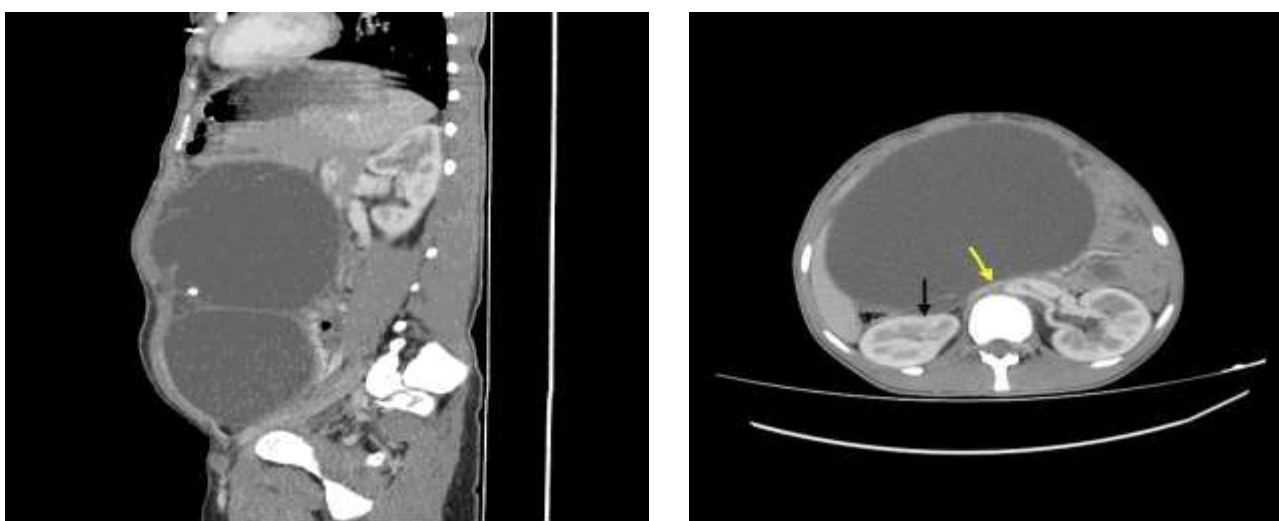
rupture. A left salpingo-oophorectomy was then performed (Fig. 2). The omentum, peritoneum, liver, pelvis, right ovary, and uterus all appeared normal.

Microscopically, the mass was a mature cystic teratoma containing multiple stratified squamous epithelia, hair roots, and adipocyte and cartilage tissue areas (Fig. 3). Microscopic examination showed no malignant transformation. The patient recovered uneventfully and was discharged from the hospital three days after surgery. Furthermore, the patient experienced no problems in the follow-up six months later, and her hydronephrotic appearance disappeared.

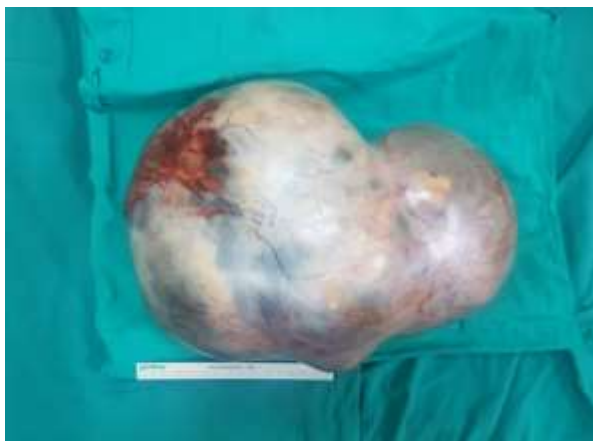### Discussion

Pathologies such as choledochal cysts, kidney cystic diseases, lymphangioma, duplication cyst, cystic teratoma, pseudocyst, pancreatic cyst, hydatid cyst, ovarian cyst, and urachal cyst are abdominal cystic masses commonly encountered in childhood [7,8]. Teratomas originating from the ovary can be found in mature or immature morphologies.

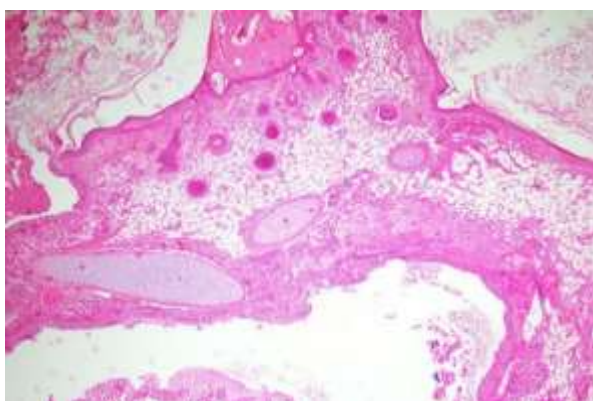
Mature cystic teratomas, often referred to as dermoid cysts, are the most common germ cell tumors in the ovaries of women of reproductive age.



**Figs. 1.** Computed tomography of the abdomen. **A)** Sagittal reconstruction view: Giant cystic mass with septation. **B)** Axial abdomen CT image of the right kidney secondary to the effect of mass (black arrow) and slight compression of the left renal vein (yellow arrow).



**Fig. 2.** A huge cyst in left ovary.



**Fig. 3.** Histopathological slide showing multiple stratified squamous epithelium, hair roots, and adipocyte and cartilage tissue areas.

Ovarian teratomas are often asymptomatic until they reach significant size and cause compression symptoms. Ultrasonography is usually diagnostic, with a reported sensitivity of 85% [4,9]. CT findings in mature cystic teratomas include fat in 93% of cases [7,8].

Because of associated risks, such as compression effect of masses reaching large dimensions and ovarian malignancy suspicion, the treatment approach is usually a resection known as oophorectomy [3]. As stated above, most patients with mature cystic teratomas are asymptomatic, yet symptoms may occur with an increase in mass size. In addition, most patients can apply with ovarian torsion. Although rare, patients may present with a rupture of cysts and pouring of sebaceous

material into the abdominal cavity [3,4]. A definitive diagnosis is made during surgical excision of the mass [8]. Surgery is curative, and malignant transformation of a mature cystic teratoma is rare [8].

The conventional approach to the treatment of giant ovarian cysts is usually a cystectomy or oophorectomy, followed by complete midline laparotomy [3,10]. Katke [10] suggested that giant cysts require resection due to compression symptoms and malignancy risks. However, he argued that benign cysts in young women should be treated conservatively, with a laparotomy performed to prevent perforation and spillage of cyst fluid into the cavity. Uyanikoglu and Dusak chose conservative laparoscopic methods both to protect the patient's reproductive health and to provide better skin appearance cosmetically.

In the case presented here, the mass was totally removed by laparotomy with a conservative approach. The negative symptoms caused by the giant mass were completely eliminated without any problems. Unfortunately, the compression of organs (e.g., urinary system) by these giant masses in the abdomen can have important negative consequences. To eliminate these complications, reaching an immediate diagnosis and treatment plan is crucial.

### ***Compliance with ethical statements***

*Conflicts of Interest: None.*

*Financial disclosure: None.*

*Consent: Patient confidentiality has been maintained and written consent for the publication of patient details and clinical pictures have been obtained from the patient's father and can be furnished when required.*

### ***ORCID iD of the author (s)***

*Sevinc Akdeniz / 0000-0002-8295-2456*

*Ulas Alabalik / 0000-0003-4551-8439*

*Mehmet H Okur / 0000-0002-6720-1515*

### **References**

- [1]Thaweeikul P, Thaweeikul Y, Mairiang K. A huge ovarian mucinous cystadenoma associated with contralateral teratoma and polycystic ovary syndrome in an obese adolescent girl. *Asia Pac J Clin Nutr.* 2016;25(4):920-23.
- [2]Multani J, Kives S. Dermoid cysts in adolescents. *Curr Opin Obstet Gynecol.* 2015;27(5):315-19.
- [3]Dolan MS, Boulanger SC, Salameh JR. Laparoscopic management of giant ovarian cyst. *JSLs.* 2006;10(2):254-56.
- [4]Uyanikoglu H, Dusak A. A Huge Ovarian Dermoid Cyst: Successful Laparoscopic Total Excision. *J Clin Diagn Res.* 2017;11(8):QD03-QD05.
- [5]Huis M, Balija M, Lez C, et al. Ciste mezenterija [Mesenteric cysts]. *Acta Med Croatica.* 2002;56(3):119-24.
- [6]Herman TE, Shackelford GD. Large torsed neonatal ovarian cysts associated with massive vesicoureteral and intrarenal reflux. *J Perinatol.* 1997;17(1):75-78.
- [7]Buy JN, Ghossain MA, Moss AA, et al. Cystic teratoma of the ovary: CT detection. *Radiology.* 1989;171(3):697-701.
- [8]Alamarat Z, Onwuzurike N, Azher Q, et al. Huge teratoma in a teenager. *Oxf Med Case Reports.* 2017;2017(8):omx040.
- [9]Sait K, Simpson C. Ovarian teratoma diagnosis and management: case presentations. *J Obstet Gynaecol Can.* 2004;26(2):137-42.
- [10]Katke RD. Giant mucinous cystadenocarcinoma of ovary: A case report and review of literature. *J Midlife Health.* 2016;7(1):41-44.