

**PEDIATRIC UROLOGY CASE REPORTS**

ISSN 2148-2969

<http://www.pediatricurologycasereports.com>**Hypertrophic labia minora associated with recurrent urinary tract infections in two adolescents: Case reports and literature review****Hulya Ozturk¹, Muzeyyen Astarci²**¹Department of Pediatric Surgery, ²Pathology, Bolu Abant Izzet Baysal University, Faculty of Medicine, Bolu, Turkey**ABSTRACT**

We presented two girls aged 11 and 14, which have similar complaints, applied at the different dates to our pediatric surgical outpatient clinic with complaints of left and right labia minora protrusion (respectively), urination difficulty, itching and malodor. The patients were reported to have symptomatic urinary tract infections every 2 to 3 months. Here, for reduction labioplasty, a simple edge technique and different surgical options were discussed with literature review.

Key Words: Adolescent; labia minora; hypertrophy; recurrent urinary tract infections; labioplasty.

Copyright © 2018 pediatricurologycasereports.com

*Corresponding Author: Dr. Hulya Ozturk
Department of Pediatric Surgery, Bolu Abant Izzet
Baysal University, Faculty of Medicine, Bolu, Turkey.
E mail: hulya_ztrk@yahoo.com
ORCID ID: [0000-0001-9277-9119](https://orcid.org/0000-0001-9277-9119)
Accepted for publication: 8 June 2018*

complaints of the patient are more important than the measurements [1,2,5]. We presented by reviewing the literature the results of labioplasty reduction of two patients with labial hypertrophy who presented with recurrent urinary tract infection.

Introduction

Hypertrophic labia minora is defined as an abnormal growth of more than 4-5 cm from the base to the edge of the labia [1,2]. It is usually bilateral but has been reported unilaterally in 10-15% of cases [1,3]. Common symptoms of labial hypertrophy are discomfort during exercise, sitting or sexual intercourse, chronic irritation, problems with personal hygiene, infection, intermittent self-catheterization, and other activities such as cycling and riding [1-4]. Indications for surgical intervention may be due to functional, aesthetic and psychological reasons. In addition, it should be noted that the

Case report

Two girls aged 11 and 14, which have similar complaints, applied at the different dates to our pediatric surgical outpatient clinic with complaints of left and right labia minora protrusion (respectively), urination difficulty, itching, malodor. The patients were reported to have symptomatic urinary tract infections every 2 to 3 months. In addition to personal hygiene problems, there were also problems with sports exercises, social difficulties with it being noticeable when wearing swimsuits or trousers. In the gynecologic examination of

both cases, left and right hypertrophic labia minora were detected [Fig. 1A,B], and we performed a reduction labioplasty after informed consent was obtained in accordance with the Declaration of Helsinki.

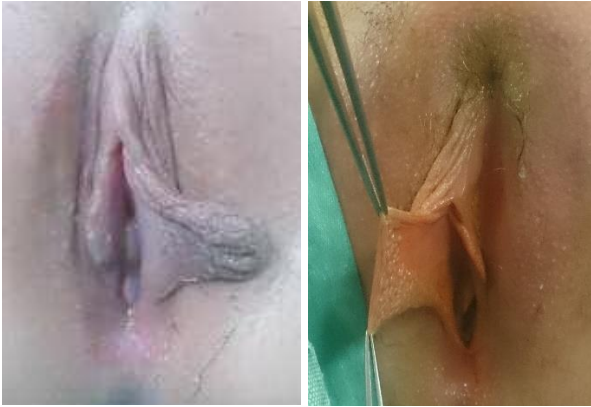

Fig. 1. (A) Left and (B) right labial hypertrophy fully extended.

Patients were placed under dorsal lithotomy under general anesthesia. Then, reduction labioplasty was done by simple edge excision technique using the cautery while preserving the labial contour. After adequate hemostasis, the wound was closed with 4-0 vicryl sutures in a simple interrupted fashion [Fig. 2].

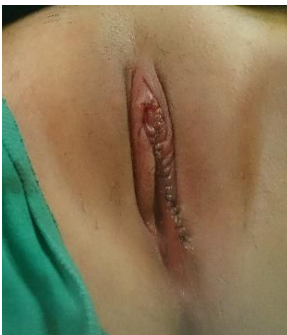

Fig. 2. Resection of the excess labial tissue using the simple edge excision technique.

There was no significant pain or complication after the operation. The patients were discharged at the same day with an indwelling foley catheter for one days. Pathology was revealed hypertrophic tissue [Fig. 3]. The patients and their mother were quite happy with the cosmetic and functional outcome.

After this procedure, they have not had any recurrent urinary tract infections and, the results were satisfactory with no further expansion of the labia.

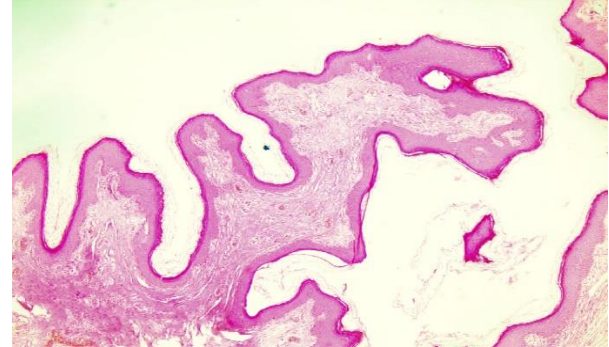


Fig. 3. Fibroepithelial polyp lined by stratified squamous epithelium. (Hematoxylin and eosin X4).

Discussion

The hypertrophic labia minora resembles the ears of a spaniel with a wing-like protrusion from the vulva [6]. The enlargement can be unilateral, bilateral or sometimes asymmetrical. In these cases, the distance between the labia minora base and the edge is over 4 cm [1]. However, in the presence of persistent symptoms, the patient may need surgical correction [7]. The age of application is usually between 12 and 67 [1].

The etiologic factors that are thought to cause the disease are a congenital anatomic variant, local estrogen, childhood estrogens, hand stretching or weight attachment (Hottentot apron), chronic lymphedema, similar to fibroepithelial stromal polyps and recurrent dermatitis [8,9,10]. Additionally, labia minora hypertrophy can be created by traditional manipulations (stretching of the labia manually or by weights), which are practiced on female children in some tribes [3,5].

Labia minora hypertrophy may cause various functional symptoms such as local irritation, chronic urinary tract infections, pain, personal

hygiene problems, and discomforts during sports exercises or sexual activities. In addition, the visible of the labia minora may be an important psychological problem for the patient with concerns about "“bulge”" and asymmetry or hypertrophy [1-9]. It is important to note that they have an important place in patients with aesthetic concerns in this disease. Discomfort in certain types clothes such as tight trousers and swim suits, difficulty in participating in athletic activities and a significant stigma are among the most common aesthetic complaints [11]. As another patient group, it is also a recognized problem in those who self-catheterize, or with mobility disabilities [12].

There are some debates about when labioplasty should be applied. Some studies have suggested that the minimum age should be between 15 and 16 years. The reasons for this approach are as follows: the continuation of the growth of the labia, the approval of young women and the need for a second method. When labioplasty is done in adolescence, the decisions of the operation should always include the parent or guardian [7]. One study suggests that the reduction of hypertrophic labia minora improves the aesthetic appearance in 91% of cases, alleviates the disease in 96%, and the results are satisfactory in 96%. In addition, they emphasized that a size >4 cm should never be considered as an aim for surgery unless labial hypertrophy is a real aesthetic or physical discomfort [1].

The aim of the labioplasty is the creation of a hypertrophic labial tissue resection and a symmetrical and diminished labial image [10]. Furthermore, minimal invasiveness, preservation of the introitus, optimal color/texture match, and maintenance of the neurovascular supply are among additional goals of this procedure [13]. In recent years,

many techniques have been described, such as edge resection, wedge resection, Z-plasty, deep dilatation, W-plasty, and laser labiaplasty [10]. Edge resection (protuberant tactile flat amputation) is the first labiaplastic technique described in the literature [10]. This technique is the technique most commonly used in practice and has the easiest healing period [7]. In 16 of 17 articles published between 1976 and 2014, positive results were recorded in terms of patient satisfaction and low morbidity. Only Hodgkinson and Hait 43 reported an aesthetically and functionally unsatisfactory extension of labia minora [14]. Complications are usually associated with excessive tissue resection and scar tissue [7, 10]. Many new techniques, such as wedge, aim to achieve adequate volume reduction and preservation of the natural labial contour [13]. It is advisable for patients to keep the operating area clean and dry, away from strenuous activities, and wear loose clothing to protect it from friction [7].

Labia minora hypertrophy usually does not require medical follow-up unless it is symptomatic. However, when the patient has functional concerns such as chronic urinary infections, reduction of labia minora should be recommended. The two cases presented in this study are the youngest reported cases with unilateral labial hypertrophy that we have found in English literature. Reduction labioplasty was done by simple edge excision of tissue while preserving the labial contour. Labia minora hypertrophy is thought to be predispose to recurrent urinary tract infections. Therefore, there is an ongoing investigation into the possible association between recurrent urinary tract infection and labial hypertrophy. Chronic urinary tract infections can be due to pooling of sweat or secretions in the space created by labial hypertrophy. Additionally,

difficulties with altered odor or hygiene of the genitalia due to enlarged labia minora, including not being able to wipe properly with toilet paper, difficulty in placing tampons, and itching due to bacterial accumulation. In two cases presented here, the urinary complaints disappeared after the operation and the patient and mother were satisfied with the cosmetic side.

Compliance with ethical statements

Conflicts of Interest: None.

Financial disclosure: None.

Consent: All photos were taken with parental consent.

References

- [1] Rouzier R, Louis-Sylvestre C, Paniel BJ, Haddad B. Hypertrophy of labia minora: experience with 163 reductions. *Am J Obstet Gynecol.* 2000;182(1 Pt1):35-40.
- [2] Solanki NS, Tejero-Trujeque R, Stevens-King A, Malata CM. Aesthetic and functional reduction of the labia minora using the Maas and Hage technique. *J Plast Reconstr Aesthet Surg.* 2010;63(7):1181-85.
- [3] Maas SM, Hage JJ. Functional and aesthetic labia minora reduction. *Plast Reconstr Surg.* 2000;105(4):1453-56.
- [4] Wu JA, Braschi EJ, Gulminelli PL, Comiter CV. Labioplasty for hypertrophic labia minora contributing to recurrent urinary tract infections. *Female Pelvic Med Reconstr Surg.* 2013;19(2):121-23.
- [5] Lynch A, Marulaiah M, Samarakkody U. Reduction labioplasty in adolescents. *J Pediatr Adolesc Gynecol.* 2008;21(3):147-49.
- [6] Jeffcoate N. Hypertrophy of the labia minora "Spaniel ear nymphae." In: *Principles of gynaecology.* 4th ed. London: Butterworths; 1975. p. 151.
- [7] Reddy J, Laufer MR. Hypertrophic labia minora. *J Pediatr Adolesc Gynecol.* 2010;23(1):3-6.
- [8] Heller DS, Kuye OO. Recurrent hypertrophy of the labia minora: a hormonally related lesion possibly related to fibroepithelial stromal polyps of the vulva. *J Lower Genit Tract Dis.* 2011;15(1):69-70.
- [9] Barrett MM, Carlson JA. A clinicopathologic study of labia minora hypertrophy: signs of localized lymph edema were universal. *J Lower Genit Tract Dis.* 2014;18(1):13-20.
- [10] Oranges CM, Sisti A, Sisti G. Labia minora reduction techniques: a comprehensive literature review. *Aesthet Surg J.* 2015;35(4):419-31.
- [11] Choi HY, Kim KT. A new method for aesthetic reduction of labia minora (the deepithelialized reduction labioplasty). *Plast Reconstr Surg.* 2000;105(1):419-22.
- [12] Gowen RM, Martin VL. Labia minora reduction in an iron-lung disabled woman. *Obstet Gynecol.* 1988;71(3 Pt 2):488-89.
- [13] Motakef S, Rodriguez-Feliz J, Chung MT, Ingargiola MJ, Wong VW, Patel A. Vaginal labioplasty: current practices and a simplified classification system for labial protrusion. *Plast Reconstr Surg.* 2015;135(3):774-88.
- [14] Hodgkinson DJ, Hait G. Aesthetic vaginal labioplasty. *Plast Reconstr Surg.* 1984;74(3):414-16.

Access this article online

<http://pediatricurologycasereports.com>

Quick Response Code

