

**PEDIATRIC UROLOGY CASE REPORTS**

ISSN 2148-2969

<http://www.pediatricurologycasereports.com>**Indirect inguinal hernia containing uterus, fallopian tube, and ovary in a term infant****Turgay Kara<sup>1</sup>, Erdi Seckin<sup>1</sup>, M. Sedat Durmaz<sup>1</sup>, Canan Kocaoglu<sup>2</sup>**<sup>1</sup>Department of Radiology, University of Health Science, Konya Training and Research Hospital, Konya, Turkey<sup>2</sup>Department of Pediatric Surgery, University of Health Science, Konya Training and Research Hospital, Konya, Turkey**ABSTRACT**

Indirect inguinal hernia is most commonly seen in infants. Prevalence is lower in girls. Both uterus and ovary including hernia sac is extremely rare. Early diagnosis and surgery is critical, since strangulation and necrosis of these organs may lead to serious conditions and infertility. Doppler Ultrasound (US) is the effective method in differentiation and diagnosis of inguinal hernias of infants. In this very rare case, according to the literature knowledge, we aimed to represent the sonographic and surgical features of a 40 day old vaginally delivered term female infant admitted to our clinic with right groin mass and diagnosed as indirect incarcerated inguinal hernia containing viable uterus, fallopian tube and ovary via US. She went under early surgery through which ovary, fallopian tube and uterus were found in hernia sac. All herniated organs were reduced into peritoneal cavity and the hernia sac was high –ligated.

**Key Words:** Inguinal hernia; incarcerated hernia; uterus; ovary; ultrasound; child.*Copyright © 2018 pediatricurologycasereports.com*

*Corresponding Author: Dr. Turgay Kara,  
Department of Radiology, University of Health Science,  
Konya Training and Research Hospital, Konya, Turkey  
E-mail: [trgykr@gmail.com](mailto:trgykr@gmail.com)  
Accepted for publication: 25 March 2018*

**Introduction**

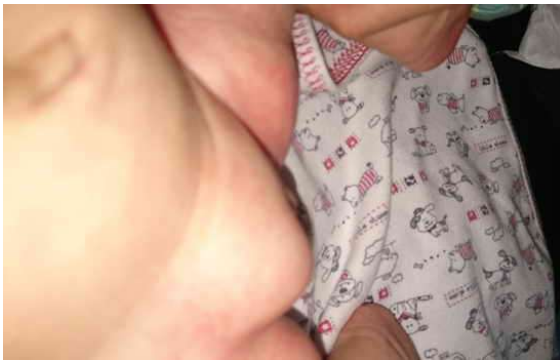Hernia is the protrusion of the small intestines or omentum or other organs through a defect in the abdominal wall. Most common hernias of groin in children are indirect inguinal hernias which occurs because of the persistence of peritoneal extension called processus vaginalis [1]. In mature babies it is seen between 0.8-4.4

% and in premature babies between 16-25%; %60 on right and % 10 bilateral. Boys are six times vulnerable than girls [2]. Typical history is swelling in the groin and the scrotum in boys, or groin and labia majora region in girls. It becomes apparent when the intra-abdominal pressure is increased, like crying or straining; disappears with push or lying. In female infants, an asymptomatic mass at labia majora region or groin is probably a sliding hernia which contains the ovary with or without fallopian tube, with the incidence of % 15-20 [3]. However, a sliding hernia including uterus

is very rare [4]. The sliding hernia is an inguinal hernia in which the retroperitoneal structure "slides" downward from the posterior abdominal wall and directly or indirectly into the inguinal canal, dragging overlying peritoneum with it. Then, the sliding hernias are located behind and outside the peritoneal sac. Ultrasound (US) is the main diagnostic procedure to differentiate groin hernias in infants. We present a 40 day old female infant with indirect inguinal hernia including uterus, both fallopian tubes and ovaries.

### Case report

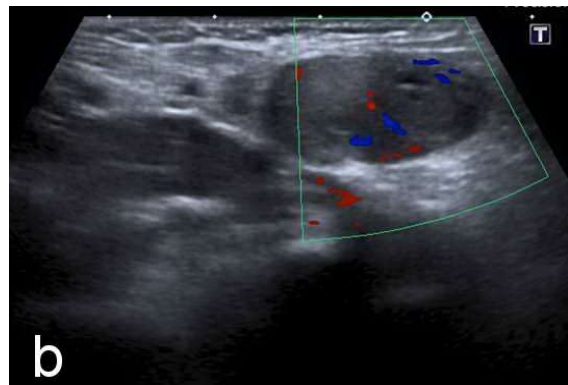
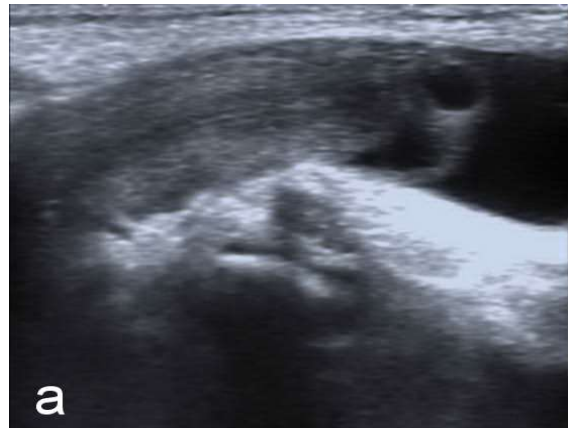40 days old female infant was referred to the pediatric clinic for right inguinal swelling [Fig. 1]. She was a term vaginally delivered baby who had 2700 gr weight, 50 cm height at birth. There was no significant perinatal problem. The family had first recognized the groin swelling two weeks ago. In physical examination there was an irreducible movable mass in her right groin that appeared larger while crying or straining. There was no history of illness, irritability, vomiting.



**Fig. 1.** The appearance of the right inguinal swelling.

The patient was examined with US using a 7.5 MHz transducer (Aplio 500, Toshiba Medical Systems, and Tokyo, Japan). Ultrasonography (US) demonstrated an incarcerated hernia that

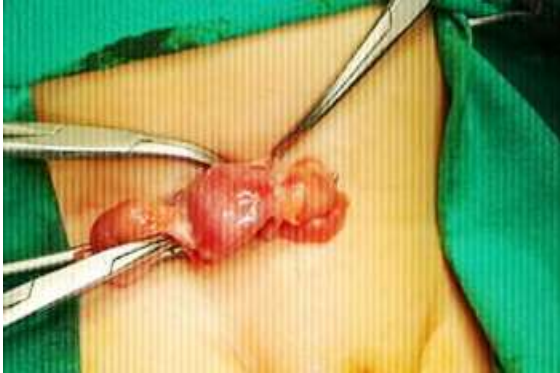passed through the right inguinal canal. It showed a homogeneous structure with a central echoic line and 2x1x1 cm sized oval mass including milimetric hypoechoic cysts suspicious for herniation of the uterus and ovary [Fig. 2a]. There was no visible peristalsis. The sac was not reducible with probe compression. Color Doppler demonstrated vascularity in ovary in order to rule out strangulation [Fig. 2b].



**Fig 2.** a) Oval mass including milimetric hypoechoic cysts suspicious for herniation of the uterus and ovary. b) Color Doppler demonstrated vascularity in ovary.

Since US effectively and satisfactorily determined the content and nature of hernia no further diagnostic examination was performed. A pediatric surgeon was able to reduce the hernia sac manually in emergency service so

that elective surgery planned. A week later hernia occurred again and surgery confirmed the hernia sac containing the uterus, fallopian tube, and both ovaries [Fig. 3].



**Fig. 3.** Intraoperative findings. The hernia sac containing the uterus, fallopian tube, and both ovaries.

Conventional surgical procedure was performed; after freeing the attachment of the fallopian tubes and uterus from the hernia sac and reducing all components back into peritoneal cavity. The hernia sac was high ligated. The postoperative course was uneventful.

### Discussion

Processus vaginalis is evagination of parietal peritoneum and the peritoneal cavity extending into the inguinal canal. In females, the processus vaginalis is accompanied by round ligament of the uterus and passes through the inguinal canal toward the labia majora. Processus vaginalis is relatively small in female infants and obliterates around eight months of gestation. If patency persists, it is termed the canal of Nuck in females [4]. This persistence usually causes hernia of bowels. Ovary or fallopian tube may involve in the hernia sac but uterine herniation is very rare. A few cases are reported. The reason why these organs herniate is still controversial. An

explanation is that, the failure of Mullerian duct fusion may lead to excessive mobility of ovary adnexa and uterus so that they herniate through inguinal canal [5]. Another theory suggests that elongated ovarian suspensory ligaments were the primary cause or the secondary effect of a hernia [6]. Since there may be some anatomical problems with ligaments, these patients must be evaluated in case of infertility when they grow up.

Fascial defect of inguinal hernia never heals without surgery, at any moment there is a risk for strangulation which means the cessation of the circulation of the herniated organ so that it goes to necrosis and gangrene.

Younger the patient's age more the risk of strangulation. Also ovary including inguinal hernias have more risk of incarceration and strangulation [7,4]. For these reasons the treatment of an inguinal hernia is surgery in elective conditions as soon as possible. Here, elective conditions means that the child is ready for undergoing surgery and general anesthesia. In premature infants, the risk of strangulation is higher (31%) and it is recommended not to be sent home from the neonatal intensive care unit without the inguinal hernia repair [8]. In the treatment of sliding hernias, in the previous years, the excision of the entire peritoneal hernia sac and the high ligation of the remaining mass was aimed. Therefore, the treatment was difficult. In a sliding hernia, a portion of the sac is formed by the retroperitoneal organ, and thus the risk of organ injury is high. In current practice, the excision of a sac is not compulsory. Gentle dissection provides tension-free repair as in any inguinal hernia operation. A sliding inguinal hernia can be repaired laparoscopically, but requires significant technical skills. Even in the hands of most experienced laparoscopic hernia

surgeons, open procedural conversion may be required in 10% of all cases [9]. Bevan's surgery was not needed in our case because we were convinced that the sac was tied high enough and the adherence of uterus and adnexa to the sac was minimal.

US should be routinely performed in female infants with an irreducible palpable inguinal mass. US is an effective and available method for diagnosis. Preoperative US using a high-frequency transducer is therefore very helpful in reaching a diagnosis with an efficacy considered to be almost 100%. Slightly probe compression is needed to determine if the hernia is incarcerated or not. However it is not as successful as manual maneuver applied by experienced physician. Color Doppler may help to differentiate strangulation of herniated organs. Inguinal hernias, localized fluid collections or enlarged lymph nodes should be considered in the differential diagnosis [10]. Further examinations such as magnetic resonance imaging may be performed when US is not able to differentiate the content of hernia sac or strangulation. In our case second ovary was not able to be detected on US examination. One possible explanation is the second ovary was behind the uterus or deep in inguinal canal so that we could not see it. Or it probably herniated during the period between US examination and surgery. Anyway it had no significant importance on the procedure of surgery.

In conclusion, a hernia sac containing uterus, fallopian tube, and ovary in female is very rare. When a female infant with groin swelling attends to a pediatric clinic, she must be referred to a radiologist for US examination. The content of the hernia can be diagnosed by the characteristic sonographic appearance. Probe compression may be applied to determine if the hernia is reducible or not.

Color Doppler is useful to show vascularity of ovary. When the diagnosis is certain, the patient must be referred to early elective surgery to prevent the strangulation and necrosis of herniated organs.

### **Compliance with ethical statements**

*Conflicts of Interest:* None.

*Financial disclosure:* None.

*Consent:* All photos were taken with parental consent.

### **References**

- [1] Artas H, Gurbuzer N. Inguinal hernia containing both ovaries and the uterus in an infant. *J Ultrasound Med.* 2012; 31(7):1138-39.
- [2] Walsh SZ. The incidence of external hernias in premature infants. *Acta Paediatr.* 1962; 51: 161-64.
- [3] Cerit KK, Ergelen R, Colak E, Dagli TE. Inguinal hernia containing uterus, fallopian tube, and ovary in a premature newborn. *Case Reports in Pediatrics* 2015, Article ID 807309.
- [4] Cascini V, Lisi G, Di Renzo D, Pappalepore N, Chiesa PL. Irreducible indirect inguinal hernia containing uterus and bilateral adnexa in a premature female infant: report of an exceptional case and review of the literature. *J Pediatr Surg.* 2013;48(1):e17-9.
- [5] Thomson GR. Complete congenital absence of the vagina associated with bilateral hernia of uterus, tubes, and ovaries. *Br J Surg.* 1948;36(141):99-100.
- [6] Fowler CL. Sliding indirect hernia containing both ovaries. *J Pediatr Surg.* 2005;40(9):13-14.
- [7] Ming YC, Luo CC, Chao HC, Chu SM. Inguinal hernia containing uterus and uterine adnexa in female infants: report of

two cases. *Pediatrics and Neonatology*. 2011;52(2):103–105.

- [8]Komorowski AL, Moran RJ, Kazi R, Wysocki WM. Sliding Inguinal Hernias. *Int J Surg*. 2012;10(4):206-208.
- [9]Zorludemir U. Inguino-scrotal Pathologies. *Turk Arch Ped*. 2010;45:23-28.
- [10]Derinkuyu BE , Affrancheh MR , Sönmez D, Koloğlu MB , Fitoz S. Canal of Nuck Hernia in a Female Infant Containing Uterus, Bilateral Adnexa and Bowel. *Balkan Med J*. 2016;33(5):566-68.

Access this article online

<http://pediatricurologycasereports.com>

Quick Response Code

