



## Inguinal microscopic varicocelectomy with spermatic vein - inferior epigastric vein anastomosis in a child with nutcracker syndrome: A case report

Bilge Turedi,<sup>ID</sup> Isik Senkaya Signak<sup>2</sup>, Mehmet Ugur Yilmaz<sup>1</sup>, Fatih Celik<sup>3</sup>, Mehmet Mazhar Utangac<sup>1</sup>, Mehmet Emin Balkan<sup>1</sup>, Nizamettin Kilic<sup>1</sup>

<sup>1</sup>Department of Pediatric Urology Surgery, Uludağ University, Faculty of Medicine, Bursa, Turkey

<sup>2</sup>Department of Cardiovascular Surgery, Uludağ University, Faculty of Medicine, Bursa, Turkey

<sup>3</sup>Department of Pediatric Surgery, Uludağ University, Faculty of Medicine, Bursa, Turkey

### ABSTRACT

Patients with nutcracker syndrome (NCS) associated left varicocele are at high risk of varicocele recurrence when treated only with routine surgical approach for varicocele. An eleven year-old boy who had mild symptoms for NCS and left grade 3 varicocele referred to our clinic. To cure varicocele and to decrease left renal vein pressure, an end to end anastomosis was performed between left spermatic vein and inferior epigastric vein after inguinal microscopic varicocelectomy. His six months follow-up was uneventful. In this case report, we present that this method in children with NCS is a safe and effective method.

**Key Words:** Varicocele, nutcracker syndrome, surgery, children.

© 2020 [pediatricurologycasereports.com](http://www.pediatricurologycasereports.com)

✉ Dr. Bilge Turedi,  
Department of Pediatric Urology Surgery, Uludağ  
University, Faculty of Medicine, Bursa, Turkey  
E mail: [blgtrd@gmail.com](mailto:blgtrd@gmail.com)  
Received: 2020-03-31 / Revisions 2020-04-22  
Accepted: 2020-04-25 / Publication Date: 2020-05-01

### Introduction

The nutcracker phenomenon which is also known as left renal vein entrapment refers to compression of the left renal vein (LRV) between the aorta and the superior mesenteric artery (SMA). This is known as ‘anterior nutcracker’ and when retroaortic or circumaortic renal vein is compressed between aorta and vertebra, it is called ‘posterior nutcracker’ [1]. Nutcracker phenomenon is

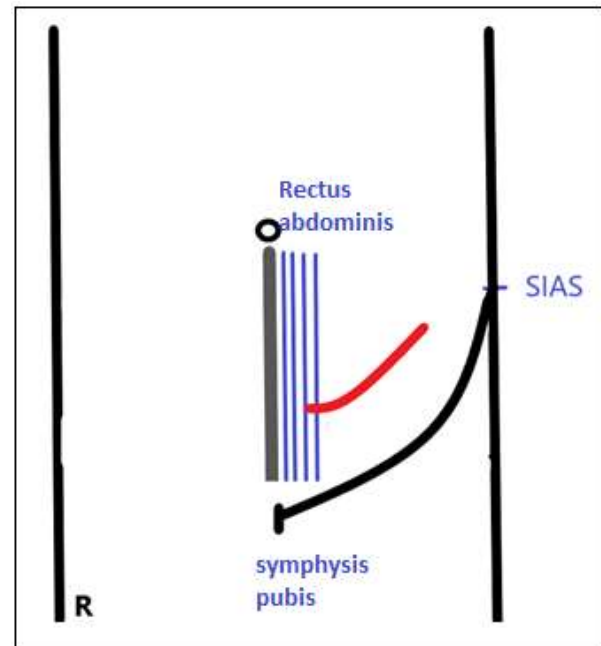
called ‘nutcracker syndrome (NCS)’ when patient has these symptoms with. El Sadr and Mina described the syndrome firstly in 1950 [2]. It can affect a wide age group from childhood to seventh decade of life. Most symptomatic patients are especially in the second or third decade of their life. Distension in the distal part of the vein results in elevated blood pressure in LRV. Increased pressure in LRV leads to hematuria in this syndrome. Orthostatic proteinuria, autonomic dysfunction, chronic fatigue and flank pain are the other symptoms of the disease [3]. There are some different surgical treatment modalities of this syndrome such as nephropexy, SMA transposition, LRV

transposition, gonadocaval shunt and renal autotransplantation [4]. NCS is also associated with left varicocele which affects 9% of men [5]. It is believed that conventional varicocele ligation is ineffective for these patients because of inadequate resolving of the LRV hypertension and most of the patients' symptoms become worse after [6]. So the need for new alternative and effective surgical treatments has been emerged. We aim to present an eleven year-old boy presented with left varicocele secondary to nutcracker syndrome who was treated with inguinal microscopic varicocelectomy and spermatic vein - inferior epigastric vein anastomosis.

### Case report

An 11 year-old boy who had left testicular pain and swelling for 5-6 months referred to our clinic. His physical examination revealed left grade 3 varicocele and decrease in left testicular volume. Other system examinations were normal. Liver function tests, renal function tests, electrolytes and acute phase reactants were within normal limits. Hematuria and proteinuria were detected in urine analyses. Renal vein and scrotal Doppler ultrasonography were compatible with NCS and left varicocele. To cure varicocele and to decrease LRV pressure at the same operation, left spermatic vein- inferior epigastric vein anastomosis was planned additional to inguinal microscopic varicocelectomy.

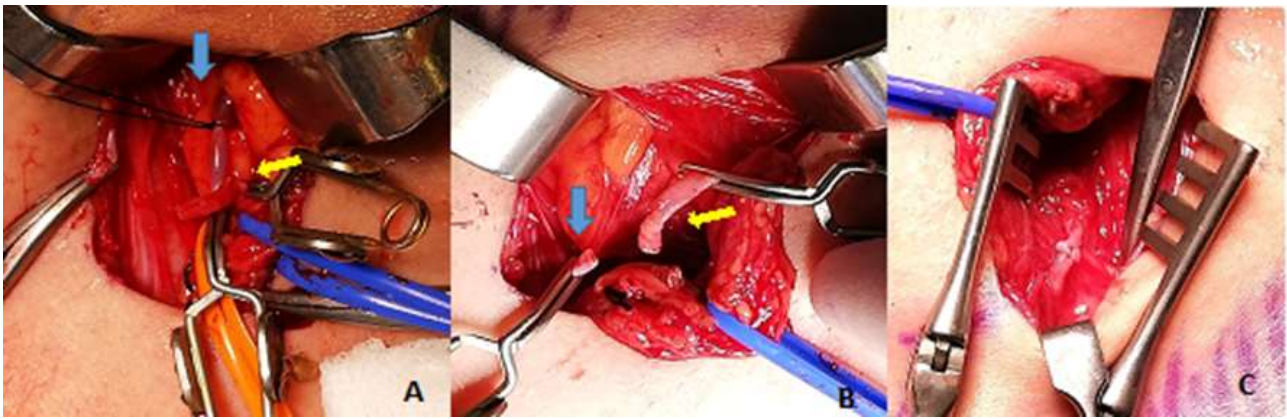
An oblique incision at inferior left quadrant between rectus muscle and anterior superior iliac spine was made (Fig. 1). Firstly inguinal microscopic varicocelectomy was performed. All of dilated veins including external spermatic vein were ligated in the way of protecting artery and lymphatic vessels under microscopic magnification and the most dilated vein was separated for the anastomosis.



**Fig. 1.** Operation incision (an oblique incision was made between lateral side of rectus abdominis and anterior superior iliac spine).

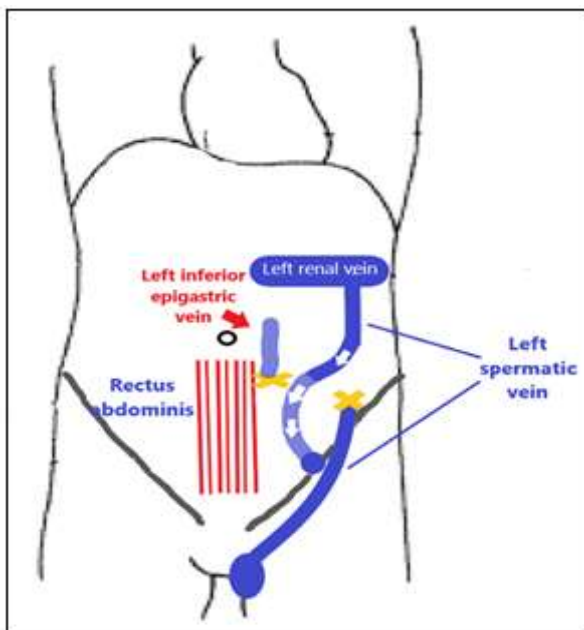
Secondly we detect inferior epigastric vessels behind rectus muscle above the inguinal region at left lower quadrant. It is the anatomical point which we detect epigastric vessels easily. Below this point inferior epigastric vein drains to external iliac vein, so anastomosis should be above this point. The sheath of the rectus abdominis was incised and inferior epigastric vein was separated from inferior epigastric artery. There were no need to use papaverine because the vessel diameters were suitable for anastomosis. Proximal part of left spermatic vein and distal part of the inferior epigastric vein were ligated and bulldog clamps were placed on the other ends which were going to be anastomosed. An end to end anastomosis was performed between left spermatic vein and inferior epigastric vein under loupe magnification (4x) with 9/0 vascular sutures (Fig. 2).

After the completion of anastomosis, bulldog clamps were declamped and blood flow was normal. The schematic drawing of the



**Fig. 2.** (a) Spermatic vein was isolated and proximal portion was clamped and separated for anastomosis (yellow arrow). Inferior epigastric vein was ligated and inferior portion was clamped and separated for anastomosis (blue arrow) (b) Proximal part of left spermatic vein and distal part of inferior epigastric vein was prepared for anastomosis (c) final seen of anastomosis after removing the vascular clips.

performed surgery is shown also in Fig. 3. No vascular leak was detected. There were no intraoperative and postoperative complications. Patient was discharged on postoperative first day. Anticoagulant therapy was not given postoperatively depending on the recommendation of cardiovascular surgery. Control renal vein Doppler ultrasonography for diameters and peak flows which was performed at postoperative first month didn't show any pathological results.



**Fig. 3.** Schematic drawing of the applied surgical procedure.

Kidney function tests, electrolytes, urine analysis were found to be normal, and there was no pathological finding for varicocele on physical examination. His six month follow-up was uneventful. There were no proteinuria or testicular pain recurrence.

### Discussion

The decreased angle between aorta and SMA leads to compression of LRV in patients with NCS. This results in increased pressure in LRV which causes several symptoms such as hematuria, proteinuria and clinical findings such as hypertension and left varicocele. Increased renal vein pressure causes erythrocyte and protein loss from the glomerulus which results in hematuria and proteinuria [5]. Radiological evaluation in this disease are important for diagnosis. Computerized tomography, magnetic resonance imaging and Doppler ultrasonography are usually used. Selective renal venography is the most reliable technique to measure pressure gradient between vena cava inferior and LRV but it is an invasive method for children [7]. Therefore Doppler ultrasonography is more preferred for diagnosis because it is non-invasive and low

cost method [8]. We used Doppler ultrasonography for diagnosis and there were no need for any other radiological examinations.

Symptoms vary in wide range in patients with nutcracker syndrome. Surgical treatment depends on severity of the symptoms. Patients with mild symptoms can be treated conservatively and it may resolve with physical development of the child [9]. For patients with severe symptoms such as significant hematuria and proteinuria, renal function impairment, severe flank pain, there are many surgical methods for correction [10]. Pastershank had firstly reported a patient who was treated surgically in 1974 [11]. The fibrous tunnel was incised and LRV was released in that surgery. Nowadays there are many other surgical methods determined for NCS such a nephropexy, LRV transposition, renocaval by pass [4]. Our case had mild symptoms of NCS so surgical treatment for syndrome itself was not needed. Surgery was performed only for his left varicocele which caused decrease in testicular volume.

Left varicocele occurs with gonadal vein reflux due to increased pressure in LRV. Varicocele affects spermatogenesis and testicular volume in men if it is not operated [12]. NCS associated varicocele should be treated to prevent testicular dysfunction and future infertility. Varicocelectomy should be performed to improve sperm parameters but conventional varicocelectomy techniques may be inadequate for patients with nutcracker syndrome. It may cause an increase pressure in LRV which exacerbates hematuria and proteinuria. Previously described alternative surgical methods are useful to decrease LRV pressure and cure varicocele. Important veins such as mesenteric or iliac veins were used for anastomosis in these methods but they have

high operative and postoperative risks for children [6]. Endoluminal stenting was thought to be minimal invasive for treatment but it couldn't be used widely because of potential risk of pseudointimal perforation [13]. Therefore it was thought that a minimal invasive method with low risk may be useful for patients with nutcracker syndrome. Li et al. presented a study about 5 infertile men with Nutcracker syndrome associated left varicocele who underwent left spermatic-inferior epigastric vein anastomosis. They claimed that it was safe and effective method for infertile men with nutcracker syndrome associated left varicocele [6]. To our knowledge the same technique was performed to pediatric patients firstly and only in the study which was reported by Dong et al [14]. We used the same surgical technique for an 11 year-old patient.

Microsurgical lymphatic sparing varicocelectomy is a useful method for varicocele. Postoperative hydrocele formation and risk of testicular atrophy are minimally seen in this technique. But in other surgical methods which were described previously for nutcracker syndrome associated left varicocele such as spermatic vein ligation for gonadal by pass, there were high risk because of insufficient arterial and lymphatic preservation. So lymphatic sparing varicocelectomy under microscopic magnification is the best technique for varicocelectomy [15]. As it was mentioned in the literature, we firstly performed microscopic varicocelectomy to our patient. No recurrence occurred in his postoperative follow-up.

### **Conclusion**

Our case was operated with spermatic vein-inferior epigastric vein anastomosis for

nutcracker syndrome associated left varicocele. Spermatic vein-inferior epigastric vein anastomosis with inguinal microscopic varicocelectomy can be safe and effective method for children with nutcracker syndrome associated left varicocele. Further results from high numbers of patients who are operated with this method are needed.

### **Compliance with ethical statements**

*Conflicts of Interest:* None.

*Financial disclosure:* None.

*Consent:* Informed and written consent was taken from patient and her parents to publish this case report.

### **ORCID iD of the author (s)**

*Bilge Turedi / 0000-0003-3532-0912*

*Isik Senkaya Sıgnak / 0000-0001-8813-4481*

*Mehmet Ugur Yilmaz / 0000-0003-2468-1333*

*Fatih Celik / 0000-0002-7960-4477*

*Mehmet M Utangac / 0000-0003-2129-0046*

*Mehmet Emin Balkan / 0000-0002-4845-9916*

*Nizamettin Kiliç / 0000-0003-2931-1227*

### **References**

- [1]Ali-El-Dein B, Osman Y, Shebab El-Din AB, et al. Anterior and posterior nutcracker syndrome: a report on 11 cases. *Transplant Proc.* 2003; 35(2): 851-53.
- [2]El-Sadr AR, Mina E. Anatomical and surgical aspects in the operative management of varicocele. *Urol Cutan Rev.*1950; 54(5): 257-62.
- [3]Wendel RG, Crawford ED, Hehman KN. The "nutcracker" phenomenon: an unusual cause for renal varicosities with hematuria. *J Urol.* 1980; 123(5): 761-63.
- [4]Gong XY, Zheng W, Du H, et al. Treatment of nutcracker syndrome with spermatic vein ligation and iliac vein anastomosis: case report of three cases. *Asian Pac J Trop Med.* 2012; 5(11): 923-24.
- [5]Kurlinsky AK, Rooke TW. Nutcracker Phenomenon and Nutcracker Syndrome. *Mayo Clin Proc.* 2010; 85(6): 552-59.
- [6]Hai Li, Zhang M, Jiang Y, et al. Microsurgical spermatic –inferior epigastric vein anastomosis for treating nutcracker syndrome-associated varicocele in infertile men: a preliminary experience. *Urology.* 2014; 83(1): 94-99.
- [7]Kim WS, Cheon JE, Kim IO, et al. Hemodynamic investigation of the left renal vein in pediatric varicocele: Doppler US, venography, and pressure measurements. *Radiology.* 2006; 241(1): 228-34.
- [8]Takebayashi S, Ueki T, Ikeda N, et al. Diagnosis of the nutcracker syndrome with color doppler sonography: correlation with flow patterns on retrograde left renal venography. *AJR Am J Roentgenol.* 1999; 172(1): 39-43.
- [9]Alaygut D, Bayram M, Soylu A, et al. Clinical course of children with nutcracker syndrome. *Urology.* 2013; 82(3): 686-90.
- [10]Hohenfellner M, D'elia G, Hampel C, et al. Transposition of the left renal vein for treatment of the nutcracker phenomenon: long term follow-up. *Urology.* 2002; 59(3): 354-57.
- [11]Pastershank SP. Left renal vein obstruction by a superior mesenteric artery. *J Can Assoc Radiol.* 1974; 25(1): 52-54.
- [12]Li F, Yue H, Yamaguchi K, et al. Effect of surgical repair on testosterone production in infertile men with varicocele: a meta-analysis. *Int J Urol.* 2012;19(2): 149-54.
- [13]Segawa N, Azuma H, Iwamoto Y, et al. Expandable metallic stent placement for nutcracker phenomenon. *Urology.* 1999; 53(3): 631-33.

- [14] Dong W, Yao Y, Huang H, et al. Surgical management of nutcracker phenomenon presenting as left varicocele in adolescents: a novel approach. *J Pediatr Urol.* 2014; 10(3): 424-29.
- [15] Silveri M, Adorisio O, Pane A, et al. Subinguinal microsurgical ligation – its effectiveness in pediatric and adolescent varicocele. *Scand J Urol Nephrol.* 2003; 37(1): 53-54.