



## Is Every Stone Urinary Stone? A Rare Case of Stone

Ali Gunes, Ibrahim Uygun

**Abstract** Primary vaginal stones in children are extremely rare medical condition but important because they are often mistaken for urinary stones. Here, we present the case of an 11-year-old girl with multiple vaginal stones.

**Key Words** Vaginal stone; urolithiasis; urinary stone; struvite stone.

© 2014 pediatricurologycasereports.com. All Rights Reserved

### Introduction

Primary vaginal stones in children are extremely rare but important because they are often mistaken for urinary stones [1–4]. They can be primary or secondary. Primary vaginal stones are formed from deposition of urinary salts. Secondary stones are more common and formed around foreign body in the vagina as with surgical sutures or forgotten material placed in vagina. Here, we present the case of a girl with multiple vaginal stones.

*From the Department of Pediatrics and Pediatric Surgery, Faculty of Medicine, Dicle University, Diyarbakir, Turkey*

#### **Corresponding Author:**

*Ibrahim Uygun, MD, Assoc. Prof. Dicle University, Faculty of Medicine, Department of Pediatric Surgery and Pediatric Urology, 21280, Diyarbakir, Turkey. E-mail: iuygun@hotmail.com*

*Accepted for publication 28 February 2014*

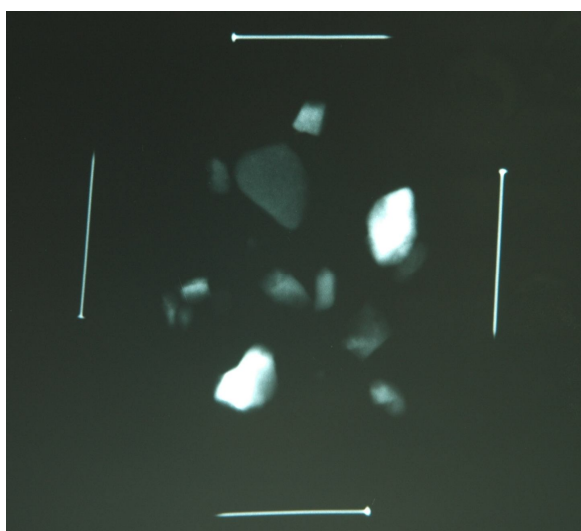
### Case Report

An 11-year-old girl was admitted with complaints about recurrent spontaneous passage of stone and abdominal pain for 4 months. She had a bottle within multiple stones the biggest of which was 1.5 cm diameter (Fig. 1). She had been investigated wholly in three centers and then the patient and her mother had not been



**Fig. 1.** Multiple stones passed spontaneously from vagina.

believed there and they had been transferred to psychiatry service. Her physical examination revealed only that the hymen was annular and wide vaginal orifice had a granular gray secretion. We told to her mother to be careful about where the stones will pass; from urethra or vagina. Biochemical and urine analyses, intravenous urography, ultrasonography, magnetic resonance imaging, and voiding cystourethrography were normal. Meanwhile, one day, her mother had pulled a stone out from her vaginal orifice while it was passing. By cystoscopy and vaginography, there was no fistula. Vaginoscopy revealed massive granular gray secretion, thus, vagina was washed out. In the plain X-ray, her multiple vaginal stones were radio-opaque (Fig. 2).



**Fig. 2.** Multiple vaginal stones were radio-opaque in plain X-ray.

Chemical analysis of the stones revealed struvite (magnesium ammonium phosphate). From the cut sections of the stones, there was no evidence of a foreign body or nidus. Vaginal wash out and voiding exercises were advised. Currently, she is doing well with no stone recurrence at 10-years follow-up.

### **Discussion**

Primary vaginal stones in children are extremely rare medical condition but important because they are often mistaken for urinary stones, and are always of urinary origin and usually formed by deposition of urinary salts (struvite) as a result of chronic pooling of urine in the vagina [1–4]. Primary vaginal stones can be associated with urinary-vaginal fistula, ectopic vaginal ureter, imperforate hymen, partial vaginal outlet obstruction or neurogenic bladder with urinary incontinence [1–7]. But in the present case, we postulate that the stones were formed as a consequence of retrograde filling of the vagina with urine in association with annular hymen and wide vaginal orifice.

Every lithiasis is not urolithiasis. We must be careful that primary vaginal stones might often be mistaken for urinary stones.

### **CONFLICT OF INTEREST**

**None declared.**

**References**

1. Petrillo CR, Borelli M, Botelho C. Primary vaginal calculus in a patient with meningomyelocele. *Arch Phys Med Rehabil.* 1981;62:227–9.
2. Yoshimura T, Nagata Y, Matsuura K, Okamura H. Primary vaginal stone in an 11 year old recumbent girl. *Gynecol Obstet Invest.* 2000;50:64–6.
3. Cetinkursun S, Surer I, Demirbag S, Ozturk H. A primary vaginal stone in a disabled child. *Obstet Gynecol.* 2001;98:978–9.
4. Liu B, Huang X, Lu J, Zhang Z, Wang P, Huang Z. Vaginal calculi secondary to urethrovaginal fistula with vaginal stenosis in a 14-year-old girl. *Urol Res.* 2008;36:73–5.
5. Oguzkurt P, Ince E, Ezer SS, Temiz A, Demir S, Hicsonmez A. Primary vaginal calculus secondary to urethrovaginal fistula with imperforate hymen in a 6-year-old girl. *J Pediatr Surg.* 2009;44:e11–3.
6. Jaspers JW, Kuppens SM, van Zundert AA, de Wildt MJ. Vaginal stones in a 5-year-old girl: a novel approach of removal. *J Pediatr Adolesc Gynecol.* 2010;23:e23–5.
7. Chen S, Ge R, Zhu L, Yang S, Wu W, Yang Y, Tan J. Giant primary vaginal calculus secondary to vesicovaginal fistula with partial vaginal outlet obstruction in a 12-year-old girl. *Urology.* 2011;78:908–10.