



PEDIATRIC UROLOGY CASE REPORTS

ISSN 2148-2969

<http://www.pediatricurologycasereports.com>**Left total ureteral substitution using appendix after failed ureteral reimplantation, in infant affected by high vesico-ureteral reflux in a left functionally solitary kidney****Marianna Iaquinto¹, Emilio Vittorio Merlini², Barbara Tadini², Giovanni Palazzo³, Antonio Fonzone Caccese³, Roberto De Castro¹**¹ Department of Urologic and Pediatric Surgery, "Prof. Petrucciani" Clinic, Lecce, Italy² Department of Pediatric Urology – "Regina Margherita" Hospital, Torino, Italy³ Department of Pediatric Urology - A.O.R.N. Santobono-Pausilipon, Napoli, Italy**ABSTRACT**

A ureteric loss is a devastating event and can be corrected with intrinsic urinary tissue using different surgical techniques such as direct anastomosis, psoas hitch, Boari flap, transuretero-ureterostomy and renal autotransplantation. We report a case of successful left ureter total substitution with appendix after failed ureteral reimplantation and acute renal failure, in an infant affected by high grade vesicoureteral reflux in a left functionally solitary kidney.

Key Words: Left total ureteral substitution; appendix; solitary kidney.

Copyright © 2018 [pediatricurologycasereports.com](http://www.pediatricurologycasereports.com)

Corresponding Author:

Dr. Marianna Iaquinto

Department of Urologic and Pediatric Surgery, "Prof. Petrucciani" Clinic, Lecce, Italy

E mail: i.marianna@hotmail.it

ORCID ID: <https://orcid.org/0000-0003-2185-4470>

Received 2018-09-04, Accepted 2018-10-04

Publication Date 2018-11-01

Herein a successful, uncommon case of left ureteric total substitution with appendix is presented.

Case report

A baby-girl, with prenatal diagnosis of right multicystic dysplastic kidney (MCDK) was investigated by pediatric nephrologist. High left vesicoureteral reflux (VUR) (grade IV), with a good compensatory left kidney, was diagnosed and conservatively managed with antibiotic prophylaxis. When 2-year-old, because of persistence of high VUR, endoscopic treatment was offered and carried out. Patient was discharged on 1st post-operative day (POD) with antibiotic therapy. On 3th POD, she was readmitted in urgency because of severe urinary tract obstruction (UTO) and acute renal failure (ARF) (creatinine 6.7 mg/dl, urea 170 mg/dl).

Introduction

Congenital or acquired defects of the ureter are usually repaired with intrinsic urinary tissue using different surgical techniques such as direct anastomosis, psoas hitch, Boari flap, transuretero-ureterostomy and renal autotransplantation. However, when the loss of ureteral tract is significant, full or partial replacement of the ureter is required. Total ureteric replacement in pediatric age is rare and experience is limited in this field [1-5].

Ultrasound (US) study showed left hydroureteronephrosis (antero-posterior pelvic diameter 22 mm, ureteral diameter 10 mm). After failure of endoscopic JJ stent introduction, trans-trigonal left ureteral reimplantation was performed. The child had an immediate clinical improvement (creatinine 1.6 mg/dl, urea 68 mg/dl). On 4th POD, UTO and ARF (creatinine 2.9 mg/dl, urea 100 mg/dl) occurred again and a salvage left loop-ureterostomy was carried out with a gradual clinical normalization (creatinine 0.5 mg/dl, urea 23 mg/dl). Monthly assessment showed a good renal function and a good quality of the ureterostomy. Six months later, an undiversion was performed with Politano-Leadbetter left ureteral reimplantation of the short proximal ureter together with psoas hitch. On 10th POD, after JJ stent removal, UTO and ARF occurred again and percutaneous nephrostomic J catheter was inserted. Nephrostogram showed no contrast in the ureter. Abdominal Computerized Tomography (CT) scan, with angiographic study of renal vessels, showed normal origin and course of left renal artery. Pathogenesis of these pathological sequences was uncertain, however there was a clear need for ureteral substitution.

The availability of a cecal long appendix and well supported by a manageable mesentery allowed its use. The cecum and the ascending colon were mobilized. The assessment of the

appendix revealed a 6 cm in length and a macroscopic normal organ. The isolated appendix, retroperitoneally transferred, was interposed in an antiperistaltic fashion between the renal pelvis (pelvis-appendix tension-free end-to-end anastomosis) and bladder (reimplantation on the bladder dome according Lich Gregoire). A JJ stent was placed before completing the anastomosis [Fig 1A-C]. Procedure and post-operative were uneventful. A radiological examination on 10th POD showed no signs of leakage or stenosis and a good passage of contrast in the bladder [Fig 2]. The JJ stent was removed after 4 months; intraoperative radiological examination showed right VUR (grade II-III) and no signs of appendix stenosis. At hospital discharge, biology (creatinine 0.3 mg/dl) and imaging [Fig. 3] were normal; antibiotic prophylaxis was stopped. At about 10 months after the surgery a videourodynamic testing (bladder with low compliance and irregular profile, bilateral VUR, presence of post-voiding residue), lumbar-sacral magnetic resonance (normal) and US study (left pelvis dilatation of 20 mm) were performed.

The patient was started on clean intermittent catheterization (CIC) through the urethra and oxybutinin treatment.

At last follow-up (13 months after the surgery) we report only one urinary tract infection, a regular CIC, an improved US study (left pelvis dilatation of 15 mm), a normal renal function.

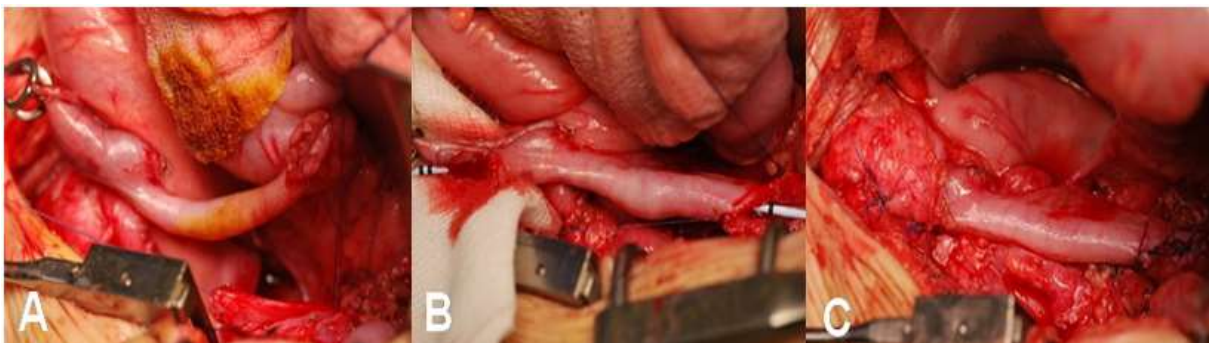

Fig. 1A-C. Appearance intraoperative of left total ureteral substitution with appendix.

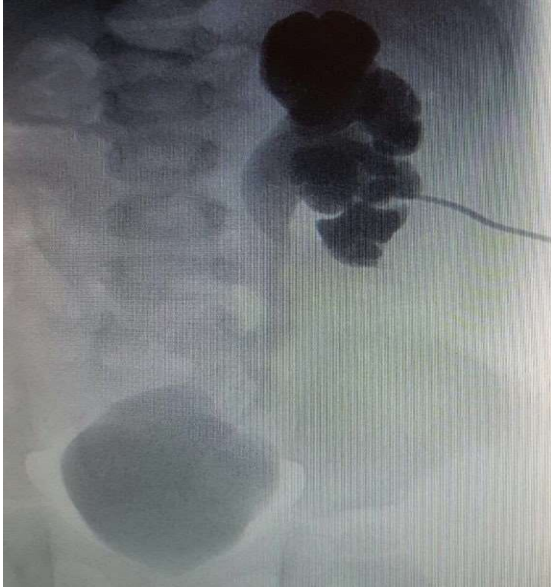


Fig. 2. A radiological examination on 10th POD showed no signs of leakage or stenosis and a good passage of contrast in the bladder.

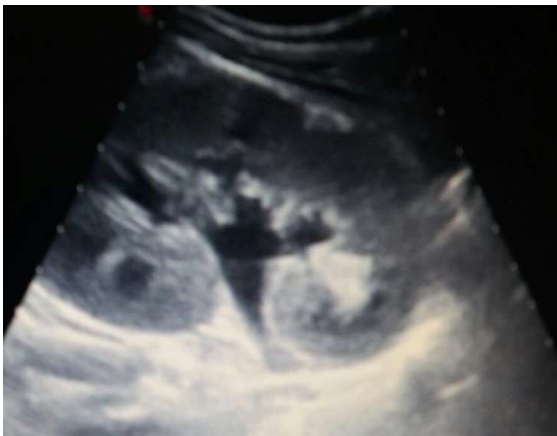

Fig. 3. At hospital discharge, normal ultrasonography imaging.

Discussion

Ureteral loss is a serious clinical problem for kidney survival and may cause inflammation, tumor, trauma, radiation damage, or retroperitoneal fibrosis [1,2]. Ureteric injury is a potential complication of any open abdominal surgery, laparoscopy and ureteroscopy. In the largest review by Dagash et al. 60% of pediatric patients who needed an ureteral substitution, suffered from

postoperative complications after pyeloplasty and ureteral reimplantation [3].

Ureteric defects or loss can be corrected with intrinsic urinary tissue using different surgical techniques such as direct anastomosis, psoas hitch, Boari flap, transuretero-ureterostomy and renal autotransplantation. However, when the loss of ureteral tract is significant, full or partial replacement of the ureter is required [4]. The extra urinary tissue most commonly used is intestine (ileum, colon, appendix). The use of ileal or colic segment as a ureteral substitute has some disadvantages such as hyperchloremic metabolic acidosis, urolithiasis and excess mucus production, tumor formation. In addition, an enlarged refluxing ileal / colic ureter due to progressive dilatation is the cause of functional obstruction and recurrent urinary tract infection (UTI) [5,6].

Since Melnikoff first used appendicitis as a ureteral substitute in 1912 [7], several case reports and small series have been published, mostly in adults. However, experience in pediatric patients is very limited. Satisfying ureteral substitution with appendix in adults and children involving the right ureter, pyeloureterostomy and for bridging the right renal pelvis to the left ureter has been showed. In addition, it should be noted that the length of the appendix and mesoappendiks may pose a problem in changing the left ureter [8-17]. The appendix is an organ which is approximately 8 Fr in diameter, with an irregularly lumen and the blood supply arises from the appendicular artery. Histologically, the appendiceal muscle wall has a circular orientation, and its peristalsis is from the base to the tip.

Compared to the ileum and colic segments, it provides several advantages: suitable caliber/length ratio, little tendency to dilation over time, caliber and structure comparable

with ureteral ones, exclusive vascularization, good contractility, reduced mucosa surface and negligible reabsorption of urinary electrolytes, easy removal with no need for intestinal anastomosis and the possibility of creating a submucosal tunnel into the bladder to prevent reflux [4, 18-19].

Limitations to use of the appendix include inadequate length (sometimes only 2 cms), previous inflammation or appendectomy, missing length and a short mesoappendix [4, 8, 14-16]. Some authors suggest interposition of the appendix isoperistaltically to favor the urine flow with the peristalsis of the appendix [20], while, others reported that reverse (antiperistaltic) interposition had no immediate consequences on urine flow from the upper excretory tract but reduces the risks of ischemia secondary to a kinking of the appendicular meso during its rotation when the appendix is isoperistaltically interposed [8,20]. In our case, three important technical points in using the appendix have been: its manageability (good length, macroscopically normal, an enough long vascular pedicle); its antiperistaltic interposition to reduce the risks of ischemia; the necessity of adequate mobilization to achieve a tension-free anastomosis.

Conclusions

A successful, uncommon case of left ureteric substitution with appendix is presented. On the basis of our experience appendix, when available and normal, is suitable for ureter substitute. This may be true, with encouraging results, also on the left side when a favorable organ is present together with a long vascular pedicle. Although, larger series and longer follow-up are necessary. More cases and longer follow-up are needed to designate

appendix as possible ideal option for total substitution of left ureter.

Compliance with ethical statements

Conflicts of Interest: None.

Financial disclosure: None.

Consent: All photos were taken with parental consent

References

- [1]Ali-el-Dein B, Ghoneim MA. Bridging long ureteral defects using the Yang-Monti principle. *J Urol.* 2003; 169(3):1074-77.
- [2]Selzman AA, Spirnak JP. Iatrogenic ureteral injuries: a 20-year experience in treating 165 injuries. *J Urol.* 1996; 155(3):878-81.
- [3]Dagash H, Sen S, Chacko J, Karl S, Ghosh D, Parag P et al. The appendix as ureteral substitute: a report of 10 cases. *J Pediatr Urol.* 2008; 4(1):14-19.
- [4]Antonelli A, Zani D, Dotti P, Tralce L, Simeone C, Cunisco SC. Use of the appendix as ureteral substitute in a patient with a single kidney affected by relapsing upper urinary tract carcinoma. *Scientific World Journal.* 2005; 5:276-79.
- [5]Verduyck FJ, Heesakkers JP, Debruyne FM. Long-term results of ileum interposition for ureteral obstruction. *Eur Urol.* 2002; 42(2): 181-87.
- [6]Bonfig R, Gerharz EW, Riedmiller H. Ileal ureteric replacement in complex reconstruction of the urinary tract. *BJU Int.* 2004; 93(4): 575-80.
- [7]Melnikoff AE. About ureteral replacement with isolated small bowel. *Rev Clin Urol.* 1912; 1:601.
- [8]Estevao-Costa J. Autotransplantation of the vermiform appendix for ureteral substitution. *J Pediatr Surg.* 1999; 34(10): 1521-23.

- [9]Die Goyanes A, Garcia Villanueva A, Lavalle Echavarria JA, Cabanñas Navarro L. Replacement of the left ureter by autograft of the vermiform appendix. *Br J Surg.* 1983;70(7):442-43.
- [10]Mesrobian HG, Azizkhan RG. Pyeloureterostomy with appendiceal interposition. *J Urol.* 1989;142(5):1288-9.
- [11]Weinberg RW. Appendix ureteroplasty. *Br J Urol.* 1976; 48(4): 234.
- [12]Martin LW. Use of the appendix to replace a ureter. Case report. *J Pediatr Surg.* 1981; 16(6): 799–800.
- [13]Thomas A, Eng MM, Hagan C, Power RE, Little DM. Appendiceal substitution of the ureter in retroperitoneal fibrosis. *J Urol.* 2004; 171(6 Pt 1): 2378.
- [14]Obaidah A, Mane SB, Dhende NP, Acharya H, Goel N, Thakur AA et al. Our experience of ureteral substitution in pediatric age group. *Urology.* 2010; 75(6):1476-80.
- [15]Jang TL, Matschke HM, Rubenstein JN, Gonzalez CM. Pyeloureterostomy with interposition of the appendix. *J Urol.* 2002;168(5):2106-7.
- [16]Richter F, Stock JA, Hanna MK. The appendix as right ureteral substitute in children. *J Urol.* 2000;163(6):1908-12.
- [17]Springer A, Reck CA, Fartacek R, Horcher E. Appendix vermiformis as a left pyelo-ureteral substitute in a 6-month-old girl with solitary kidney. *Afr J Pediatr Surg.* 2011; 8(2):218-20.
- [18]Yoon BI, Hong CG, Kim S, Ha US, Chung JH, Kim SW, et al. Ureteral substitution using appendix for a ureteral defect caused by a retroperitoneal rhabdomyosarcoma in a child. *Korean J Urol.* 2014;55(1):77-79.
- [19]Zargar MA, Mirzazadeh M, Zargar K. The appendix, an acceptable substitute for all segments of both ureters: a report of two cases. *Med J Islam Repub Iran.* 2004; 18(2): 177-180.
- [20]Goldwasser, B., Leibovitch, I., and Avigad, I. Ureteral substitution using the isolated interposed vermiform appendix in a patient with a single kidney and transitional cell carcinoma of the ureter. *Urology.* 1994; 44(3): 437–40.

Access this article online

<http://pediatricurologycasereports.com>

Quick Response Code

