


**PEDIATRIC UROLOGY CASE REPORTS**

ISSN 2148-2969

<http://www.pediatricurologycasereports.com>**Malignant peripheral nerve sheath tumor (Schwannoma) of the dorsal penis: A case report and review of the literature****Ruankha Bilommi***Department of Pediatric Surgery, Mitra Keluarga Group General Hospital, YARSI Medical Faculty, Jakarta***ABSTRACT**

Malignant peripheral nerve sheath tumors (MPNST) are rare, aggressive soft tissue sarcomas arising from peripheral nerves that present great challenges to known treatment modalities. Here, we present a case of MPNST involving the dorsum of a penis in a 13-month-old boy. The mass was incompletely excised and a circumcision was performed. Histological study revealed spindle cell tumor of the lesion. Immunohistochemistry showed a strong positive staining for tumor cells. A high grade malignant peripheral nerve sheath tumor was diagnosed.

Key Words: Penile neoplasm, penis, malignant peripheral nerve sheath tumor, schwannoma.

Copyright © 2019 [pediatricurologycasereports.com](http://www.pediatricurologycasereports.com)

Correspondence: Dr. Ruankha Bilommi

Department of Pediatric Surgery, Mitra Keluarga Group General Hospital, YARSI Medical Faculty, Jakarta, Indonesia

E mail: rbilommi@gmail.com

ORCID ID: <https://orcid.org/0000-0001-9527-9929>

Received 2019-05-14,

Accepted 2019-06-28, Publication Date 2019-09-01

schwannoma, is rarest in childhood and there are four cases reported in the pediatric age group [1,5,6]. Here, we reported a case of a 13-month-old boy presenting with painless masses on the dorsal aspect of the penile shaft, the first report from Indonesia.

Introduction

Malignant peripheral nerve sheath tumors (MPNSTs) are a rare type of cancer that occurs in the lining of the nerves that extend from the spinal cord into the body, accounting for approximately 5-10% of all soft tissue sarcomas [1-4]. They tend to cause pain and weakness in the affected area and may also cause a growing lump or mass. MPNST is also an aggressive neoplasm in which local recurrence is common and complete excision of the mass should be the goal of surgery [1-5]. A high grade MPNST, malignant

Case report

A previously healthy 13-month-old boy was evaluated for swelling in the dorsal penis and suprapubic area for two weeks. At first, parents thought that their children had inguinal hernia. Therefore, they came to the pediatric surgery clinic and requested a herniorrhaphy procedure. The patient's physical examination showed that the hard masses in the dorsal penis extend to the suprapubic area and scrotal area (Fig. 1).

We performed abdominopelvic ultrasonography (US) and

computed tomography (CT) scan that shows solid tumor at the dorsal penis and suprapubic region. An ultrasound of the mass revealed a heterogeneous solid mass centered near on the dorsal aspect of the penile shaft. Further evaluation by CT study showed a heterogeneous density mass on the coronal plan CT image that erased the right muscle planes and reached into the pelvis and pushed into the bladder (Fig. 2).

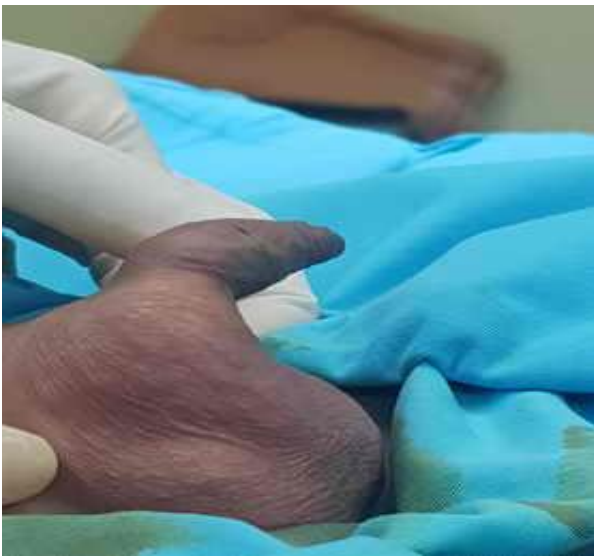

Fig. 1. Dorsal penile mass extending to the suprapubic and scrotum region.

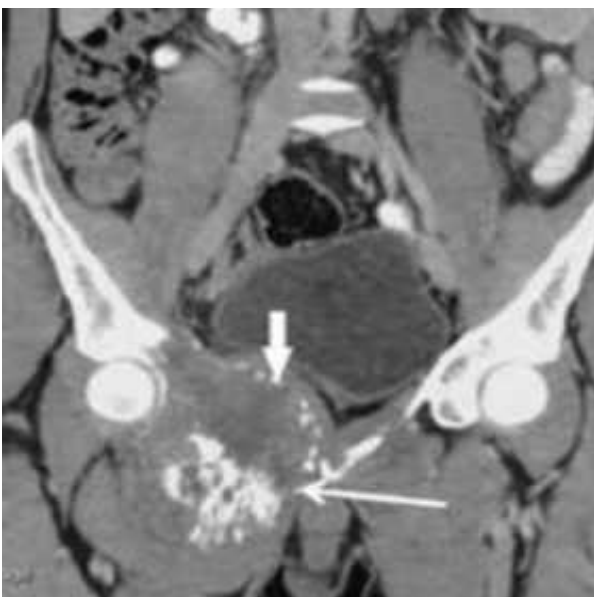

Fig. 2. Coronal plan CT image of the mass with heterogeneous density.

Incomplete surgical excisions were performed, macroscopically the sample was measured 3.2 cm x 4 cm x 3 cm and we also performed dorsal circumcision (Fig. 3).

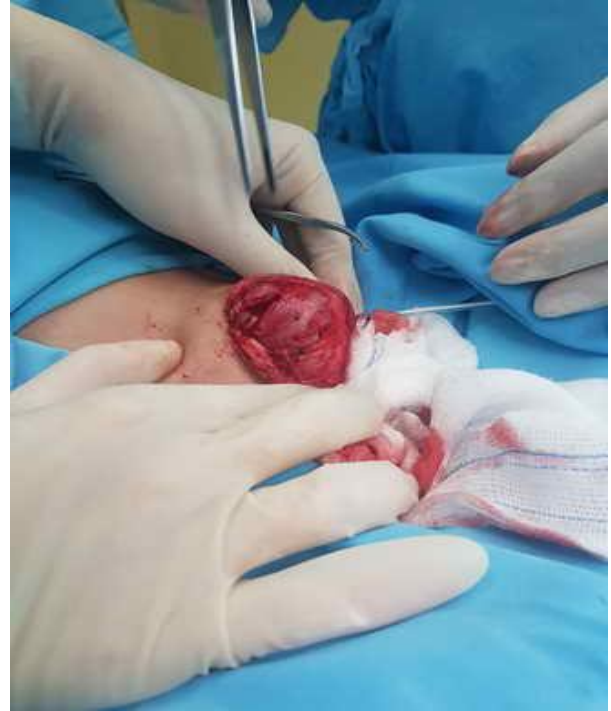

Fig. 3. Intraoperative view of the mass.

The mass originated from the right penile neuro-vascular bundle, invaded the right tunica albuginea and corpus cavernosum, and draped over the dorsal penis. The urethra and bilateral spermatic cords were preserved. The parents did not allowed for penectomy. Given the patient's comorbidities, maximum excision of the tumor for palliation while maintaining minimum penile anatomy was performed with right erectile body reconstruction and scrotoplasty.

Histopathological examination of the lesion revealed spindle cell tumor (Fig 4.) Immunohistochemical study with S100 and vimentin showed that it was strongly positive for the diagnosis of high grade malignant peripheral nerve sheath tumor. He had no family history of von Recklinghausen's neurofibromatosis (VRN). The surgery is

followed by post-operative radiotherapy and adjuvant chemotherapy, the patient now had done first round of chemotherapy and will continue.

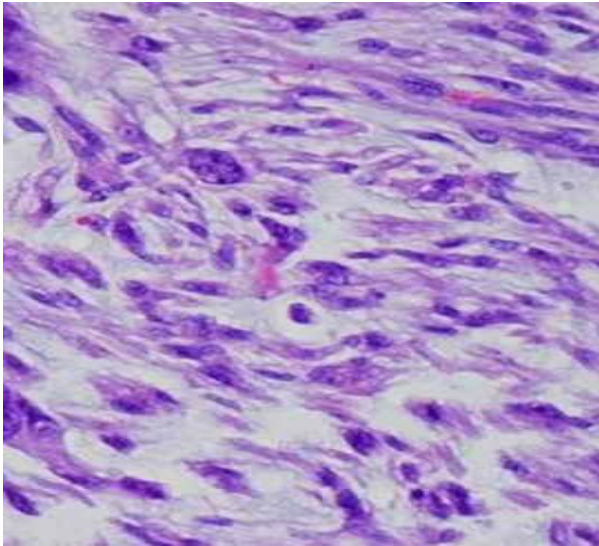


Fig. 4. Histology, spindle cell tumor (H&Ex400).

Discussion

Malignant peripheral nerve sheath tumors (MPNSTs) are rare aggressive soft tissue sarcomas originating from peripheral nerve fibers such as Schwann cells, perineural cells or fibroblasts. In addition to the above features of these tumors, complete excision of the mass is important for the success of the treatment since local recurrence of the tumor is common [1,5,6]. The management of penile MPNST is particularly difficult due to the limited number of cases reported in the literature and the variability in surgical, chemotherapy and radiation combinations [1,5,7]. In the literature, penile MPNST was described in only 4 pediatric patients, 2 of which were associated with NF1. Here we present a 13-month-old boy with 5th penile MPNST (Table 1) [1,5,6].

Table 1. Reported pediatric cases of penile MPNST in the current literature [1,5,6].

Author (year)	NF1	Age at diagnosis (years)	Size (cm)	Location	Treatment	Outcome
Dehner (1970)	Yes	15	4.0	Prepuce, glans	Partial excision	Lost to follow-up
Dehner (1970)	Yes	2	2.5	Dorsal shaft	Excision	Recurrence (4x) at same location in 2 years
Mortell (2007)	No	3	1.3 × 0.7 × 0.4	Dorsal shaft	Excision with positive margins -re-resection at 3 months	-Local recurrence (2x) & resection (2x) at 4 and 4.5 years - No recurrence at 5.5 years
Parekh (2013)	No	14 months	5.4 × 3.7 × 3.8	Base of penis	-Chemotherapy -Total penectomy - Radiotherapy	No recurrence or metastasis at 9 months
Current case	No	13 month	3.2 x 4 x 3	Dorsal shaft	-Incomplete surgical excision -Chemotherapy -Radiotherapy	-No recurrence in early period

In cases with penile MPNST, 60.0% of the lesions are located in the dorsal aspect of the penis and 43.3% are located on the penis body or shaft. Patients may present with a single nodule (66.7%) or multiple nodules (33.3%), and the lesions are usually painless [8].

Because of the lack of standardized diagnostic criteria, it is difficult to diagnose MPNST. First of all, MPNST should be considered in any patient with a rapidly growing or painful mass. US, CT and magnetic resonance imaging with NF1 evaluation are diagnostic tools for the preoperative evaluation of peripheral nerve sheath tumors and exclusion of metastases [1,6].

In the surgical treatment of MPNST, the priority is to completely remove the lesion. The rate of surgical excision varies between 20% and 95% of the complete excision, primarily depending on the location of the tumor [9]. In some challenge cases, however, the disability of surgical treatment should be considered [9]. In addition, the efficacy of chemotherapy regimens is not complete, and radiation therapy may be useful only for minimum residual disease [10]. Thus, current and other reports suggest that treatment options for MPNSTs are limited when complete surgical excision is not achieved.

Conclusion

Although rare, MPNSTs are a highly aggressive soft tissue sarcomas requiring rapid diagnosis and surgical excision. For these patients, adjuvant radiation and chemotherapy or targeted therapy are other useful additional potential therapeutic approaches. In addition, the penile localization of the tumor poses anatomical and functional challenge for all sides.

Compliance with ethical statements

Financial disclosure: None.

Consent: All photos were taken with parental consent.

Acknowledgement

This study was presented at the 30th ESPU Congress (S2-5, 30th ESPU Congress - 2019 - Lyon, France).

References

- [1]Mortell A, Amjad B, Breatnach F, Devaney D, Puri P. Penile malignant peripheral nerve sheath tumour (schwannoma) in a three-year-old child without evidence of neurofibromatosis. *Eur J Pediatr Surg.* 2007;17(6):428-30.
- [2]Carli M, Ferrari A, Mattke A, Zanetti I, Casanova M, Bisogno G, et al. Pediatric malignant peripheral nerve sheath tumor: the Italian and German soft tissue sarcoma cooperative group. *J Clin Oncol.* 2005;23(33):8422-30.
- [3]Ferner RE, Gutmann DH. International consensus statement on malignant peripheral nerve sheath tumors in neurofibromatosis. *Cancer Res.* 2002;62(2): 1573-77.
- [4]Wong WW, Hirose T, Scheithauer BW, Schild SE, Gunder-son LL. Malignant peripheral nerve sheath tumor: Analysis of treatment outcome. *Int J Radiat Oncol Biol Phys.* 1998;42(2): 351-60.
- [5]Dehner LP, Smith BH. Soft tissue tumors of the penis: A clinicopathologic study of 46 cases. *Cancer.* 1970;25(6): 1431-47.
- [6]Parekh N, Cockrell E, McMahan D. Malignant peripheral nerve sheath tumor of the penis: a case report and review of the literature. *Urology.* 2013;81(5):1067-68.
- [7]Djahangirian O, Ngoc-Anh T, Torno L, Khoury A. Case of penile malignant

peripheral nerve sheath tumor in a twenty-year-old male with Neurofibromatosis type 1. *Int Arch Urol Complic.* 2018;4(2):1-4.

[8] Nguyen AH, Smith ML, Maranda EL, Punnen S. Clinical Features and Treatment of Penile Schwannoma: A Systematic Review. *Clin Genitourin Cancer.* 2016; 14(3):198-202.

[9] Bilgic B, Ates LE, Demiryont M, Ozger H, Dizdar Y. Malignant peripheral nerve sheath tumors associated with neurofibromatosis type 1. *Pathol Oncol Res.* 2003;9(3):201-5.

[10] Ducatman BS, Scheithauer BW, Piegras DG, Reiman HM, Ilstrup DM.

Malignant peripheral nerve sheath tumors. A clinicopathologic study of 120 cases. *Cancer.* 1986;57(10):2006-21.

Access this article online

<http://pediatricurologycasereports.com>

Quick Response Code

