



Management of acute paraphimosis in a 3-year-old boy: A case report and current treatment options

Volkan Sarper Erikci 

Department of Pediatric Surgery, Tepecik Training Hospital, University of Health Sciences, Izmir, Turkey

ABSTRACT

Paraphimosis is a disease when the foreskin of an uncircumcised penis is left retracted behind the glans penis for a time period. An uncircumcised boy with paraphimosis was treated with dorsal slit following subsequent circumcision. If normal anatomy is not corrected, serious consequences can occur, including necrosis or partial amputation of the glans penis; therefore, an urgent approach is necessary. This case is presented and discussed with reference to etiology and current treatment options in paraphimosis which is a rare but real urological emergency problem.

Key Words: Paraphimosis, treatment, surgical management, child.

© 2020 [pediatricurologycasereports.com](http://www.pediatricurologycasereports.com)

✉ *Dr. Volkan Sarper Erikci,*
Department of Pediatric Surgery, Tepecik Training
Hospital, Sağlık Bilimleri University, Izmir, Turkey
E mail: verikci@yahoo.com

Received: 2020-02-18 / Revisions: 2020-03-10

Accepted: 2020-03-12 / Publication Date: 2020-05-01

Introduction

Paraphimosis is a true urological emergency that occurs when the foreskin is trapped behind the corona area of the glans penis. Retracting the foreskin of an uncircumcised male is an initial event and, if left untreated, can have serious consequences such as edema, extreme pain, distal venous congestion, and even necrosis [1,2]. In cases where paraphimosis is suspected, attempts without adequate analgesia and sedation are likely to fail, and further examination or treatment interventions can make it very difficult [2]. Therefore, pediatric surgical consultation is

recommended immediately. Here we present a case of paraphimosis developing acutely in a 3-year-old uncircumcised boy with current treatment approaches and a literature review.

Case report

A 3-year-old boy was admitted to our department with a painful swelling of the glans penis including retraction of foreskin behind the glans penis (Fig. 1, 2). History of the patient revealed that while playing at home, he unintentionally retracted the foreskin and could not reduce it for 8 hours before coming to hospital. When his parents noticed it they immediately took their child to the emergency department. Manual reduction was attempted using topical anesthetic gel but could not be performed due to huge swelling and intractable edema of the glans penis. Urgent surgical intervention under general anesthesia

including dorsal slit of the constricting prepuce and a safe circumcision solved the problem (Fig. 3). The patient was discharged home in good condition on the first postoperative day. There was no recurrence during the 2nd year postoperative follow-up period and he is currently under follow-up. The study was carried out in compliance with the 1964 Helsinki Declaration and was approved by the ethical committee of Tepecik Training Hospital. All photos were taken with parental consent and the written consent from the family was taken and there is no conflict of interest to declare.



Fig. 1. Dorsal view of paraphimotic penis.



Fig. 2. Lateral view of paraphimotic penis.



Fig. 3. Postoperative ventral view of penis after circumcision.

Discussion

As a cause of one of the few urologic emergencies that may be encountered in general practice, paraphimosis has been reported to occur in 0.7% of uncircumcised boys [3]. Paraphimosis is observed in uncircumcised males when foreskin is pulled back behind the glans penis and left there for a period of time. Etiology of paraphimosis include mostly iatrogenic factors including penile examination, urethral catheterization or cystoscopy and it commonly occurs iatrogenically, when the foreskin is retracted for cleaning, placement of a urinary catheter, a procedure such as a cystoscopy, or for penile examination [4]. Typical presentation is that, after insertion of foley catheter, health provider forgets to return the retracted foreskin to its original position [5]. Other causes of paraphimosis include self-inflicted injury to the penis like piercing a penile ring into the glans and penile erections [6,7]. The reason of paraphimosis in our case was unintentional retraction of foreskin by himself while playing at home which was noticed by his parents

nearly 8 hours after the occurrence. If untreated for a prolonged time, constriction of glans penis may impede the blood and lymphatic flow which can give rise to penile ischemia even penile gangrene and autoamputation may follow [8].

The most common symptoms of paraphimosis include swelling of the penis, penile pain and inability to pull the foreskin back. As the time passes, the tip of the penis gets dark red or blue in color as in our case. Painful urination and decreased urinary stream may also be observed in patients with paraphimosis [1-4]. Swelling of penis with discoloration of the penile shaft and glans penis was observed in our patient and failure of nonoperative management prompted us to perform urgent dorsal slit including reduction of paraphimosis together with a safe circumcision.

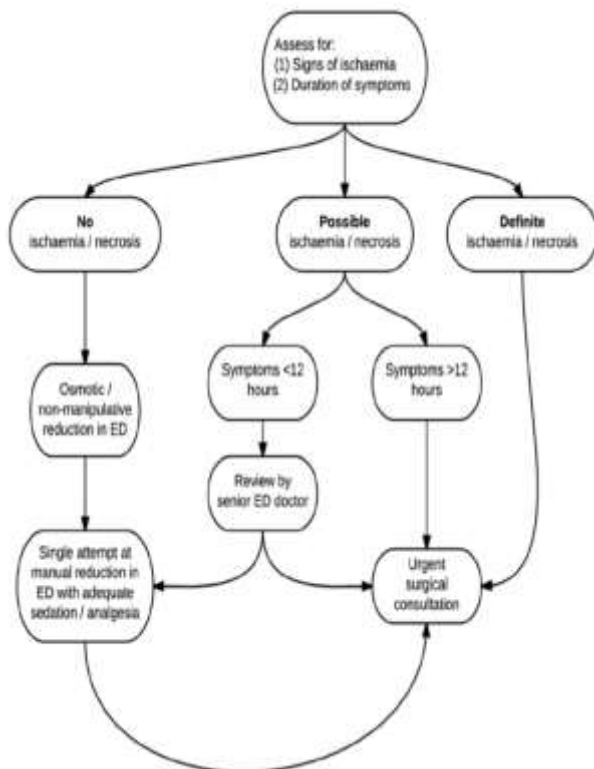


Fig. 4. Clinical assessment determines the management plan for paraphimosis [1].

Once the diagnosis of paraphimosis is made, prompt management is paramount in order to

avoid unwanted consequences of tight constriction of glans penis. Clifford et al. [1] proposed a guide for clinical assessment and management for paraphimosis (Fig. 4). The aims of management include reducing penile and glans edema and retracting the foreskin back over the glans penis to its original anatomic position. Several noninvasive techniques have been suggested for the management of paraphimosis and include manual reduction, pharmacologic therapy including hyaluronidase injection and usage of granulated sugar [9-12]. Because of pain during the procedure, penile nerve block, topical analgesic agents or oral/iv narcotics are often used. In our case topical analgesia with 2% lidocaine gel was used before attempting manual reduction of paraphimosis. "Iced glove" technique has also been proposed as an adjunct in reducing paraphimosis using a combination of cooling and compression to help decrease penile edema [13]. When these noninvasive measures fail invasive therapy becomes a matter of necessity rather than of choice. These operative procedures include "puncture" technique using hypodermic needle to puncture the edematous prepuce, blood aspiration of the tourniqueted penis and if all these methods fail to reduce paraphimosis, emergent dorsal slit with subsequent circumcision should be performed [14-16]. In order to avoid ischemic changes, after an unsuccessful attempt for manual reduction of paraphimosis, urgent dorsal slit with circumcision solved the problem in our case.

In conclusion, paraphimosis is a rare but an important cause of one of the real urologic emergencies. It has the potential for catastrophic penile injury including ischemia and necrosis of the glans penis. If simple methods for reduction of paraphimosis fail urgent surgical intervention should be

performed. Timely and accurate management of these children is recommended for the preservation of viability for both glans penis and penile shaft. The health providers dealing with such kinds of patients should keep this emergent situation in mind and a prompt pediatric surgical consultation is recommended and the patient should be treated accordingly.

Compliance with ethical statements

Conflicts of Interest: None.

Financial disclosure: None.

Consent: We obtained the informed consent from the patient's parents to report this case.

ORCID iD of the author (s)

Volkan Sarper Erikci / 0000-0002-9384-2578

References

- [1]Clifford ID, Craig SS, Nataraja RM, et al. Paediatric paraphimosis. *Emerg Med Australas.* 2016; 28(1):96–99.
- [2]Palmisano F, Gadda F, Spinelli MG, et al. Glans penis necrosis following paraphimosis: A rare case with brief literature review. *Urol Case Rep.* 2017; 16:57–58.
- [3]Herzog LW, Alvarez SR. The frequency of foreskin problems in uncircumcised children. *Am J Dis Child.* 1986; 140(3):254–256.
- [4]Hayashi Y, Kojima Y, Mizuno K, et al. Prepuce: phimosis, paraphimosis, and circumcision. *ScientificWorldJournal.* 2011; 11:289–301.
- [5]Choe JM. Paraphimosis: current treatment options. *Am Fam Physician.* 2000; 62(12): 2623-28.
- [6]Jones SA, Flynn RJ. An unusual (and somewhat piercing) cause of paraphimosis. *Br J Urol.* 1996; 78(5): 803-4.
- [7]Higgins SP. Painful swelling of the prepuce occurring during penile erection. *Genitourin Med.* 1996; 72(6):426.
- [8]Hollowood AD, Sibley GN. Non-painful paraphimosis causing partial amputation. *Br J Urol.* 1997; 80(6):958.
- [9]Litzky GM. Reduction of paraphimosis with hyaluronidase. *Urology.* 1997; 50(1):160.
- [10]Cahill D, Rane A. Reduction of paraphimosis with granulated sugar. *BJU Int.* 1999; 83(3):362.
- [11]Palmisano F, Gadda F, Spinelli MG, et al. Glans penis necrosis following paraphimosis: A rare case with brief literature review. *Urol Case Rep.* 2017; 16:57–58.
- [12]Pohlman GD, Phillips JM, Wilcox DT. Simple method of paraphimosis reduction revisited: point of technique and review of the literature. *J Pediatr Urol.* 2013; 9(1):104-7.
- [13]Houghton GR. The "iced-glove" method of treatment of paraphimosis. *Br J Surg.* 1973; 60(11):876–77.
- [14]Hamdy FC, Hastie KJ. Treatment for paraphimosis: the 'puncture' technique. *Br J Surg.* 1990; 77(10):1186.
- [15]Finkelstein JA. "Puncture" technique for treating paraphimosis. *Pediatr Emerg Care.* 1994; 10(2):127.
- [16]Raveenthiran V. Reduction of paraphimosis: a technique based on pathophysiology. *Br J Surg.* 1996; 83(9):1247.