

## Monophasic Wilms' tumor with multiple skeletal metastases in a young female: A case report and review of literature

Sreeranga YL,<sup>1</sup> Anil Kumar N,<sup>1</sup> Tyagi A,<sup>1</sup> Vijaya Lakshmidivi B,<sup>2</sup> Chowhan AK<sup>3</sup>

<sup>1</sup>Department of Urology, Sri Venkateswara Institute of Medical Sciences, Tirupati, India

<sup>2</sup>Department of Radiology, Sri Venkateswara Institute of Medical Sciences, Tirupati, India

<sup>3</sup>Department of Pathology, Sri Venkateswara Institute of Medical Sciences, Tirupati, India

### Abstract

Wilms' tumor (nephroblastoma) is the most common renal tumor in children. It is uncommon in adolescent and skeletal metastasis at the time of presentation is even rare. The present case is a rare monophasic blastemal variant of Wilms' tumor presenting with multiple skeletal metastases in a young female. We report a case of 23-year-old female presented with severe low backache and colicky right loin pain of 1 month and constant dull aching left upper arm pain of 20 days duration. Contrast-enhanced computed tomography (CECT) abdomen revealed heterogeneously enhancing soft tissue density mass with central nonenhancing areas arising from the upper pole of the right kidney. Whole body <sup>18</sup>F-Sodium Fluoride (NaF) Positron emission tomography-computed tomography (PET/CT) bone scintigraphy revealed multiple skeletal metastases. The patient underwent right radical nephrectomy and the tumor was confirmed as adult Wilms' tumor by histopathology and immunohistochemistry. Skeletal metastasis may be the first presentation in a case of adolescent Wilms' tumor, and this possibility should be considered when an adolescent patient presents with flank pain and a renal mass. The clinical course of adult Wilms' tumor with blastemal component is very aggressive with high chances of recurrence and mortality.

### Keywords

Wilms' tumor; blastemal variant; <sup>18</sup>F NaF PET/CT bone scintigraphy; skeletal metastasis.

Copyright © 2016 [pediatricurologycasereports.com](http://www.pediatricurologycasereports.com).

**Corresponding Author:** Sreeranga YL,

Department of Urology, Sri Venkateswara Institute of  
Medical Sciences- 517507, Tirupati, India.

E-mail: [ylr9999@gmail.com](mailto:ylr9999@gmail.com)

Accepted for publication: 21 February 2016

## Introduction

Wilms' tumor is the most common renal tumor in children derived from pluripotent embryonic renal precursor cells of the mesonephric blastema. Fifty percent of cases occur before the age of 3 years and 90% before 7 years, whereas only 1% of Wilms' tumors are reported in adults [1]. The primary distant site for Wilms' tumor metastasis is the lung; hepatic and lymph nodal metastases are much less common and skeletal metastasis being extremely rare [2,3] The diagnosis is often unexpected and made after nephrectomy for presumed renal cell carcinoma. Young and adult Wilms' tumor may have a more aggressive clinical course and a higher tumor stage at the time of presentation compared to that in children [4]. Outcome for adults is inferior compared with children as there is often a delay in initiating chemotherapy while diagnostic review is being undertaken by oncologists and pathologists [5]. We hereby report a case of young female Wilms' tumor with multiple skeletal metastases at initial presentation with brief review of literature.

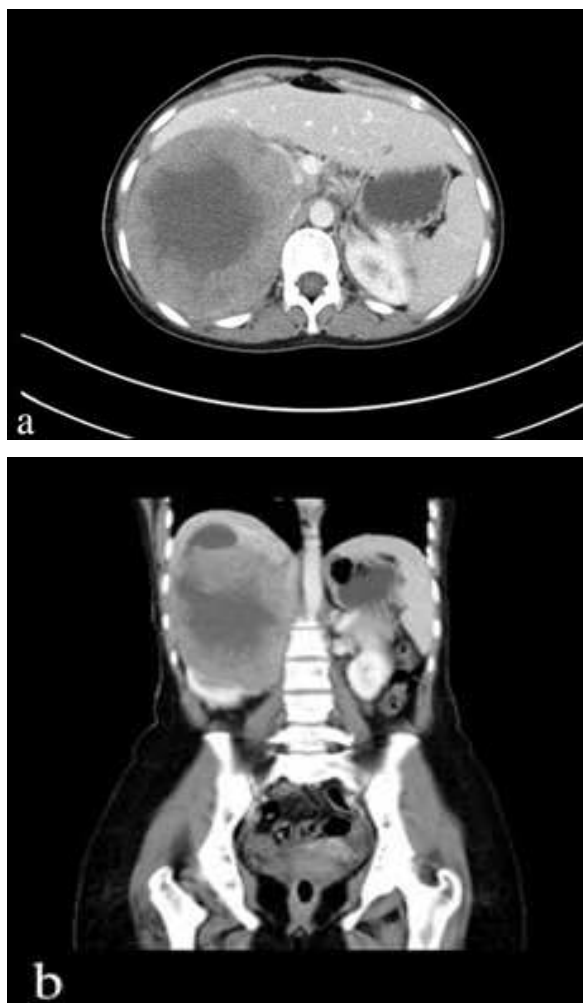
## Case report

A 23 year old female presented with severe low backache and colicky right loin pain associated with vomiting since 1 month.

There was history of constant dull aching left upper arm pain which got worse with activity and not relieved by rest or pain medication since 20 days. There was neither any history of prior abdominal surgery nor any history of trauma. Further there was no complaint of hematuria, pyuria, or calculuria. She was unmarried with regular menstrual cycle.

Per abdomen examination revealed tender mass palpable in the right upper quadrant of the abdomen.

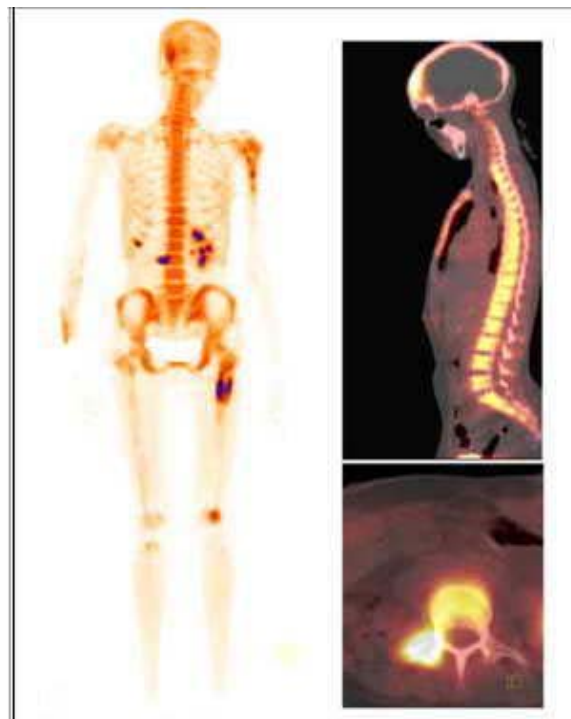Routine laboratory investigations showed hemoglobin of 11.2 g/dl, leukocyte count of 12,600 cells/cumm, platelet count of 4.51 lakhs/cumm, serum creatinine of 0.54 mg/dl and liver function tests were within normal limits except for marked elevation of serum LDH levels which was 2169 IU/L. Chest X-ray was normal. Abdominal ultrasonography (US) showed a large heterogeneous lesion measuring 11.8 × 10 cm in upper pole of right kidney containing few foci of cystic degeneration and areas of increased vascularity. Contrast-enhanced computed tomography (CECT) abdomen reported as heterogeneously enhancing soft tissue density lesion measuring 14 × 11 cm arising from the upper pole of the right kidney with central non-enhancing areas [Fig. 1a and b].



**Fig. 1.** Post contrast axial image (a) and coronal image (b) showing heterogeneously enhancing soft tissue density lesion with central non-enhancing areas arising from the upper pole of the right kidney with mass effect on inferior vena cava.

The lesion was abutting right lobe of liver and causing mass effect on inferior vena cava (IVC). Right renal artery was involved and right renal vein was stretched by the mass lesion. Whole body  $^{18}\text{F}$ -Sodium Fluoride (NaF) PET/CT bone scintigraphy revealed increased radio-tracer uptake suggestive of metastases involving the right frontal bone, proximal 1/3<sup>rd</sup> of left humerus,

anterior 1/3<sup>rd</sup> of right 8<sup>th</sup> rib, right transverse process and hemibody of third lumbar vertebra and proximal 1/3<sup>rd</sup> of left femoral shaft [Fig. 2].



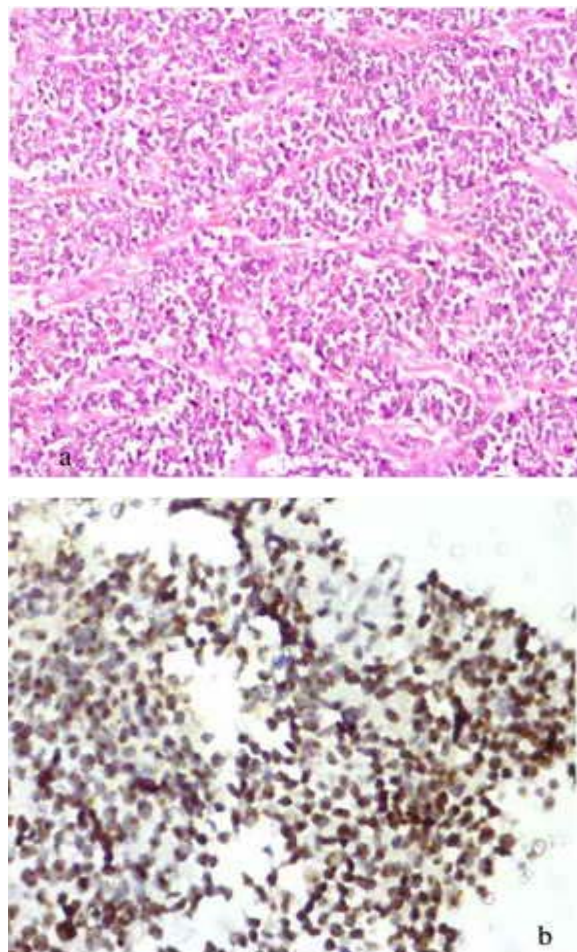
**Fig. 2.** Whole body  $^{18}\text{F}$ -Sodium Fluoride (NaF) PET/CT bone scintigraphy showing multiple skeletal metastases before chemotherapy.

The patient underwent right radical nephrectomy. The nephrectomy specimen measured 20×11×7 cm. Cut section showed a large grey white lesion measuring 13×10 cm with areas of hemorrhage and necrosis. Microscopically, the tumor comprised of round to mild pleomorphic cells present as solid sheets, nests, ill defined trabeculae with intervening many proliferating congested capillaries, large areas of necrosis, thick and thin fibrous septations with

hyalinization [Fig. 3a]. Ureteric margin was free of tumor. The specimen was grossed extensively but did not reveal any foci of clear cell renal cell carcinoma. Histological possibilities considered were monophasic variant of Wilms' tumor (blastemal component) and poorly differentiated renal cell carcinoma. Immunohistochemistry was performed with a panel of antibodies like Cytokeratin, EMA, Vimentin, CD10, CD99, LCA, WT 1. The tumor exhibited mild focal positivity for Vimentin and CD 99 and moderate to intense nuclear positivity for WT 1 [Fig. 3b] which favored the diagnosis of Wilms' tumor. The tumor did not reveal any anaplasia and nephrogenic rests also could not be seen, there by falling into the category of favorable histology.

Patient received palliative radiotherapy and six cycles of chemotherapy. Three weeks after surgery, she was put on combination chemotherapy and radiotherapy. She received a total of 2520cGY over 14 fractions (180 cGy/day) to symptomatic bone sites such as left humerus, left femur and L-3 vertebra and 3000 cGY over 10 fractions (300 cGy/day) to brain and injection Zolodronic acid 4mg. Further she completed 6 cycles of pulsed intensive DD4A regimen (weeks 1-6). The chemotherapy schedule was Dactinomycin 1.35 mg/M<sup>2</sup> IV over 1-5 minutes once in

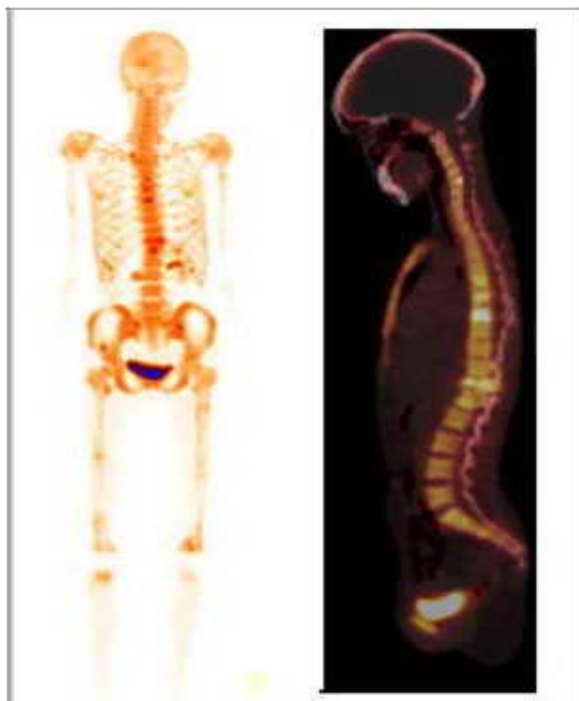
week 1; Vincristine 2.0 mg/M<sup>2</sup> IV once in weeks 1-6; and Doxorubicin hydrochloride 45 mg/M<sup>2</sup> IV over 15 minutes once in week 4.



**Fig. 3.** Photomicrograph showing (a) ill defined trabeculae and nests of round to pleomorphic cells with scant cytoplasm (H&Ex20) (b) diffuse intense nuclear positivity for Wilms' Tumor 1(WT-1) in tumor cells (IHCx40).

CECT abdomen 3 weeks after chemotherapy showed multiple retroperitoneal, anterior abdominal wall, paracolic and pelvic deposits. Follow-up whole body <sup>18</sup>F-Sodium

Fluoride (NaF) PET/CT bone scintigraphy revealed progression of the disease with appearance of new lesions in the shaft of right femur, spine (D-6,7,8 with wedging of D12,L1 vertebrae), pelvis when compared with previous bone scan [Fig 4].



**Fig. 4.** Whole body  $^{18}\text{F}$ -Sodium Fluoride (NaF) PET/CT bone scintigraphy showing after 6 cycles of chemotherapy.

Patient received palliative radiotherapy to these new bone lesions with a total dose of 2000cGY over 5 fractions (400cGY/day). Patient refused to continue the treatment afterwards and died 3 months later.

### Discussion

Wilms' tumor, or nephroblastoma, is a malignant renal tumor that arises from abnormal proliferation of metanephric

blastema without differentiation into glomeruli and tubules. Wilms' tumor is extremely rare in adults, accounting for 1% of renal tumors in this age group [1,5]. Fewer than 300 adult cases have been reported in world medical literature [6]. The clinical presentation of adults with Wilms' tumor differs from that of children. The main symptom of adults is flank pain, and the majority of them have a history of weight loss and of a sudden drop in performance status. In children, tumors are mainly asymptomatic, or children present with a painless swollen abdomen. There is no significant difference between the radiological appearance of Wilms' tumor seen in either children or adults. About 75-80% of the cases have similar clinical and radiological findings. It is possible to confuse a Wilms' tumor with renal cell carcinoma because of the similar radiological appearances [7].

Classic Wilms' tumor is composed of three types of cells i.e. undifferentiated blastemal, stromal, and epithelial; although the occurrence of all three types in the same case is uncommon [8,9].

Adult Wilms' tumor is diagnosed based on the criteria given by Kilton, Mathews, and Cohen [9,10]. These include: 1) The tumor under consideration should be a primary renal neoplasm; 2) Presence of primitive



blastemic spindle or round cell component; 3) Formation of abortive or embryonal tubules or glomerular structures; 4) No area of tumor diagnostic of renal cell carcinoma; 5) Pictorial confirmation of histology and 6) Patient's age >15 years.

The differential diagnosis of an adult Wilms' tumor with mainly epithelial differentiation includes metanephric adenoma. A predominant blastemic Wilms' tumor has a strong resemblance to lymphoma, peripheral neuroectodermal tumor and rhabdomyosarcoma. Extensive search for any other components is needed as a poorly differentiated renal carcinoma can have large sarcomatous areas resembling blastema. Immunohistochemistry with a panel of antibody markers can differentiate the various tumors accurately.

In adults, about half of the patients have stage 3 or 4 disease. The most frequent places of metastases are lung, liver, bones, skin, bladder, colon, brain and contralateral kidney. Metastasis rates for children and adults are 10% and 29%, respectively [7]. Skeletal metastasis is extremely rare. To our knowledge this was the second case of blastema variant of Wilms' tumor presenting with multiple bone metastases in a young. Females are involved in all the four cases available from the world literature. This might indicate that female gender is a

significant risk factor for development of skeletal metastasis [Table 1].

**Table-1: Literature review of adult Wilms' tumor with skeletal metastasis at initial presentation**

Study	Year	No. Pati.	Age / Sex	Histological variant
Lu SY et al <sup>[3]</sup>	2005	1	18 / F	Epithelial
H Joo Jeong et al <sup>[9]</sup>	1989	1	69 / F	Blastemal
R Patnayak et al <sup>[10]</sup>	2012	1	19 / F	Blastemal
Present case	2015	1	23 / F	Blastemal

The prognosis of Wilms' tumor in adults is worse than in children because of the advanced stage at the time of clinical presentation, unfavorable histology in majority of cases, high recurrence, and the lower response rate to chemotherapy regimens [10]. In spite of multimodal approach similar to childhood Wilms' tumor, the treatment outcome in adults is disappointing. The majority of adult Wilms' tumor patients die of metastatic disease.

## Conclusions

Adolescent Wilms' tumor is rare and diagnosed on histopathology after nephrectomy for presumed renal cell carcinoma, as in our young female case. Tumors containing blastemal component will have more aggressive clinical course associated with increased risk of recurrence

and high mortality. Prognosis is poor despite aggressive multimodal therapy.

## References

1. Heidi Seqers, Marry M van den Heuvel-Eibrink, Kathy Pritchard-Jones, et al. Management of adults with Wilms' tumor: recommendations based on international consensus. *Expert Rev Anticancer Ther.* 2011; 11(7):1105-13.
2. Shahla Ansari, Ghasem Miri-Aliabad, Naser Rakhshani. Bilateral Wilms' Tumor Metastasis to Right Spermatic Cord. *Int J Hematol Oncol Stem Cell Res.* 2013; 7(4): 45–48.
3. Lin F, Krishnamurthy S. Fine needle aspiration cytology of a skeletal metastasis of adult Wilms' tumor. A case report. *Acta Cytol.* 2001; 45(3):393-8.
4. Adolphs HD, Knopfel G, Vogel J. Wilms tumor in the adolescent and adult. *Eur J Urol* 1983;9: 281-7.
5. Elwira Szychot, John Apps, Kathy Pritchard-Jones. Wilms' tumor: biology, diagnosis and treatment. *Transl Pediatr* 2014; 3(1):12-24.
6. Jay Krishnan, Jerome Pietras, Marcella Nachmann, Gordon Brown. Adult Wilms' Tumor with a Unique Presentation of High-Grade Fever, Photophobia, and Headache. *Rev Urol.* 2012; 14(1-2): 31–34.
7. Patil TV, Patel KM, Shukla SN, Parikh BJ, Anand AS, Shah MS. Adult Wilms' tumour. *Indian J Med Paediatr Oncol.* 2008;29(4):37-40.
8. Ebb DH, Green DM, Shamberger RC, Tarbell NJ. Solid tumors of childhood. In *Cancer principles and practice of oncology.* In: DeVita VT Jr, Hellman S, Rosenberg SA, editors. 7th ed. Philadelphia: Lippincott Williams and Wilkins; 2005.
9. Hyeon Joo Jeong, Kwang Hwa Park, Hyung Ki Choi, Ki Hwang Kim et al. Adult Wilms' tumor: a case report. *Yonsei Med J.* 1989; 30(1):88-94.
10. Rashmi Patnayak, D. V. S. Rambabu, Amitabh Jena, Bodagala Vijaylaxmi et al. Rare case of blastemal predominant adult Wilms' tumor with skeletal metastasis case report and brief review of literature. *Indian J Urol.* 2012; 28(4): 447–449.

## Acknowledgements

The author(s) declare that they have no competing interests and financial support.

Access this article online

<http://pediatricurologycasereports.com>

Quick Response Code

