



Multiple bilateral stones as a cause of acute renal failure: Three case reports

Hulya Ozturk, Emine Dagistan, Ugur Uyeturk

Abstract Complex renal stones are staghorn calculi stones >2 cm and most calculus are calcium stones. In patients found with obstruction may need an emergency intervention. Three patients with multiple stones causing bilateral renal obstruction were operated.

Key Words Anuria; calculus; multip stones; renal obstruction; management.

© 2014 pediatricurologycasereports.com. All Rights Reserved

INTRODUCTION

About 5-15% of the population worldwide affects from urolithiasis [1]. New stone formations after treatment are close to 50% [2]. Additionally, the cost of treatment to persons and society is high [3]. The main types of the kidney stones are calcium, uric acid, struvite (magnesium ammonium phosphate), and cystine stones.

However, most (75% to 80%) kidney stones are calcium stones, composed of calcium oxalate and/or calcium phosphate [4]. The one patient may have more than one type of stone concurrently (e.g. calcium oxalate and uric acid) [9]. Complex renal stones such as staghorn calculi include stones >2 cm and this stones occurring usually in kidneys with abnormal anatomy. In patients found with obstruction and anuria may need an emergency intervention [3].

*From the Department of Pediatric Surgery, Radiology and Urology, Abant Izzet Baysal University, Medical School, Bolu, Turkey. **Corresponding Author:** Hulya Ozturk-Associate Prof, M.D. Abant Izzet Baysal University, Medical School, Department of Pediatric Surgery, Bolu, Turkey*

E mail: hulya_ztrk@yahoo.com

Accepted for publication 4 April 2014

In this study, three patients with multiple stones causing bilateral renal obstruction were presented by reviewing the literature.

CASE REPORT

Two 12 and 13-year-old boy and 14 year old one girl with calculus anuria were admitted through emergency. Urine output between 0–100 ml/24 hours was regarded as anuria. Blood urea, serum creatinine, serum electrolytes were investigated. Blood urea and serum creatinine were increased moderately.

Urinary ultrasonography was performed and bilateral multiple stones were demonstrated. X-Ray was taken for size and site of stone in the urinary tract (Fig. 1,2,3).


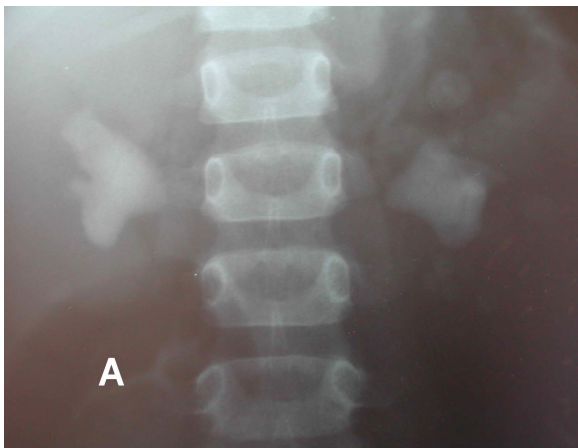


Fig. 1. A, B. The appearance of the x-ray and stones cases in the first patient.

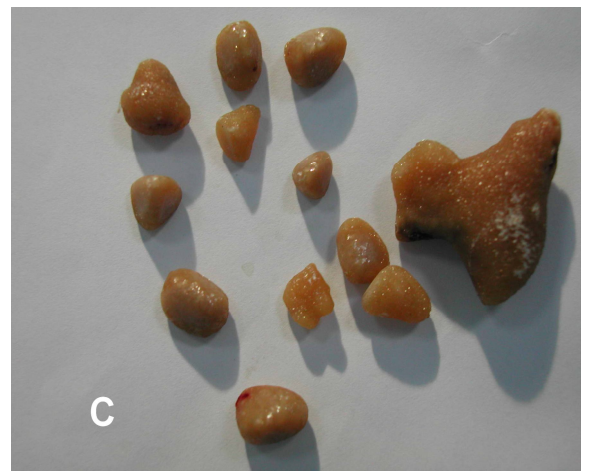
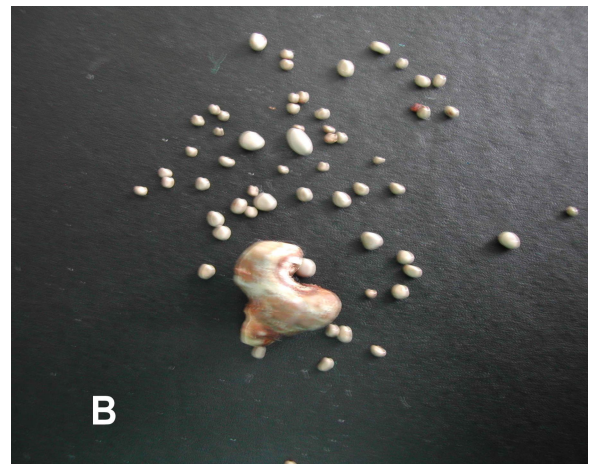
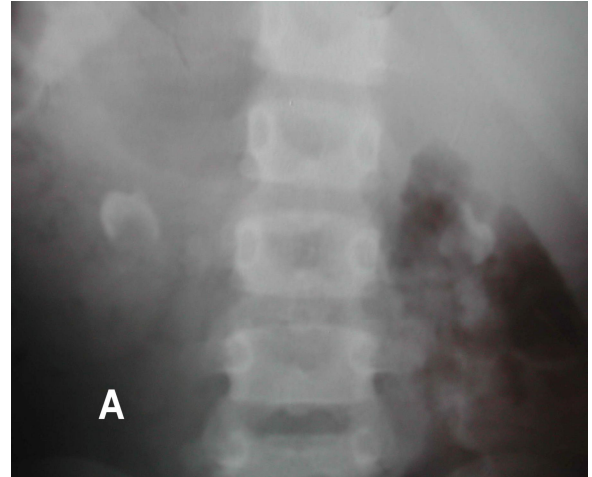


Fig. 2. A, B, C. The appearance of the x-ray and stones cases in the second patient.

Three cases were operated and urea and creatinine levels were postoperatively found normal and patients were removed obstruction. Three patients were discharged uneventfully.




Fig. 3. A, B, C. The appearance of the x-ray and stones cases in the third patient.

DISCUSSION

Bilateral pelvic or ureteric calculus and unilateral ureteric calculus impaction of solitary kidney may cause anuria. There is obstructive uropathy in about 5% of the patients admitted with acute renal failure and urolithiasis is the most common cause of obstruction [5]. Symptoms in patients with obstructive uropathy are depended upon calculus size. Most patients with caliceal stones which are documented as immobile do not have pain. X-ray can detect radiolucent stones missed on kidney and ultrasonography may miss small stones and ureteral stones [6].

Features of the stones, renal anatomy, and clinical findings are all considered in a treatment approach for renal calculi. Calculus anuria is a urological emergency and upper urinary tract obstruction increases renal pelvic pressure, which reduces glomerular filtration and renal blood flow [6].

After treatment of the renal obstruction is significantly improved concentrating and acidifying ability of the kidney.

Staghorn stones >2 cm resistant to fragmentation occurs usually in kidneys with abnormal anatomy and these known as complex kidney stones. Open surgery was the mainstay of treatment for urolithiasis, but it now is supported less invasive approaches. American Urologic Association recommends that percutaneous nephrolithotomy is the treatment of choice for most complex renal stones [7]. In a study on 54 children of calculus anuria, Mohammed A. Elgammal et al [8] concluded that formal surgery in compensated children is associated with good out come and early recovery. They suggested that urinary diversion in children is associated with high complication rate while dialysis is highly effective. In the three cases presented here were found obstruction of bilateral stone and patients were operated emergency. The main stone in

the pelvis of the kidney was removed along with numerous other stone. Complete bilateral obstruction together with oliguria or anuria is incompatible with long survival unless treatment. Prompt and early intervention can save the kidney of patient and prevent to develop acute renal failure.

CONFLICT OF INTEREST

None declared.

REFERENCES

1. Moe OW. Kidney stones: pathophysiology and medical management. *Lancet*. 2006; 367:333-44.
2. Sutherland JW, Parks JH, Coe FL. Recurrence after a single renal stone in a community practice. *Miner Electrolyte Metab*. 1985;11:267-9.
3. Miller NL, Evan AP, Lingeman JE. Pathogenesis of renal calculi. *Urol Clin North Am*. 2007;34:295-313.
4. Deshpande S, Malekar S, Asghar S, Showkat P, Pragati U. A case report of urolithiasis of patient with multiple

- bilateral renal stones bilateral renal Stones. International Journal of Scientific and Research Publications. 2013;3:1-4.
5. Khan AG, Lal S, Soomro MI, Jalbani MH. Calculus anuria and its remedy. J Ayub Med Coll Abbottabad. 2010;22:12-114.
 6. Alonso JV, Cachinero PL, Ubeda FR, Ruiz DJL, Blanco A. Bilateral stones as a cause of acute renal failure in the emergency department. World J Emerg Med. 2014;5:67–71.
 7. Preminger GM, Assimos DG, Lingeman JE, Nakada SY, Pearle MS, Wolf JS Jr. Chapter 1: AUA guideline on management of staghorn calculi: diagnosis and treatment recommendations. J Urol. 2005; 173:1991-2000.
 8. Mohammed A. Elgammal, Mohammed S. Abdel-kader, Adel kurkar *et al.* Management of calculus anuria in children: Experience of 54 cases. J Pediatr Urol. 2009;5:462–5.