



## Multiple urethroperineal fistula in a boy with posterior urethral valve: A case report of an extremely rare association

Md. Samiul Hasan,  Ipsita Biswas, Umama Huq

Department of Pediatric Surgery, Dhaka Shishu (Children) Hospital, Shere Bangla Nagar, Dhaka, Bangladesh

### ABSTRACT

We describe a case of posterior urethral valve with multiple urethroperineal fistulas. This association is extremely rare. The crucial point in the diagnosis is to distinguish these fistulas from the urethral duplications that actually guide the treatment. The presence of these fistulas in patients with posterior urethral valve may have a beneficial effect on renal function as it reduce the pressure on the bladder. On the other hand, incomplete valve ablation may contribute to the recurrence of the fistula.

**Key Words:** Urethroperineal fistula, posterior urethral valve, urethral duplication.

© 2020 [pediatricurologycasereports.com](http://www.pediatricurologycasereports.com)

✉ Md. Samiul Hasan, MBBS, MS, Assistant Prof.  
Department of Pediatric Surgery, Dhaka Shishu  
(Children) Hospital, Shere Bangla Nagar, Dhaka,  
Bangladesh

E mail: [samiulo45@gmail.com](mailto:samiulo45@gmail.com)

Received: 2019-11-18 / Revisions: 2019-12-06

Accepted: 2019-12-08

Publication Date: 2020-01-01

### Introduction

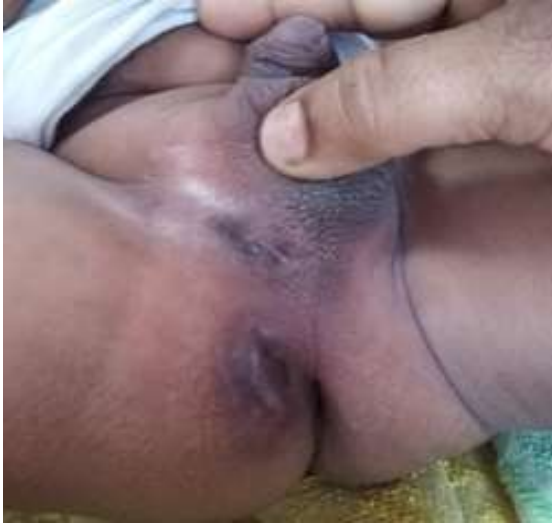Congenital urethroperineal fistula (CUPF) is a very rare anomaly of the lower urinary tract in children. In addition to the normal orthotopic urethra, there exists an extra channel draining from prostatic urethra to perineum. This term sometimes creates confusion with hypospadiac variety of urethral duplication especially Y duplication (Effmann type IIA2). In contrast to duplication, the orthotopic dorsal urethra in cases of CUPF is of normal caliber and function [1,2]. On the other hand, posterior urethral valve (PUV) is a relatively common

urinary tract anomaly in boys. Several urinary tract anomalies have been described in association with both of these two but the association of CUPF with PUV is extremely rare. In fact, we did not find them together in extensive literature review. We intend to describe a patient with posterior urethral valve who had multiple urethroperineal fistulas draining urine from the posterior urethra proximal to the valve, thereby reducing pressure on bladder and upper tract.

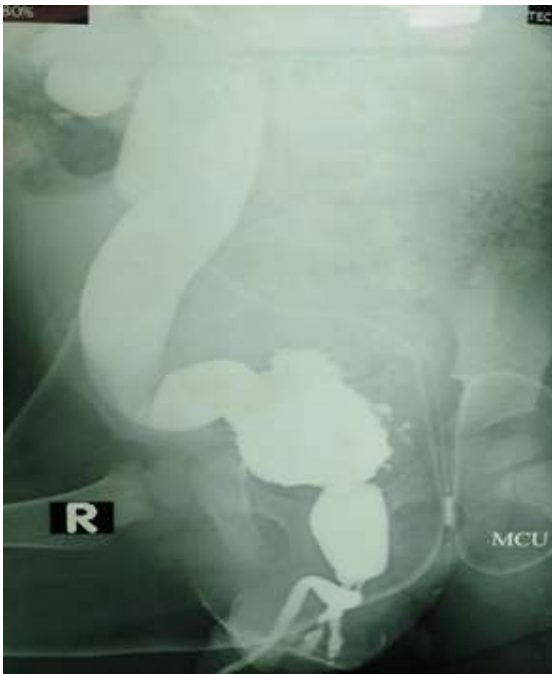
### Case report

One and a half-year-old boy, second issue of his non consanguineous parents from a low socio economic background presented to us with dribbling of urine and straining during micturition since birth. Mother noticed three small openings in the perineum leaking urine during micturition for one year. There was no known congenital anomaly in the family. On

clinical examination, there were three openings in the perineum, right to the midline, surrounded by scar tissue (Fig. 1). The urinary bladder was palpable and both the kidneys were ballotable.



**Fig. 1.** Three opening in the perineum surrounded by scar tissue.



**Fig. 2.** MCUG showing normal anterior urethra, dilated posterior urethra, and two fistulous tracts from posterior urethra, irregular bladder and right sided high grade reflux.

Sonography revealed bilateral hydroureteronephrosis, thickened irregular bladder wall, and dilated posterior urethra. Micturating cystourethrogram (MCUG) showed normal anterior urethra, dilated and elongated posterior urethra. There were two extra channels leading from the posterior urethra to the perineum. The urinary bladder was thick, irregular and had multiple diverticulums. High-grade vesicoureteric reflux (VUR) was present on the right side (Fig. 2).

We did cystoscopic valve ablation and excision of all three fistulas. Postoperatively, the boy is doing well. The perineum is dry. We have a plan to check MCUG after 6 months.

### Discussion

Multiple urethroperineal fistulas are metaphorically called ‘watering can’ perineum. This condition is usually associated with a chronic and severe infection of urethra and perineum. Most commonly occur in gonorrhoea, schistosomiasis, tuberculosis and Crohn’s disease. Its association with the posterior urethral valve has never been found [3].

Congenital urethroperineal fistula is usually single, often deviates on either side of the midline but there is no side preponderance [1]. In this case, there were three opening visible in perineum right to the midline though; MCUG visualized two, maybe due to inadequate pressure in the third tract.

Differentiation of CUPF from urethral duplication is critical which directs the treatment of these conditions. In CUPF, the normally positioned orthotopic urethra is of normal caliber and function. The excision of the fistulous tract is usually curative. On the other hand, ventrally placed urethra in duplication is the main urethra and excision of

which could be devastating [4]. MCUG along with Cystoscopy are enough to differentiate between these two. Some authors used MRI and fistulogram for confirmatory diagnosis [5,6].

Associated upper tract anomalies have been reported in patients with urethroperineal fistula. Most common are vesico-ureteral reflux (VUR), renal dysplasia and agenesis [4,5]. This patient also had right sided VUR which might be due to the presence of PUV.

Urethroperineal fistula in patients with posterior urethral valve could have some beneficial effects also. It reduces the pressure on the bladder and upper tract thereby helps to protect renal function like a pressure pop-off. Different pressure pop-off mechanisms have been described before like unilateral reflux & renal dysplasia, bladder diverticulum, urinoma, and urinary ascites but urethroperineal fistula has never been described in association with posterior urethral valve [7]. Our patient had bladder diverticulum and unilateral reflux and serum creatinine was normal at presentation.

Fistulous tracts in this patient were excised after ablation of posterior urethral valve. It is accepted that reduced pressure in posterior urethra after valve ablation will prevent recurrence of fistula. Recurrence of fistula has been reported requiring re operation [4]. Long term follow up is necessary for this patient to comment on recurrence. Incomplete valve ablation or post-operative urethral stricture may contribute to recurrence of fistula.

### **Conclusion**

Urethroperineal fistula is an extremely rare association with posterior urethral valve which could have a beneficial effect on renal function but it should be carefully differentiated from

urethral duplication which requires completely different management.

### **Compliance with ethical statements**

*Conflicts of Interest:* None.

*Financial disclosure:* None.

*Consent:* All photos were taken with parental consent.

### **ORCID iD of the authors**

*Md. Samiul Hasan /0000-0001-5470-2241*

*Ipsita Biswas /0000-0001-7519-4899*

*Umama Huq /0000-0002-7438-783X*

### **References**

- [1]Bello JO. Congenital posterior urethroperineal fistula: a review and report of the 25th case in literature. *Urology.* 2014;84(6):1492–95.
- [2]Okur MH, Aydogdu B, Arslan S, Basuguy E, Zeytun H, Arslan MŞ. Type II A2 duplication of urethra in an 8-month-old male child: A case report. *Pediatr Urol Case Rep.* 2015; 2(1):17-22.
- [3]Segovis CM, Dyer RB. The ‘watering can perineum’. *Abdom radiol.* 2016; 41: 1214
- [4]Bates DG, Lebowitz RL. Congenital urethroperineal fistula. *Radiology.* 1995;194(2):501–504.
- [5]Badawy H, Youssef M, Saad A, et al. Congenital urethroperinealfistula: report of 2 cases and analysis of the literature. *Afr J Urol.* 2006;12(3):141-43.
- [6]Sakaguchi T, Kon M. Congenital urethroperineal fistula. *J Pediatr Surg Case Rep.* 2018;28:17-20.
- [7]Kaefer M, Keating MA, Adams MC, Rink RC. Posterior urethral valves, pressure pop-offs and bladder function. *J Urol.* 1995;154(2 Pt 2):708–711.