



## Omphalocele, exstrophy of cloaca, imperforate anus and spinal defect (OEIS Complex): A case report

Mete Kaya<sup>1</sup>, Serpil Sancar<sup>1</sup>, Esra Ozcakil<sup>1</sup>, Arzu Akdag<sup>2</sup>

<sup>1</sup> Sevket Yilmaz Education and Research Hospital, Department of Pediatric Surgery, Bursa, Turkey

<sup>2</sup> Sevket Yilmaz Education and Research Hospital, Department of Pediatrics, Division of Neonatology, Bursa, Turkey

**Abstract** Omphalocele, exstrophy of cloaca, imperforate anus and spinal defect (OEIS Complex) is an extremely rare combination of serious defects, which was firstly described by Carey and colleagues. Surgical repair of cloacal exstrophy in patients with OEIS complex can be performed at one stage, but it can also be performed safely as staged to minimize the potential complications. In this case report, we aimed to present our early approach to the OEIS complex.

**Key Words** Cloacal exstrophy; omphalocele; imperforate anus; spinal defect; surgical repair.

Copyright © 2015 [pediatricurologycasereports.com](http://www.pediatricurologycasereports.com)

**Corresponding Author:** Mete Kaya, M.D.

Sevket Yilmaz Education and Research Hospital,  
Department of Pediatric Surgery, Bursa, Turkey

E mail: [kayamete@yahoo.com](mailto:kayamete@yahoo.com)

Accepted for publication: 11 May 2015

### INTRODUCTION

Omphalocele, exstrophy of cloaca, imperforate anus and spinal defect (OEIS Complex) is an extremely rare combination of serious defects consisting of omphalocele,

exstrophy of cloaca, imperforate anus, and spinal defect, which was firstly described by Carey and colleagues [1]. The complex is also known as exstrophy of cloaca, and has an estimated frequency of 1:200,000-400,000 live births [2]. The etiology is unknown, but is probably heterogeneous. The findings of this congenital anomaly show the spectrum of defects that can occur in the embryologic development of the

cloaca and the urorectal septum [3-5]. Exstrophy of the cloaca in OEIS complex includes the persistence and bladder exstrophy that receives ureters, ileum and a rudimentary hind gut. In addition to the four classic defects, several anomalies (e.g., genital abnormalities, renal malformations, symphysis pubis diastasis, limb abnormalities) may be encountered in OEIS patients [6].

Although it may be difficult to diagnose prenatally, the presence of a spinal defect in combination with absent bladder and abdominal wall defect on prenatal sonography may indicate an OEIS complex [3,7]. Many pregnancies electively are terminated after prenatal diagnosis of this anomaly. If it has not been diagnosed, the most babies diagnosed with OEIS complex die shortly after birth or are stillborn. For the past 20 years, survival among the patients with cloacal exstrophy has exceeded 90% [8].

The surgical management of OEIS is typically undertaken in the postnatal period (48 to 72 hours) as a multidisciplinary approach involving neonatologists, pediatric surgeon, pediatric urologist, pediatric orthopedist, pediatric neurosurgeons, genetic, and pediatric endocrinologist. Neurosurgical correction of associated spinal deformities is performed as soon as

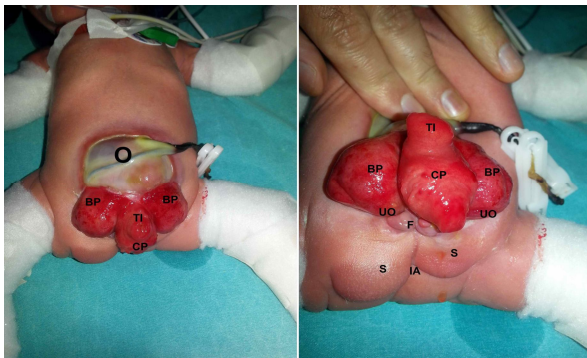
the infant is medically stable. Most of the patients are required so many surgeries, with many potential complications, such as urogenital dysfunctions, neurologic impairment and psychosocial consequences [8,9].

Surgical repair of cloacal exstrophy in patients with OEIS complex can be performed at one stage, but it can also be performed safely as staged to minimize the potential complications [8]. In this case report, we aimed to present our early approach to the OEIS complex.

## CASE REPORT

A 30-year-old G2P2 woman delivered a baby weighing 1900 gm by caesarian section after a 35-week twin gestation. At approximately 18th and 25th weeks of gestation, ultrasound examinations were showed multiple anomalies affecting the one of twins. The baby was consulted by our department for multiple anomalies including omphalocele, cloacal exstrophy, imperforate anus, ambiguous genitalia, and spinal deformity as meningocele. These findings were compatible with the diagnosis of the OEIS complex. The baby had been intubated and received mechanical ventilation in the neonatal intensive care unit (NICU). On examination, the baby had a presence of omphalocele below umbilicus, the

foreshortened hindgut between the two hemibladders in lower part of abdomen. Prolapsed terminal ileum and caecal surface were seen while the anal opening was absent. There was a wide pubic symphysis diastasis, and the phallus was separated into right and left halves with each half of phallus attached to the corresponding pubic bones with the adjacent labioscrotal folds. Both testis were undescended with right inguinal hernia (Fig. 1).

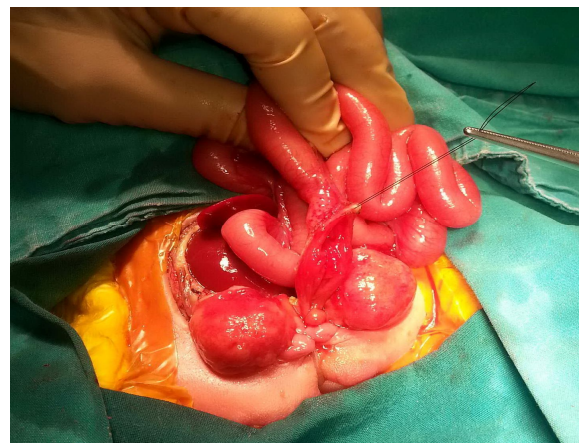


**Fig. 1.** Preoperative appearance of the newborn with OEIS complex: large omphalocele (O), bladder plates (BP); prolapsed terminal ileum (TI), cecal plate (CP), ureteral orifices (UO), separated phallus (F), empty scrotal halves (S), and imperforate anus (IA).

After initial resuscitation and baby was investigated for other associated anomalies. Echocardiography showed a meso dextrocardia, mitral valve failure, patent ductus arteriosus (PDA), and patent foramen ovale (PFO). Ultrasound examination did not reveal any other associated intra-abdominal abnormality. The patient was consulted for evaluation by a neurosurgeon,

and there was recommended an observation without immediate neurosurgical intervention. The karyotype of the patient was 46, XY.

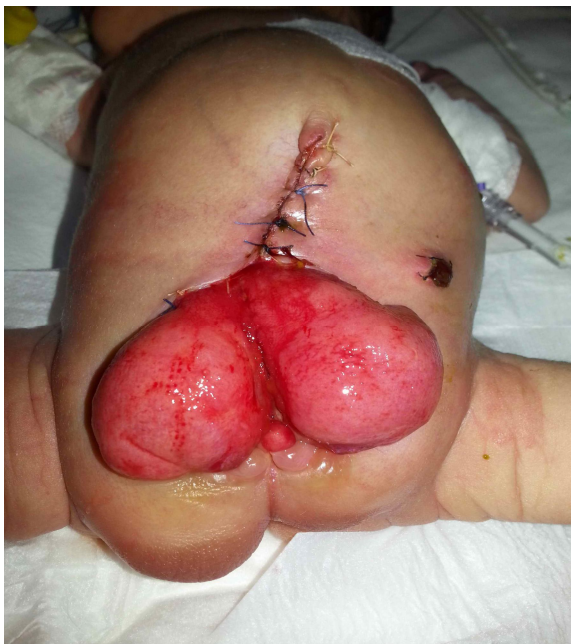Baby was taken for surgery after explanation about procedure to the parents and taking written informed consent on the second day after birth. During operation, the omphalocele membrane was excised, the cecal plate was separated from the two hemibladders and tubularized, and an end-colostomy was created from the distal colon in the left lower quadrant of the abdomen (Fig. 2).



**Fig. 2.** Intraoperative photograph showing the separated intestinal plate from bladder halves.

The two bladder halves were sutured in the midline without dissection from lateral skin attachments. Because of the approximation of the pubis and lower abdominal wall fascia did not seem feasible, and the limited intra-abdominal space, we have decided to take a staged approach, and have planned a

urogenital reconstruction along with pelvic osteotomy at least 3–6 months later. The rectus sheaths on both sides in the upper part of abdominal wall defect were approximated with difficulty by figure of eight stitches and the skin was closed. Thus the appearance of classic bladder exstrophy has become, but it was protruding due to increased intra-abdominal pressure (Fig. 3).

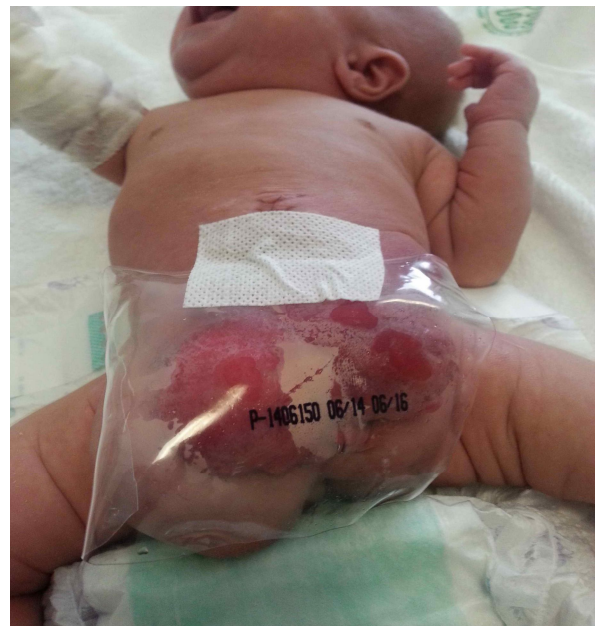

**Fig. 3.** The postoperative photo showing the repaired abdominal wall defect, the classic bladder exstrophy created by approximating of the bladder halves in midline, and end colostomy.

The bladder plate was covered with a plastic sheet to prevent prolonged environmental exposure, and it was able to use the diaper upon this coverage also. The baby was transferred back to the NICU and electively put on mechanical ventilation. Mechanical ventilation was continued for 4 days in the

NICU and the infant improved gradually and discharged at 29 day after the operation.

No serious complication was seen during 3-month follow-up. No serious complication was seen during 3-month follow-up. Plastic coverage was used in all follow-up period, and it has prevented the thickening of the mucosa and the polyp formation owing to chronic irritation (Fig. 4).



**Fig. 4.** Covering of the bladder surface by plastic sheet.

The orthopedic surgeon consulted again when the infant is admitted for second stage of treatment. At this time, a general assessment of symphysis pubic diastasis and potential problems were discussed. There was agreed that pelvic osteotomy should be performed in experienced center, and he has been transferred to another institution which include pediatric orthopedist.

## DISCUSSION

Nowadays, the most of patients with OEIS survive with advances in perinatal caring and surgical reconstruction. After undertaking an initial evaluation and appropriate management of associated life-threatening malformations, patients should be managed by a multidisciplinary team [8-10]. The goals of OEIS management are; separating the bowel from the hemi-bladders to create an intestinal stoma, closing the omphalocele, adaptation of the bladder halves, and adequate cosmetic and functional urogenital reconstructions with preserving renal function. The surgical treatment of OEIS can be achieved in a single or multiple stages with increasing preference towards the staged approach [8,9].

In single stage management, many surgical procedures, including closure of the omphalocele; tubularization of the foreshortened hindgut or caecum and creating terminal colostomy; approximation of two bladder halves; closure of bladder and urethra according to standard principles applied for primary bladder exstrophy repair; reconstruction of the external genitalia with or without osteotomies, are performed under optimal conditions [11].

The single stage management to cloacal exstrophy as a part of OEIS complex has the potential to fail and cause problems with the outcome. The major etiology of failure are from severe symphysis diastasis causing to inadequate approximation of the pubic bones and a tight closure of large abdominal defect leading to organ ischemia.

In infants with associated malformations and who are medically unstable, then it may not be undertaken at this point in a single stage procedure with/without pelvic osteotomy [11-13]. If staging is indicated, firstly, the hemibladders are dissected and then reapproximated in the midline after tubularization of the cecum, and creating an end colostomy, after that the classical bladder exstrophy and imperforate anus repairs are done in the next stages. Additionally the omphalocele closure may lead to organ ischemia from the increased intra-abdominal pressure and a silo may be required in some cases. We were able to close an omphalocele defect in our patient with OEIS complex without tension. However, thereafter, a protruded bladder halves like a hernia along with a large right inguinal hernia was discovered, indicating high intra-abdominal pressure. The 3-month



follow-up visit for the patient remained this appearance. We thought that the staged management in OEIS patients is not only a suitable approach for the reconstruction of urogenital system but also an approach that reduces intra-abdominal pressure.

The symphysis diastasis is usually more severe in OEIS patients. Pelvic osteotomies are almost always necessary for optimal approximation of the pubic bones, for prevention of midline hernias, for a better overall cosmetic result, and for posterior positioning of the urinary tract [10,12,14]. Thus, the current treatment of OEIS needs a pelvic osteotomy that is best performed by an experienced pediatric orthopedist. Actually our approach in bladder exstrophy is that if closure can be done in the first 48-72 h of life, the pubic bones can usually be brought together manually and held in place with nylon sutures through the pubic rami. But the extreme pubic diastasis typical of cloacal exstrophy does not usually allow for tension-free approximation of the pelvic ring as in our case. Thereby osteotomy has become inevitable, and it was left to subsequent stages.

Gender assignment is other complex issue because of reconstruction of external male genitalia can be quite challenging in patients with cloacal exstrophy and OEIS also. Assessment of the genitalia and gender

identity should be made by a multidisciplinary approach. It has been known that male-to-female gender reassignment with gonadectomy could be performed for baby with severe phallic insufficiency. Although there have been received better outcomes for female vs male assignment, the most of pediatric urologists began to support male gender assignment for patients with 46 XY cloacal exstrophy in the last 6 years [15]. In fact, the karyotype had been performed, our patient has not have been recognized as having ambiguous genitalia and had been assigned male gender. However the final decision will be made by referred center.

Another controversial issue in delayed bladder closure is the effect of exposure of bladder mucosa to the environment. Delaying closure while the bladder grows carries some risk in terms of bladder degradation (thickening and pseudo-polyps formation) due to mechanical irritation, inflammation or infection. The bladder mucosa is tried to preserve with using a barrier dressing and frequent irrigation [9,16]. In our case, the open bladder template was covered with plastic sheet to reduce mechanical irritation. The findings of bladder irritation were not seen during the follow up period. Although, except lack of osteotomy equipments, all disciplines in our

hospital can provide a contribution to the diagnosis and treatment of patients with OEIS, only the first stage of the approach to the patient could be performed. We thought that is needed a highly skilled exstrophy team which provides comprehensive anesthetic, orthopedic, nursing and child-life care for these complex patients for later stages.

### Conclusion

There is no standard treatment of OEIS patients, but in common with other reports and larger series, it seems that staged reconstruction is an appropriate approach.

### REFERENCES

1. Carey JC, Greenbaum B, Hall BD. The OEIS complex (omphalocele, exstrophy, imperforate anus, spinal defects). Birth Defects Orig Artic Ser. 1978;14(6B):253-63.
2. Hurwitz RS, Manzoni GA, Ransley PG, Stephens FD. Cloacal exstrophy: a report of 34 cases. J Urol. 1987;138(4 Pt 2):1060-1064.
3. Keppler-Noreuil KM. OEIS complex (omphalocele-exstrophy-imperforate anus-spinal defects): a review of 14 cases. Am J Med Genet. 2001;99(4):271-279.
4. Lee DH, Cottrell JR, Sanders RC, Meyers CM, Wulfsberg EA, Sun CC. OEIS

Because of the complexity of this condition, patients in this population often undergo procedures at multiple hospitals. After separating intestinal plate, in OEIS patients, we recommend delayed closure to allow for the use of osteotomy to better approximate the larger diastasis. Covering of open bladder mucosa by plastic sheet could prevent prolonged environmental exposure.

### Acknowledgements

The author(s) declare that they have no competing interests and financial support.

- complex (omphalocele-exstrophy-imperforate anus-spinal defects) in monozygotic twins. Am J Med Genet. 1999;84:29-33.
5. El-Hattab AW, Skorupski JC, Hsieh MH, Breman AM, Patel A, Cheung SW, et al. OEIS complex associated with chromosome 1p36 deletion: a case report and review. Am J Med Genet A. 2010;152A(2):504-511.
6. Meglin AJ, Balotin RJ, Jelinek JS, Fishman EK, Jeffs RD, Ghaed V. Cloacal exstrophy: radiologic findings in 13 patients. AJR Am J Roentgenol. 1990;155(6):1267-1272.

7. Tiblad E, Wilson RD, Carr M, Flake AW, Hedrick H, Johnson MP, et al. OEIS sequence--a rare congenital anomaly with prenatal evaluation and postnatal outcome in six cases. *Prenat Diagn*. 2008;28(2):141-147.
8. Woo LL, Thomas JC, John W. Brock JW. Bladder and Cloacal Exstrophy. In: Coran AG (ed). *Pediatric Surgery*. 7<sup>th</sup> ed. Philadelphia: Mosby; 2012. pp. 1515-1529.
9. Purves JJT, Gearhart JP, The bladder exstrophy –epispadias- cloacal exstrophy complex. In: Gearhart JP, Rink RC, Mouriquand PDE (eds). *Pediatric Urology*. 2<sup>nd</sup> ed. Philadelphia: W.B. Saunders; 2010 pp. 386-415.
10. Cervellione RM. The use of pelvic osteotomy in cloacal exstrophy. *Semin Pediatr Surg*. 2011;20(2):119-122.
11. Shah BB, Di Carlo H, Goldstein SD, Pierorazio PM, Inouye BM, Massanyi EZ, et al. Initial bladder closure of the cloacal exstrophy complex: outcome related risk factors and keys to success. *J Pediatr Surg*. 2014;49(6):1036-1039.
12. Silver RI, Sponseller PD, Gearhart JP. Staged closure of the pelvis in cloacal exstrophy: first description of a new approach. *J Urol*. 1999;161(1):263-266.
13. Baird AD, Nelson CP, Gearhart JP. Modern staged repair of bladder exstrophy: a contemporary series. *J Pediatr Urol*. 2007;3(4):311-315.
14. Ben-Chaim J, Peppas DS, Sponseller PD, Jeffs RD, Gearhart JP. Applications of osteotomy in the cloacal exstrophy patient. *J Urol*. 1995;154(2 Pt 2):865-867.
15. Diamond DA, Burns JP, Huang L, Rosoklija I, Retik AB. Gender assignment for newborns with 46XY cloacal exstrophy: a 6-year followup survey of pediatric urologists. *J Urol*. 2011;186(4 Suppl):1642-1648.
16. Ferrara F, Dickson AP, Fishwick J, Vashisht R, Khan T, Cervellione RM. Delayed exstrophy repair (DER) does not compromise initial bladder development. *J Pediatr Urol*. 2014;10(3):506-510.

**Access this article online**

<http://pediatricurologycasereports.com>

**Quick Response Code**

