



---

## Pelvioureteric junction obstruction of the lower collecting system associated with incomplete ureteral duplication: A case report

Hulya Ozturk, Emine Dagistan, Serkan Ozturk, Hayrettin Ozturk

---

**Abstract** In cases with incomplete ureteric duplication, lower pole ureteropelvic junction obstruction (UPJO) may occur as an unusual entity. Surgical reconstruction of UPJO can be with different techniques such as pyeloplasty, pyeloureterostomy or ureteroureterostomy. In our case, the connecting segment distal to the pelvioureteric junction was found short and we performed direct pyeloureteral side-to-side anastomosis, with a double j catheter. It is helpful to determine prior to reconstruction of a short lower pole ureteral length.

**Key Words** Ureteric duplication; incomplete ureteric duplication; children; ureteropelvic junction obstruction; pyeloureterostomy.

© 2014 pediatricurologycasereports.com. All Rights Reserved

---

*From the Department of Pediatric Surgery and Pediatric Urology and Radiology Abant Izzet Baysal University, Medical School, Bolu, Turkey.*

**Corresponding Author:** Hulya Ozturk-Prof. M.D. Abant Izzet Baysal University, Medical School, Department of Pediatric Surgery, Bolu, Turkey

*E mail: [hulya\\_ztrk@yahoo.com](mailto:hulya_ztrk@yahoo.com)*

*Accepted for publication 03 October 2014*

---

### INTRODUCTION

Ureteral duplications are a common anomaly reported in the incidence approximates 1 in 125. [1,2]. A ureteral duplex system can be a

partial or incomplete duplication in which a single ureter enters the bladder and they seen slightly as more prevalent. Duplications may be manifest with symptoms such as hydronephrosis, urinary tract infections (UTI) incontinence, and urinary tract obstruction. Additionally, partial duplications are generally discovered

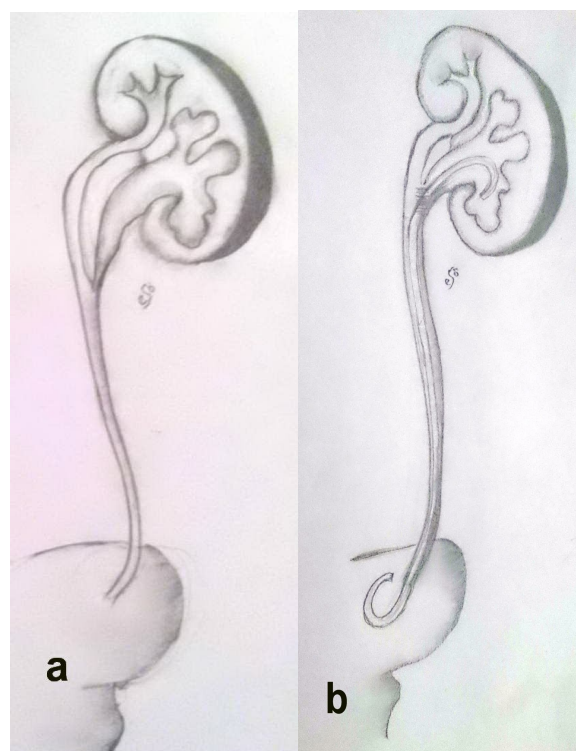
incidentally; however, to diagnose ureteral duplication requires highly suspect [2,3]. In cases with incomplete duplication, lower pole ureteropelvic junction obstruction (UPJO) may occur as an unusual entity, and a side-to-side anastomosis of the obstructed lower pole pelvis to the upper pole ureter is applied as a surgical intervention [3,4,5]. However, the incomplete ureteral duplication associated with obstruction may be technical difficulties when the junction of the upper pole and lower pole ureters are proximally located and in close proximity to the lower pole UPJ [6].

Here, we presented a case of our experience on diagnosis and management challenging of lower pole UPJO in a 5-year-old boy.

### CASE REPORT

A 5-year-old boy was referred for evaluation of abdominal pain and urinary tract infection (UTI). Ultrasonography showed a left hydronephrosis with suspicion of a duplicated system. Blood tests, including blood urea nitrogen and creatinine were found at normal levels. The voiding cystourethrogram (VCUG) result was

normal. A lasix DTPA renal scan demonstrated delayed clearance consistent with an obstructed lower-pole UPJ obstruction. In case our, ureteral length was not sufficient and a pyeloureterostomy (PU) was performed joining the pelvis of the lower pole moiety to the ureter of the upper pole and double J catheter was inserted. (Fig.1a,b). Postoperative ultrasound and renal scan studies repeated at 3-6 months showed decompression of the lower pole with no evidence of obstruction.



**Fig. 1.** Representation with a graphic (a) pre and (b) postoperative of lower pole ureteropelvic junction obstruction.

## DISCUSSION

Ureteral duplications are the most common anomaly of the urinary tract. In autopsy series of the urinary tract, the overall incidence of duplication is 0.7% and, complete duplication is 0.2% [7]. The both kidneys are affected equally by ureteral duplication, and bilateral duplication occurs in approximately 40% of patients [8]. Partial ureteral duplication results from a ureteral bud bifurcating after its origin from the mesonephric duct. A ureteral bud that bifurcates early results in a partial duplication [3]. As in the case presented here, obstruction in the left kidney lower pole moiety can be found as secondary to UPJO.

The diagnosis of obstruction in incomplect duplication may be difficult and, most of them are discovered incidentally. In the study pre or postnatal ultrasonography, they may be detected a hydronephrotic lower pole with normal parenchyma in the upper pole. The functional status of the duplicate kidney should be obtained by a

renal scan. If the diagnosis of duplicated system is uncertain, intravenous pyelogram may be useful. Fehrenbaker et al [9] demonstrated that reflux was found in more than two-thirds of children with complete duplex systems who were seen because of a UTI. VCUG establishes the diagnosis by showing a duplex renal system with VUR. Additionally, a retrograde pyelogram in operation is helpful in completely defining of the anatomy and planning of the surgical technique [8]. A bifid renal pelvis may be the result of the highest level of bifurcation and occurs in about 10% of the patients. Of the other incomplete ureteral duplications, approx 25% divide in the proximal third, 50% divide in the middle, and 25% divide in the distal third of the ureter [3].

When surgery is needed for a highest proximal incomplete duplication, an ureteropyelostomy or ureteroureterostomy at the renal level is therapeutic [10]. Sometimes, ureteropelvic junction obstruction may be found in association with incomplete duplex systems [5]. Generally

the lower pole ureter is narrowed, and a side-to-side anastomosis of the obstructed lower pole pelvis to the upper pole ureter is required. VanderBrink et al. [6] suggested that the length of ureter between the UPJ and junction of the lower pole and upper pole ureter was the major determinant of reconstructive technique. A short lower pole ureteral length is more suited to pyeloureterostomy whereas longer lengths allowed for consideration and performance of standard dismembered pyeloplasty. It is helpful to determine this status with retrograde ureteropyelography immediately prior to reconstruction.

In this study, our case was diagnosed by ultrasonography and renal scan. However, the shortness of the lower pole ureter was detected during the operation. In this new

situation, the surgical repair may be complicate. Intravenous urography in defining the lower pole ureter shortness can provide partial information, but the study of retrograde ureteropyelography can be useful. As a results, in the presence of the lower pole UPJO in a patient with incomplete ureteral duplication, the length of ureter between the UPJ and junction of the lower pole and upper pole ureter is important in surgical selection. We have found that pyeloureterostomy is a safe and effective to drainage of the obstructed lower pole.

#### **CONFLICT OF INTEREST**

**None declared.**

#### **REFERENCES**

1. Nation EF. Duplication of the kidney and ureter: a statistical study of 230 new cases. *J Urol.* 1944; 51:456–65.
2. Schluskel RN, Retik AB. Ectopic ureter, ureterocele and other anomalies of ureter. In: Wein A, Novick AC, Kavoussi LR, Partin AW, Peters CA, (eds). *CampbellWalsh urology.* 9th ed. Saunders Elsevier; 2007. p. 3383e422.

3. Cooper CS. Duplicated Ureters and Ureteroceles. Edited by John P. Gearhart. Pediatric Urology. Humana Press Inc. Totowa, New Jersey; 2003. pp 185-210
4. Maizels M, Smith CK, Firlit CF. The management of children with vesicoureteral reflux and ureteropelvic junction obstruction. J Urol. 1984;131(4):722-7.
5. Ossandon F, Androulakakis P, Ransley PG. Surgical problems in pelvioureteral junction obstruction of the lower moiety in incomplete duplex systems. J Urol. 1981;125(6):871-2.
6. VanderBrink BA, Cain MP, Gilley D, Meldrum KK, Rink RC. Reconstructive surgery for lower pole ureteropelvic junction obstruction associated with incomplete ureteral duplication. J Pediatr Urol. 2009;5(5):374-7.
7. Ulchaker J, Ross J, Alexander F, Kay R. The spectrum of ureteropelvic junction obstructions occurring in duplicated collecting systems. J Pediatr Surg. 1996;31(9):1221-4.
8. Timothy RP, Decter A, Perlmutter AD. Ureteral duplication: clinical findings and therapy in 46 children. J Urol. 1971;105(3):445-51.
9. Fehrenbaker LG, Kelalis PP, Stickler GB. Vesicoureteral reflux and ureteral duplication in children. J Urol. 1972;107(5):862-4.
10. Amar AD. Ureteropyelostomy for relief of single ureteral obstruction in cases of ureteral duplication. Arch Surg. 1970(3);101:379-81.