



## Removal of proximally migrated double J ureteric stent through a percutaneous nephrostomy route in an infant

Nirmalya Ray<sup>1</sup>, Ujjwal Gorsil<sup>1</sup>,  Tejeshwar Singh Juggal<sup>1</sup>, Ravi Prakash Kanojia<sup>2</sup>, Manavjit Singh Sandhu<sup>1</sup>

<sup>1</sup>Department of Radiodiagnosis and Imaging, Post Graduate Institute of Medical Education and Research (PGIMER), Chandigarh, India

<sup>2</sup>Department of Pediatric Surgery, Post Graduate Institute of Medical Education and Research (PGIMER), Chandigarh, India

### ABSTRACT

Proximal migration of double J-stent (DJ stent) can be a reason for failure of its cystoscopic removal. Antegrade percutaneous nephrostomic removal of the stent can be done in such cases. Although the technique is described in adults and older children, the technique requires some modification when used in infants because of smaller calibre of pelvicalyceal system. Here we describe a case of a 6 month old male child who was treated by robotic assisted pyeloplasty for left sided ureteropelvic junction obstruction followed by placement of DJ stent. Cystoscopic removal of the stent 6 weeks after surgery was not possible due to proximal migration of the stent. Hence, antegrade percutaneous nephrostomic removal of the stent was performed using micro-snare. Certain novel technical modifications, like advancement of a diagnostic angiographic catheter in pelvicalyceal system, has been used in this case to reduce the risk of urothelial injury. Thus, antegrade removal of DJ stent with few technical modifications can be used safely in infants for removal of proximally migrated stents.

**Key Words:** Double J-stent, ureteral stent, migration, percutaneous removal.

© 2020 [pediatricurologycasereports.com](http://www.pediatricurologycasereports.com)

✉ Dr. Ujjwal Gorsil

Department of Radiodiagnosis and Imaging, Post Graduate Institute of Medical Education and Research (PGIMER), Chandigarh, India.

E-mail: [ujjwalgorsil@gmail.com](mailto:ujjwalgorsil@gmail.com)

Received: 2020-04-07 / Revisions 2020-04-26

Accepted: 2020-05-03 / Publication Date: 2020-07-01

### Introduction

Placement of double J (DJ stent) ureteral stent following pyeloplasty for ureteropelvic junction obstruction is a commonly performed procedure for achieving internal urinary

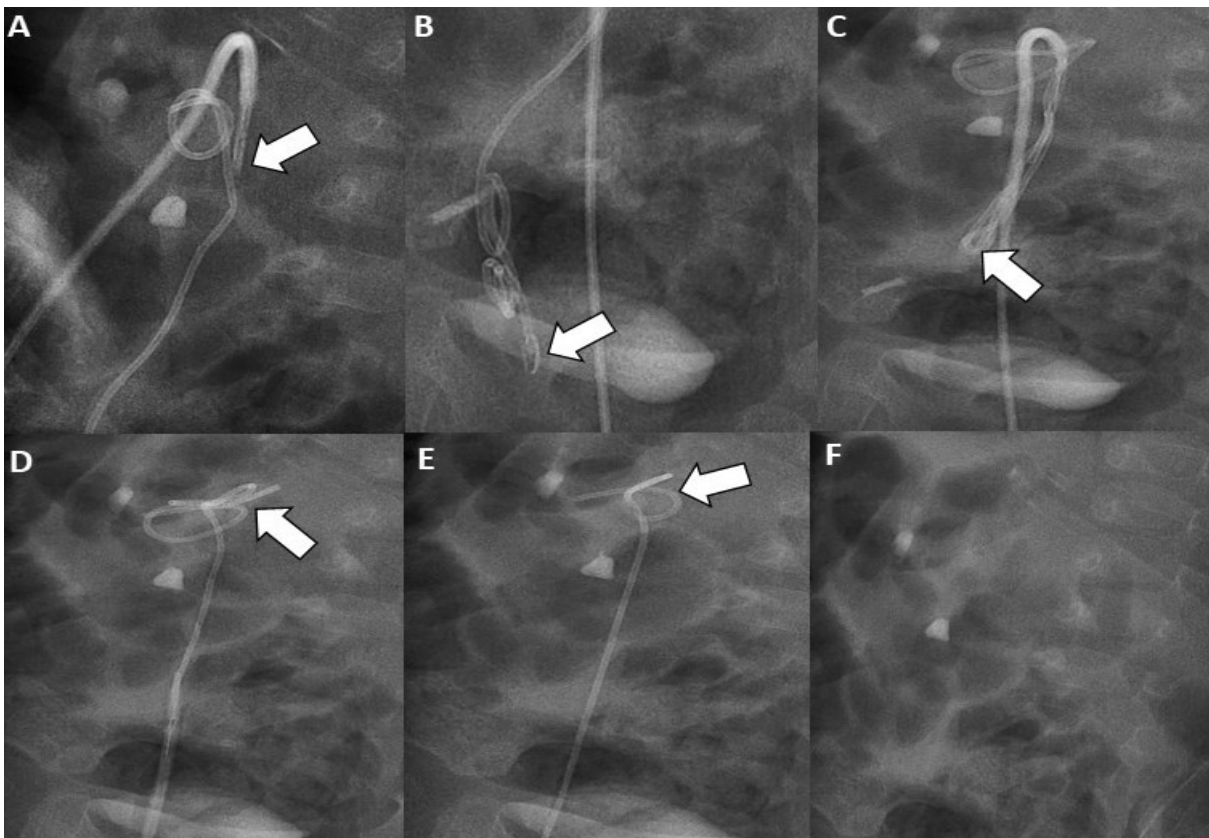
diversion [1]. Eventually these stents are removed electively (as an end point to treatment) or because of associated complications like stent obstruction, fragmentation, migration or erosion into adjacent organs [2,3]. Conventionally retrograde cystoscopic route is the preferred route for removal of these stents [2,3]. However, the conventional method of retrograde cystoscopic stent removal may not be feasible in presence of proximal stent migration, distorted anatomy secondary to

urinary diversion or previous bladder surgeries [2-4]. Antegrade percutaneous nephrostomic removal of the ureter stent can be used as a bailout technique in these cases and is well described in the literature [2-4]. However, our case was unique as it was performed in an infant which required certain modifications in standard technique.

### Case report

A 6 months old male child, who was diagnosed to have left ureteropelvic junction obstruction antenatally, underwent robotic assisted pyeloplasty followed by placement of DJ ureteral stent. He was planned for cystoscopic removal of the stent after 6 weeks. However, because of proximal migration of the stent, retrieval by retrograde route was not possible.

Hence, antegrade removal of the ureteric stent via percutaneous nephrostomy route was planned. The procedure was performed under general anesthesia after obtaining informed consent from the child's parents. The child was placed in right lateral position and access to the left lower polar calyceal system was obtained using an 18 G lumbar puncture needle and a 6F femoral access sheath (Avanti; Cordis, Bridgewater, New Jersey) was placed into the pelvicalyceal system. Position of the arterial sheath was confirmed by injection of non-ionic iodinated contrast material (iohexol, Omnipaque 300, GE Healthcare Inc, Princeton, NJ, USA) which showed opacification of the pelvicalyceal system. A 5F RC2 catheter (Cook, Bloomington, IN, USA) is advanced through the arterial sheath into the



**Fig. 1. A-F.** Fluoroscopic store images showing sequential capture of the DJ stent with micro-snare. (A) Introduction of the micro-snare (arrow) through the 5F RC2 catheter. (B) Distal end of the DJ stent grasped by the micro-snare (arrow). (C)- (E) Gradual removal of the DJ stent by microsnare. (F) Status after complete removal of DJ stent from pelvicalyceal system.

renal pelvis. A 5 mm Amplatz gooseneck microsnares tip (Plymouth, MN, USA) was advanced through the RC2 catheter into the pelvicalyceal system and downstream into the left ureter. The tip of the DJ stent was grasped using the microsnares and the entire system including the arterial sheath is taken out. The sequential steps in the procedure is demonstrated in Fig 1A-1F. Under ultrasound and fluoroscopic guidance, a 6F percutaneous nephrostomy catheter (Devoncath, Bengaluru, India) was placed into the lower polar calyx as hematuria was anticipated subsequently. The child had mild hematuria after the procedure which resolved over next 3 days with conservative management. Subsequently, the percutaneous nephrostomy catheter was removed and child was discharged.

### **Discussion**

Percutaneous antegrade nephrostomic removal of ureteral stent is well described in literature and generally considered a safe procedure despite few reported complications like nephrostomy wound infection, pelvicalyceal system injury, and clot in renal pelvis [2-7]. Major studies in this regard have described the use of 8F or 9F vascular access sheath placed through a percutaneous nephrostomic route and removal of the DJ stent using micro-snares or foreign body removal forceps [2,3,6]. However, the patient population included in these studies were adults [2,3], and certain technical modification should be done while performing this maneuver in children particularly in infants to reduce the chance of urothelial injury, which is more likely in pediatric population because of smaller capacity of the pelvicalyceal system. Hence, a smaller dimension of vascular access sheath was used in this case to minimize the risk of pelvicalyceal system injury. Similar use of 6F

vascular access sheath in a 9 month old infant for removing coiled DJ stent in pelvis was described in one of the case reports [5]. However, the introduction of a 5F diagnostic catheter into the pelvis rather than advancing the vascular access sheath itself is a novel technical modification for reducing risk of urothelial injury and is not described in literature.

Bronchoscopic forceps was used for removal of the stents in the previous cases described by Lal et al [5], as in those cases the DJ stent was coiled into the renal pelvis and can be accessed by the semi-rigid bronchoscopic forceps keeping the forceps within the vascular access sheath. In our case, the tip of the DJ stent was lying in the distal ureter and hence, advancing a bronchoscopic forceps would have increased the likelihood of urothelial injury owing to less capacious pelvicalyceal system and ureter in the infant. Hence, we used a micro-snare to catch the tip of the DJ stent. The introduction of a 5F RC2 catheter helped by providing additional stability for introduction of micro-snare into the pelvicalyceal system. Moreover, as the tip of the RC2 catheter is inferiorly pointed, it also helped in advancing the micro-snare into the ureter. In case it was not possible to capture the DJ stent with the micro-snare, pushing of the DJ stent distally with the help of a guidewire could have been considered to facilitate its cystoscopic removal later.

### **Conclusion**

Antegrade percutaneous nephrostomic route is a safe procedure that can be used as a bailout technique for removal of proximally migrated double J ureteral stents in infants with certain technical modifications like introduction of a 5F diagnostic angiographic catheter into the pelvicalyceal system through a smaller size of vascular access sheath.

**Compliance with ethical statements**

*Conflicts of Interest:* None.

*Financial disclosure:* None.

*Consent:* Informed and written consent were taken from patient and her parents to publish this case report.

**ORCID iD of the author (s)**

Nirmalya Ray / 0000-0002-8149-6735

Ujjwal Gorski / 0000-0002-1713-8327

Tejeshwar S Jugpal / 0000-0003-0437-9612

Ravi P Kanojia / 0000-0002-7521-9256

Manavjit S Sandhu / 0000-0001-6365-6291

**References**

- [1]Kulkarni AA, Kothari P, Gupta A et al. Forgotten DJ stents with calculi in a double moiety re-implant: A case report. *Pediatr Urol Case Rep.* 2017; 4(1):253-55.
- [2]Shin JH, Yoon HK, Ko GY, et al. Percutaneous antegrade removal of double J ureteral stents via a 9-F nephrostomy route. *J Vasc Interv Radiol.* 2007;18(9):1156-61.
- [3]Liang HL, Yang TL, Huang JS, et al. Antegrade retrieval of ureteral stents through an 8-French percutaneous nephrostomy route. *AJR Am J Roentgenol.* 2008;191(5):1530-35.
- [4]Jayakumar S, Marjan M, Wong K, et al. Retrieval of proximally migrated double J ureteric stents in children using goose neck snare. *J Indian Assoc Pediatr Surg.* 2012;17(1):6-8.
- [5]Lal A, Singhal M, Narasimhan KL, et al. Percutaneous retrieval of coiled double-J stent from renal pelvis after Anderson-Hynes pyeloplasty: report of two cases. *J Pediatr Urol.* 2012;8(3):e19-22.
- [6]Boren SR, Dotter CT, McKinney M, et al. Percutaneous removal of ureteral stents. *Radiology.* 1984;152(1):230-31.

- [7]Shin JH, Yoon HK, Ko GY, et al. Percutaneous antegrade removal of double J ureteral stents via a 9-F nephrostomy route. *J Vasc Interv Radiol.* 2007;18(9):1156-61.