

## Simple intratesticular cyst: A rare finding amenable to testis-sparing surgery

Jessica N. Jackson<sup>1</sup>, Rebecca S. Zee<sup>1</sup>, C.D. Anthony Herndon<sup>2</sup>

<sup>1</sup>Department of Urology, University of Virginia, Children's Hospital, Charlottesville, VA, USA

<sup>2</sup>Department of Surgery, Division Pediatric Urology, Virginia Commonwealth University, Richmond, VA, USA

### Abstract

Simple intratesticular cysts (SIC) are rare in infancy. There is a paucity of data with regards to management. Concern for malignancy often prompts the pediatric urologist to perform a radical orchiectomy which may impact endocrine function and fertility potential later in life. Recently, there has been a movement towards testis-sparing surgery for SIC. Herein, we describe a case of a 7-month-old infant who presented to pediatric urology clinic with left intraparenchymal SIC that was treated with a testis-sparing approach. In summary, this case report supports the use of testis-sparing surgery for management of preoperatively well-defined SIC.

### Keywords

Intratesticular cyst; testis mass; infant testis mass.

Copyright © 2016 [pediatricurologycasereports.com](http://www.pediatricurologycasereports.com).

### Corresponding Author:

Rebecca Zee, MD, PhD

PO Box 800422, Charlottesville, VA 22908, USA

Email: [rz2r@hscmail.mcc.virginia.edu](mailto:rz2r@hscmail.mcc.virginia.edu)

Accepted for publication: 30 September 2016

neonatal diagnosis of a simple testicular cyst and advocated testicular sparing surgery [1]. Herein, we report a case of SIC in a 7-month-old successfully managed with testis-sparing surgery.

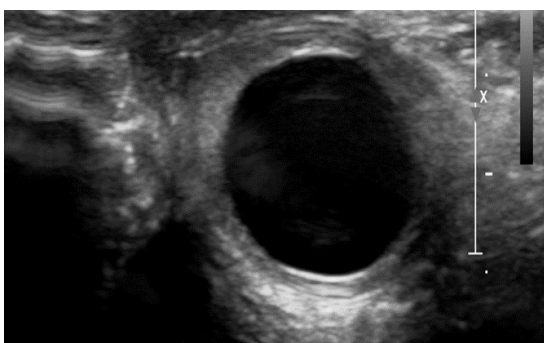
### Introduction

Simple intra-testicular cysts (SIC) in childhood are an uncommon finding. There are approximately 50 reported cases in the literature, with only about 10 cases reported in children under 2 years of age. Slaughenhaupt et al. reported the first

### Case Report

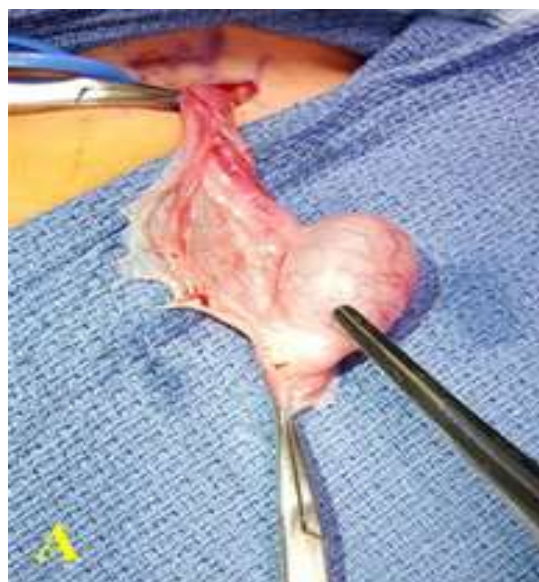A 7-month-old male was incidentally discovered to have a left simple intratesticular cyst (SIC) during an evaluation for fever of unknown origin at an outside hospital. The pediatrician noted new

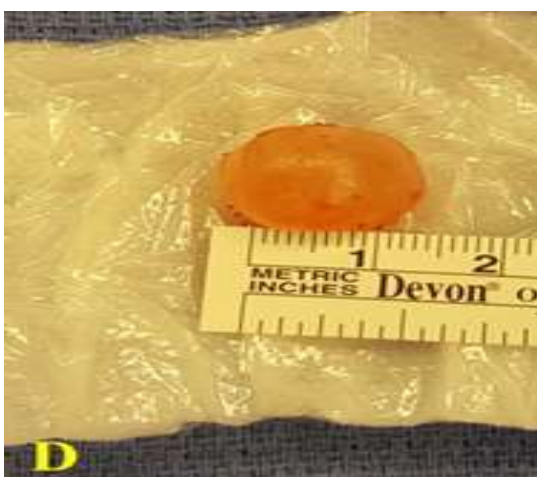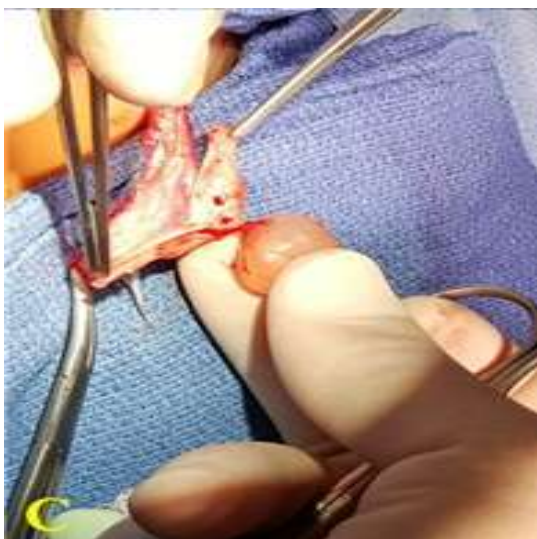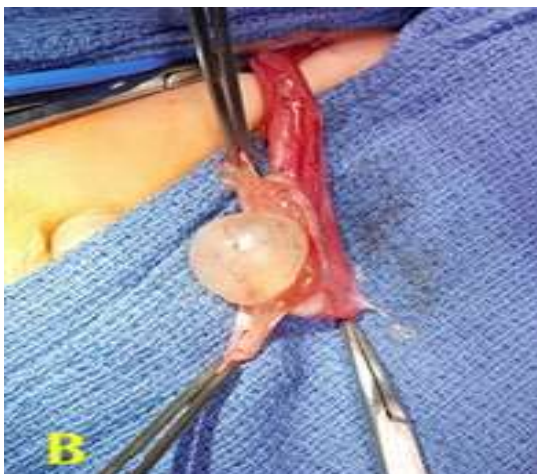onset left testicular enlargement on exam. The child had no history of trauma, urinary tract infections, or hematuria. Both testes were descended and symmetric at birth. He had no family history of undescended testis or testicular cancer. He presented to the urology clinic shortly thereafter for scrotal evaluation. Upon examination the child's left testis was considerably larger than the right and felt somewhat tense on palpation. Tumor markers revealed an AFP 17.1 ng/mL and an HCG <1.2 U/L. An ultrasound demonstrated a left simple intratesticular cyst, approximately 15 mm x 10 mm, within the testicular capsule that appeared to be compressing the normal testicular parenchyma. There was a hyperechoic rim and posterior acoustic amplification. There did appear to be substantial and normal looking testicular tissue immediately adjacent to the cyst [Fig. 1].



**Fig. 1.** Left intratesticular cyst approximately 15 mm x 10 mm displaces the normal testicular parenchyma.

After discussion with the family we elected to remove the cystic mass by enucleation. An inguinal approach was taken for excision. The testis was extracted from the inguinal incision and a vessel loop tourniquet was used for vascular control. After the tunica vaginalis was opened the testis appeared tense with a tightly adherent epididymis. A longitudinal incision was made in the tunica albuginea and carefully extended into the testicular tissue until the cyst was visualized. The cyst was then gently dissected away from the normal testicular tissue with tenotomy scissors. The cyst was enucleated [Fig. 2A,B,C,D]. The tunica albuginea and remaining testicular tissue was then closed primarily. The remaining tissue had good blood flow with release of the tourniquet.

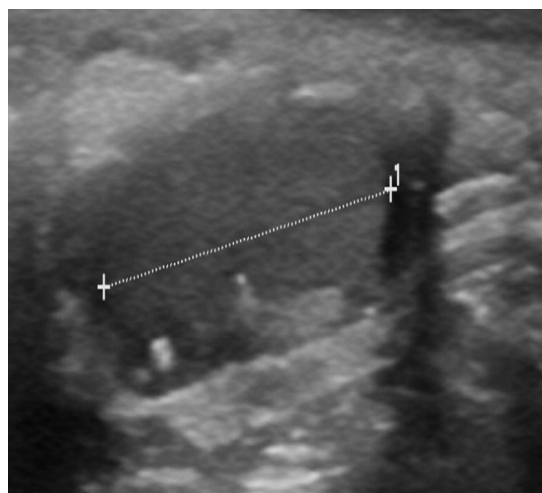




**Fig. 2.** A) Left testis with tunica albuginea opened and everted demonstrating densely

adherent epididymis. B) Sharp dissection through testicular parenchyma exposes the SIC. C) Isolation of SIC from left testicular parenchyma reveals no communication with tunica albuginea. D) SIC after enucleation.

The gross pathology from this specimen revealed a benign intratesticular cystic structure measuring 16 mm in diameter, filled with clear serous fluid. Microscopic pathology also correlated with a benign cyst. He did well postoperatively and made a full recovery at his 3 month follow-up visit with no evidence of recurrence on scrotal US [Fig. 3].



**Fig. 3.** Left testis at 3 month follow-up demonstrates no evidence of recurrence. The testis is 16 mm in longitudinal dimension.

### Discussion

Testicular cysts are a rare finding in the pediatric population. Both cysts and

testicular tumors can present as painless testicular mass. Testis cysts are often an incidental finding on ultrasound evaluation and may not be palpable due to size [2]. Once discovered, tumor markers, AFP, and alpha fetoprotein levels should be checked to rule out malignancy.

The differential diagnosis of testis mass includes SIC, cystic teratoma, cystic lymphangioma, and epidermoid cyst [3–6]. Testis tumors are 10 times less common in prepubertal population with incidence of 0.5 to 1 per 100,000 [7,8]. Benign cystic teratomas can be managed similarly to testis cysts given the ability to perform serial ultrasound examinations post-operatively [3].

Prior to the advent of ultrasound radical orchiectomy was advocated for testis mass. However, with detailed ultrasonographic findings confirming the presence of a simple cyst the surgeon may proceed with testis-sparing surgery. On ultrasound, a cyst will be anechoic and round with an echogenic rim and posterior acoustic enhancement [1,4,9].

Pathologically, the cyst contains simple serous fluid. The cyst wall will not involve the tunica albuginea. It is lined with cuboidal or simple flattened epithelium [6,10]. The origin of testicular cyst is unclear. They may arise from seminiferous

tubules or coelomic epithelium that became embedded in testicular parenchyma during fetal development [1]. Others have speculated an association with prior testis inflammation or trauma [11].

Although there is a paucity of data in regards to management of a testicular cyst, recent literature advocate for a testis sparing approach if a testicular lesion has sonographic features of a cyst and negative tumor markers [1,5]. Hoag et al. reported a case series of 7 patients with intratesticular cysts. Six underwent a testis-sparing approach via inguinal incision and the seventh patient had spontaneous resolution with serial imaging. All patients who underwent surgery had final pathology consistent with epidermoid cyst or cystic teratoma. None had evidence of testicular atrophy or malignancy during follow-up [6]. Interestingly, two patients in this series had cystic teratoma with adjacent intratubular germ cell neoplasia (ITGCN) which is of unknown significance with regard to future tumorigenic potential in this patient population. Our patient differs from this series in that it was a simple cyst but still substantiates the utility of a testis sparing approach.

In conclusion, simple intratesticular cysts (SIC) are an uncommon finding in the pediatric population. Ultrasound imaging

facilitates characterization of intratesticular masses prior to surgical management. For masses that are characterized as simple cyst, do not involve the tunica albuginea and have a hyperechoic rim, testis-sparing surgery via inguinal incision and enucleation of the cyst

has been demonstrated to be an effective approach.

### Acknowledgements

The author(s) declare that they have no competing interests and financial support.

### References

1. Slaughenhaupt B, Klauber G. Simple Testicular cyst in the Neonate. *J Pediatr Surg.* 1995;30(4):636–7.
2. Hoag N a., Afshar K, Youssef D, Masterson JST, Murphy J, MacNeily AE. Cystic intratesticular lesions in pediatric patients. *J Pediatr Surg.* 2013;48(8):1773–7.
3. Garrett JE, Cartwright PC, Snow BW, Coffin CM. Cystic testicular lesions in the pediatric population. *J Urol.* 2000;163(3):928–36.
4. Rubenstein RA, Dogra VS, Seftel AD, Resnick MI. Benign Intrasrotal Lesions. *J Urol.* 2004;171(5):1765–72.
5. Liniger B, Fleischmann A, Zachariou Z. Benign cystic lesions in the testis of children. *J Pediatr Urol.* 2012;8(3):226–33.
6. Hoag NA, Afshar K, Youssef D, Masterson JS, Murphy J, Macneily AE. Cystic intratesticular lesions in pediatric patients. *J Pediatr Surg.* 2013;48(8):1773–7.
7. Brosman SA. Testicular tumors in prepubertal children. *Urology.* 1979;13(6):581–8.
8. Pohl H, Shukla A, Metcalf P, Cilento B, Retik A, Bagli D, et al. Prepubertal Testis Tumors: Actual Prevalence Rate of Histological Types. *J Urol.* 2004;172(6 Pt 1):2370–2.
9. Al-Jabri T, Misra S, Maan ZN, Khan K, Coker C, Thompson P. Ultrasonography of simple intratesticular cysts: a 13 year experience in a single centre. *Diagn Pathol.* 2011;6:24.
10. Casaccia G, Spagnoli A, Ferro F. Simple intratesticular cyst in infancy: testis sparing surgery by a scrotal approach. *Urology.* 2000 ; 56 (5) : 854–5.

11. Shergill IS, Thwaini A, Kapasi F, Potluri BS, Barber C. Management of simple intratesticular cysts: a single-institution 11-year experience. *Urology* 2006;67:1266–8.

