




PEDIATRIC UROLOGY CASE REPORTS

ISSN 2148-2969

<http://www.pediatricurologycasereports.com>**Spontaneous resolution of urinary calculi in a congenital solitary kidney: A case report**John F. Fahy¹, Nicholas R. Rocco², Matthew S. Christman²¹Uniformed Services University, School of Medicine, United States²Department of Urology, Naval Medical Center San Diego, United States**ABSTRACT**

Spontaneous resolution of a large renal stone burden in adults is a rare occurrence with few reports in the last 50 years. Improved imaging techniques and understanding of the pharmacology of dissolution therapy have led to a better understanding of which stones have the potential for spontaneous passage or targeted dissolution via medical treatment. Less is known regarding stone outcomes in children, and anecdotes of pediatric patients spontaneously passing large stones has been widely propagated. Here we report a case of spontaneous resolution of a large renal stone burden in a child with a congenital solitary kidney.

Key Words: Spontaneous resolution, spontaneous passage, spontaneous dissolution, solitary kidney, large renal stone burden.

Copyright © 2019 [pediatricurologycasereports.com](http://www.pediatricurologycasereports.com)

Correspondence: Dr. John F. Fahy,
Uniformed Services University, School of Medicine,
United States.

E mail: jffahy@gmail.com

ORCID ID: <http://orcid.org/0000-0002-9856-3631>

Received 2019-04-14, Revised 2019-05-09

Accepted 2019-05-21

Publication Date 2019-07-01

Introduction

The management of pediatric nephrolithiasis has evolved rapidly over the last several decades due to the dramatic worldwide increase in incidence [1]. Detection via enhanced imaging techniques has provided the ability to determine which stones may pass spontaneously, most likely with stones less than 3mm [2], or could be managed conservatively with dissolution therapy. Dissolution therapy takes advantage of the

physiological properties of the kidney in order to alter the chemical environment within the nephron. Stone dissolution could occur spontaneously if the physiological conditions within the kidney were altered due to factors other than medical intervention. There is not extensive research or case studies on the spontaneous dissolution of stones, with the most notable cases occurring greater than 50 years ago [3]. Below we report the first case of the spontaneous resolution of a large kidney stone burden in a pediatric patient with a congenital solitary kidney.

Case report

A 10-year-old Caucasian boy presented acutely with a one-day history of fevers, nonbilious, non-bloody emesis, and worsening

wheezing. His medical history was notable for congenital solitary kidney, translocation between chromosomes 11 and 14, and developmental delays. He had no history of nephrolithiasis. He had normal vital signs with a benign abdomen and no costovertebral angle tenderness. Laboratory evaluation revealed a leukocytosis of $17.2 \times 10^9/L$ and a rise in serum creatinine from 0.7 to 2.2 mg/dL. Urinalysis and microscopy revealed a pH of 5.0 with 4 RBCs/hpf and 31 WBCs/hpf. A contrast enhanced abdominal and pelvic computed tomography (CT) scan demonstrated a proximal obstructing left ureteral stone measuring 1.0 cm with HU of 487 (Fig. 1) along with multiple large non-obstructing nephrolithiasis (Fig. 2).

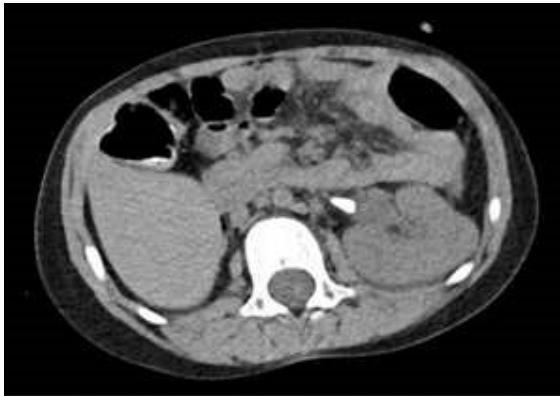


Fig. 1. Axial CT scan showing proximal obstructing left ureteral stone measuring 1.0 cm.

Findings were consistent on renal bladder ultrasound. Concern for obstructive pyelonephritis and obstructive uropathy prompted a urine culture, the administration of piperacillin/tazobactam, and ureteral stent placement. Antibiotics were transitioned to ceftriaxone and his acute kidney injury and leukocytosis resolved over the next several days. Urine culture returned 2,000 cfu/mL of

gram-negative growth, no speciation. He was discharged home on POD#5 with a course of trimethoprim/sulfamethoxazole and plans for definitive stone treatment by ureteroscopy two weeks later.

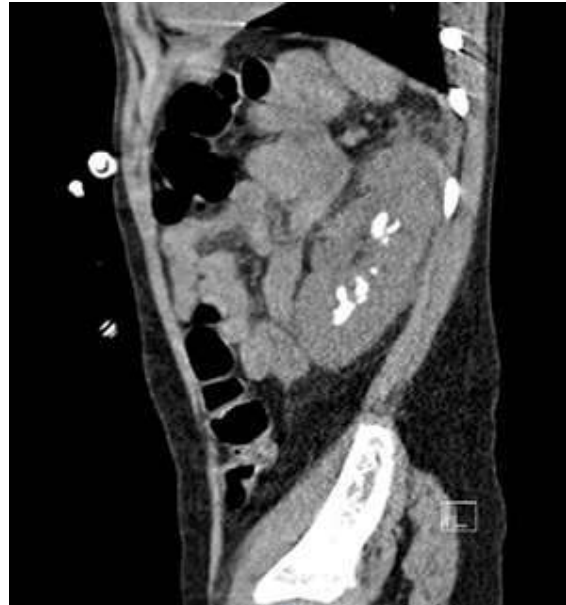

Fig. 2. Sagittal CT scan showing multiple large non-obstructing nephrolithiasis.

The patient tolerated his stent through the day of his ureteroscopy, 17 days after initial presentation. Parents denied the presence of any stones in the patient's diapers. Intraoperatively, cystoscopy with retrograde pyelogram revealed no filling defects. During ureteroscopy no stones or anatomic abnormalities were noted.

A urinalysis revealed a urine pH of 7.0. A 24-hour urine collection obtained on the first post-operative day revealed hypocitraturia with a pH of 7.1 and a total volume of 700 mL. Serum uric acid was $3.7 \mu\text{mol/L}$. An ultrasound of the left kidney was performed on post-operative day 2 and was negative for any identifiable stone burden or hydronephrosis (Fig. 3).

At a four-week follow-up appointment the patient had no new complaints or indications of stone recurrence.

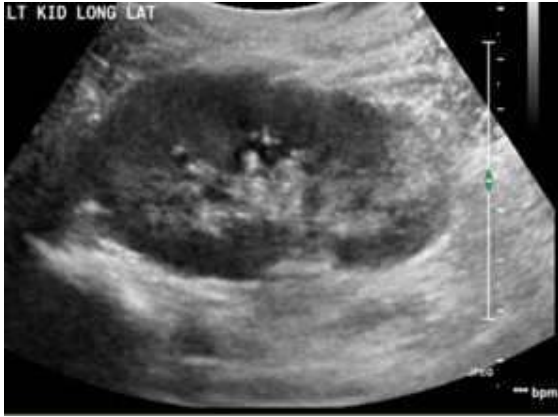

Fig. 3. Ultrasound performed post-operative day 2.

Discussion

Our patient presented with an obstructive uropathy secondary to a heavy stone burden, which spontaneously and completely resolved within 2.5 weeks. The two rational explanations are that the stones either passed or dissolved. Passage seems unlikely given the volume of stone burden and stone size, however, despite a paucity of literature some urologists would argue that pediatric patients are able to pass large stones. Dissolution appears to be the only feasible solution, despite the fact that no attempt was made to alkalinize his urine.

In a study of 80 patients, spontaneous stone passage was observed in 34% of patients younger than 10 years and 29% of patients 10 years or older. Mean size of passed stones was 3.2 mm in the younger group and 2.5 mm in the older group [4]. Similar findings were noted in a retrospective analysis of 119 prepubertal children with symptomatic urolithiasis [5]. The specific time needed to pass the stones was not reported, but all stones were passed within 6 months.

Given our patient's heavy renal stone burden it is unlikely that the stones passed spontaneously within 2.5 weeks. The more probable explanation is that the stones had

spontaneously dissolved. This would have been most likely if the patient's stones were milk of calcium or uric acid.

Milk of calcium stones are a viscous colloidal suspension of calcium salts commonly associated with a calyceal diverticulum. On radiographs, milk of calcium stones are faintly opaque or radiolucent, in dependent positions with possible semi-lunar pattern or layering, and have HU ranging from 114-612 [6]. Our patient's stones were well formed without any evidence of layering or semilunar shape. The only characteristic consistent with our patient is the density as measured by HU, making milk of calcium stones unlikely.

Dissolution of stones most commonly occurs with uric acid stones, however, in children, only approximately 1% of stones are uric acid [7]. Risk factors for uric acid stone formation include low volume of urine output and acidic urine; both promote uric acid precipitation. At a pH greater than 6.5 up to 90% of uric acid is soluble in urine, which serves as the rationale for the dissolution therapy of uric acid stones. For our patient, the urine pH of 5.0 on initial presentation and low HU on CT scan would suggest that his were uric acid stones.

The time between the initial presentation and the observed resolution of the stones is also much shorter than what has been observed previously. In reported cases the time for stone dissolution ranged from several months to several years [3]. However, an *in vitro* study evaluating the dissolution kinetics of uric acid calculi estimated that at a constant pH of 7.0, the time for complete *in vivo* dissolution is 4.4 days for 1 cm of stone burden [8]. Based on the imaging obtained for our patient, he had an estimated 4 cm of stone burden. In an ideal environment our patient's stones could have spontaneously dissolved in approximately 18 days. Given the 17 days between initial

presentation and definitive ureteroscopy it is feasible that the patient's stones spontaneously dissolved.

In children who present with stones, 34-50% will be found to have some underlying metabolic cause [9]. His only abnormality seen on 24-hour urine collection was hypocitraturia. Citrate acts as a urinary inhibitor of the crystallization of several stone-forming salts, and hypocitraturia can be found in up to 20% to 60% of stone formers [10]. While it is a potential factor in the formation of stones in this patient, it does not aid in explaining the spontaneous resolution of a heavy stone burden.

Lastly, the only interventions prior to negative ureteroscopy were antibiotic therapy and stent placement. Trimethoprim is a weak base, with 50% to 60% being excreted in the urine within 24 hours [11]. It is possible that this weak base had some effect on the dissolution of his uric acid calculi. His urine pH may also have been changed by improved renal function after placement of the stent. Children with solitary kidneys are more susceptible to acidotic events after urinary obstruction. Relief of the obstruction may have resulted in autoalkalinization and stone dissolution.

Conclusion

In conclusion, we present a case of spontaneous resolution of urolithiasis in a child with unilateral renal agenesis. In this case, the spontaneous resolution occurred within 2.5 weeks in the absence of any targeted dissolution therapies. Spontaneous passage is unlikely given the significant stone burden at presentation. Despite the common belief that children can pass large stones, there is a paucity of literature supporting the passage of stones larger than 3.5 mm. Antibiotic therapy with trimethoprim, and/or autoalkalinization

following relief of the obstruction with the ureteral stent could have played a role in stone resolution. Close follow-up will be required for early identification of any recurrence.

In children with underlying genetic/metabolic abnormalities and a solitary kidney, consideration should be given to repeat imaging after stenting, but prior to stone intervention. Some clinicians may have approached this patient with percutaneous nephrolithotomy, which would have added additional morbidity but no value in our patient.

Finally, further research regarding spontaneous passage and dissolution of large stones is warranted.

Compliance with ethical statements

Conflicts of Interest: *None.*

Financial disclosure: *None.*

Consent: *All photos were taken with parental consent.*

Acknowledgements:

The views expressed in this manuscript are those of the authors and do not reflect the official policy or position of the Department of the Navy, Department of Defense, or the United States Government.

References

- [1] Dwyer ME, Krambeck AE, Bergstralh EJ, Milliner DS, Lieske JC, Rule AD. Temporal trends in incidence of kidney stones among children: a 25-year population based study. *J Urol.* 2012;188(1):247-52.
- [2] Van Savage JG, Palanca LG, Andersen RD, Rao GS, Slaughenhaupt BL. Treatment of distal ureteral stones in children: similarities to the American urological association guidelines in adults. *J Urol.* 2000;164(3 Pt 2):1089-93.

- [3] Elliot JS. Spontaneous dissolution of renal calculi. *J Urol.* 1954;72(3):331-36.
- [4] Kalorin CM, Zabinski A, Okpareke I, White M, Kogan BA. Pediatric urinary stone disease--does age matter? *J Urol.* 2009;181(5):2267-71.
- [5] Dangle P, Ayyash Ot, Shaikh H, 3rd, Stephany HA, Cannon GM, Schneck FX, et al. Predicting Spontaneous Stone Passage in Prepubertal Children: A Single Institution Cohort. *J Endourol.* 2016;30(9):945-49.
- [6] El-Shazly M. Milk of calcium stones: radiological signs and management outcome. *Urolithiasis.* 2015;43(3):221-25.
- [7] Gabrielsen JS, Laciak RJ, Frank EL, McFadden M, Bates CS, Oottamasathien S, et al. Pediatric urinary stone composition in the United States. *J Urol.* 2012;187(6):2182-87.
- [8] Burns JR, Gauthier JF, Finlayson B. Dissolution kinetics of uric acid calculi. *J Urol.* 1984;131(4):708-11.
- [9] Koyuncu H, Yencilek F, Erturhan S, Eryildirim B, Sarica K. Clinical course of pediatric urolithiasis: follow-up data in a long-term basis. *Int Urol Nephrol.* 2011;43(1):7-13.
- [10] Zuckerman JM, Assimos DG. Hypocitraturia: pathophysiology and medical management. *Rev Urol.* 2009;11(3):134-44.
- [11] National Center for Biotechnology Information. PubChem Compound Database; CID=5578 [Apr. 2, 2018]. Available from: <https://pubchem.ncbi.nlm.nih.gov/compound/5578>.

