

Subcutaneous scrotal dirofilariasis in a 3- year- old boy

Biserka Pigac¹, Silvija Mašić², Valentina Mašić³

¹Pathology, Cytology and Forensic Medicine Unit, Varaždin General Hospital, Varaždin, Croatia

²Educational Institute of Emergency Medicine of City of Zagreb, Zagreb, Croatia

³Training and Education Center 'Vinko Bek', Zagreb, Croatia

Abstract

Dirofilariasis is a zoonosis caused by parasites the genus *Dirofilaria*, most common species are *D. repens* and *D. immitis*. This parasitosis rarely affects humans and it is usually asymptomatic. Canines are considered to be the reservoir of the parasite, yet the parasite is transmitted via mosquito bite. We present a case of subcutaneous scrotal dirofilariasis in a 3-year-old boy from north- western part of Croatia, where this zoonosis's not endemic, which characterizes this entity as rarity in this part of the country. In this case, parasitic infestation was manifested as painless scrotal nodule up to 1 cm in its largest diameter. Surgical excision revealed a thread- like material exiting the incision site. According to well –preserved morphologic characteristics, the specimen was characterized as a helminth of the genus *Dirofilaria*. We emphasize the importance of dirofilariasis in patients with subcutaneous nodules. And increase the awareness level of these parasites among clinicians and pathologists.

Keywords

Dirofilariasis; zoonosis; subcutaneous nodule; scrotum.

Copyright © 2016 [pediatricurologycasereports.com](http://www.pediatricurologycasereports.com).

Corresponding Author:

Silvija Mašić, M.D.

Educational Institute of Emergency Medicine of City
of Zagreb, Zagreb, Croatia

E-mail: silvijamasic57@gmail.com

Accepted for publication: 6 May 2016

Introduction

Dirofilariasis is a zoonosis caused by filarial worms of the genus *Dirofilaria* [1,2]. Although around 40 different species of *Dirofilaria* are so far recognized, only few of them affect humans [2]. This parasitosis is widely spread in Europe, Africa and Asia [3]. In Croatia, most of the cases were

noticed in the southern, Mediterranean part [1]. *D. repens* is considered to be the prevalent species of *Dirofilaria* in Europe [1].

The most common presentation of the infection is subcutaneous painful or painless nodule, located in various sites such as face, breast, subconjunctival tissue, epididymis, omentum, scrotum, lacrimal gland, and spermatic cord [1,4-6].

We report a case of a young boy from the north-western part of Croatia with scrotal subcutaneous form of dirofilariasis.

Case Reports

A 3- year-old boy presented with a painless scrotal lump, which had been first noted 2 months prior to medical examination. Despite the lack of pain and other symptoms, boy's parents, who are concerned by the persistence of the lesion, decided to visit a pediatrician. Medical history was inconspicuous, except for epidemiologic findings according to which our patient visited Mediterranean part of Croatia. Physical examination revealed single nodule measuring about 1 cm in longest diameter surrounded by hyperemic area. Laboratory findings demonstrated no abnormalities. Surgical treatment of the lump was the following step. During the excision, a thread-like object was noticed and tissue

specimens was sent to pathology department for the histopathological analysis. Both specimens were trimmed, then underwent routine H&E staining. Histopathological analysis demonstrated area in deep dermis where the parasite was located before removal surrounded by granulation tissue where polymorphonuclear and mononuclear inflammatory cells are intensely infiltrated [Fig.1].

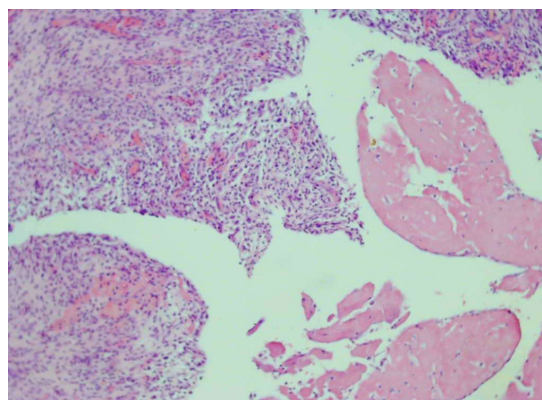


Fig.1. Area in deep dermis where the parasite was located before removal surrounded by granulation tissue where polymorphonuclear and mononuclear inflammatory cells are intensely infiltrated (H&E, 40x).

Other segment showed a well preserved parasite, identified as a *Dirofilaria* species. The most conspicuous morphological features were: a thick cuticle with longitudinal ridges, large lateral chords, slender coelomian muscle layer, a gut tube

and spermatocytes in the genital tubule [Fig. 2].

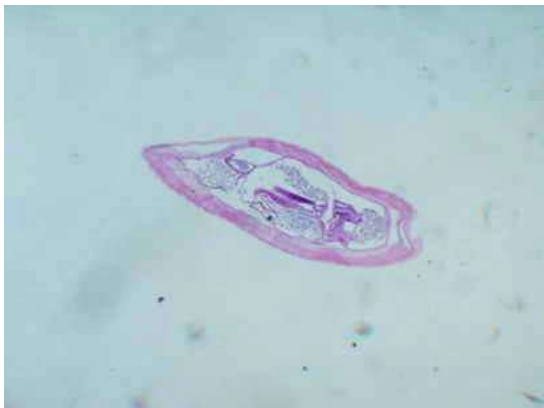

Fig. 2. Morphological features of *Dirofilaria*: a thick cuticle with longitudinal ridges, large lateral chords, slender coelomian muscle layer, a gut tube and spermatocytes in the genital tubule (H&E, 10x).

The boy gone postoperatively, without any detected abnormalities in clinical status or laboratory and radiological parameters. Since surgical treatment is considered to be the only efficient and appropriate therapy of subcutaneous dirofilariasis, no further interventions except clinical monitoring were performed. During patient follow-up, no signs of relapse were observed.

Discussion

Dirofilarias are parasites who live and replicate in canines as their natural hosts and reservoirs. Production of a form called

microfilariae occurs in the host and leads to their circulation in the bloodstream. Through bite of a mosquito, microfilariae are transmitted into mosquito's body and subsequently invade its digestive tract. The helminth is then transmitted to animals or humans via mosquito bite [7]. After settling in human organism, microfilariae undergo death since humans represent their unnatural host [8,9].

Dirofilariasis can be considered as pulmonary and extrapulmonary (visceral, subcutaneous, and ophthalmic) [10]. Symptoms of infection differ according to the site of infestation, yet human infection is usually a disease with mild course or it presents as asymptomatic condition [11]. Most common manifestations include: nodule or abscess formation when localized subcutaneously, conjunctiva redness, excessive lacrimation, swelling in cases of eye involvement [5,8]. Pulmonary dirofilariasis manifests as infarction cause since microfilariae lodge in lung arteries [12]. Symptoms include fever, chest pain, cough, hemoptysis but asymptomatic cases are also documented [12]. Visceral involvement was reported in cases of mesentery, blood vessels, peritoneum, and liver [13]. Subcutaneous lesions are most often caused by *D. repens*, while *D. immitis* relates to pulmonary appearance [10].

Localization of dirofilariasis in scrotum is not common, especially in non- endemic areas, yet it should be considered as differential diagnosis since it can mimic surgical or malignant condition in this body part [14-16], especially in patients with epidemiologic anamnestic data that indicate their travelling to endemic areas like it occurred in case of our patient.

Diagnosis can be obtained through biopsy in case of well-preserved parasite morphology which enable correct identification of the helminth. It is important that physician considers parasite infestation as a possible diagnostic option and for pathologist to be familiar with parasite morphology in order to establish correct diagnosis. In cases of unpreserved morphology, another method is PCR which requires parasite DNA in order to identify it [1,9].

Therapeutic methods of subcutaneous dirofilariasis include extirpation of the worm since in these cases microfilaraemia rarely

occurs and therefore requires no chemotherapeutic measurements [9, 17].

Number of recognized cases due to *D. repens* has nowadays been increasing [18]. It is important for the physicians to consider this parasitosis as possible diagnosis in order to distinguish it from other more serious conditions such as malignant tumors, metastases, other parasitosis, tuberculosis, fungal infections, abscesses which demand surgical and pharmacological treatment [1,11].

We consider validation of this parasitic infection important since it contributes to avoidance of patient's exposure to unnecessary therapeutical procedures.

Acknowledgements

The author(s) declare that they have no competing interests and financial support.

References

1. Marušić Z, Stastny T, Kirac I, Stojčević D, Krušlin B, Tomas D. Subcutaneous dirofilariasis caused by *Dirofilaria repens* diagnosed by histopathologic and polymerase chain reaction analysis. *Acta Dermatovenerol Croat.* 2008;16 (4): 222-225.
2. Janardhanan M, Rakesh S, Savithri V. Oral dirofilariasis. *Indian J Dent Res.* 2014; 25(2):236-239.
3. Das D, Das K, Islam S, Bhattacharjee K, Bhattacharjee H, Das SM et al. A rare case of anterior chamber dirofilariasis. *Oman J Ophthalmol.* 2015; 8(1):50–53.

4. Abdel- Rahman SM, Mahmoud AE, Galal LA, Gustinelli A, Pampiglione S. Three new cases of human infection with *Dirofilaria repens*, one pulmonary and two subcutaneous, in the Egyptian governorate of Assiut. *Ann Trop Med Parasitol*. 2008; 102(6):499-507.
5. Juri J, Kuzman T, Stiglmayer N, Tojagic M. A case of lacrimal gland dirofilariasis. *Ophthalmologica*. 2007; 221(3):204-206.
6. Singh R, Shwetha JV, Samantaray JC, Bando G. Dirofilariasis: a rare case report. *Indian J Med Microbiol*. 2010; 28(1):75-77.
7. Janjetović Z, Arar ZV, Paradzik MT, Sapina L, Bitunjac M, Lojen G et al. Ocular dirofilariasis: a case report. *Acta Med Croatica*. 2010; 64(1):41-45.
8. Khurana S, Singh G, Bhatti HS, Malla N. Human subcutaneous dirofilariasis in India: A report of three cases with brief review of literature. *Indian J Med Microbiol*. 2010; 28(4):394-396.
9. Maltezos ES, Sivridis EL, Giatromanolaki AN, Simopoulos CE. Human subcutaneous dirofilariasis: A report of three cases manifesting as breast or axillary nodules. *Scott Med J*. 2002; 47(4):86-88.
10. Achappa B, Madi D, Mahalingam S. An interesting case of a subcutaneous nodule. *J Clin Diagn Res*. 2013; 7(2):364-365.
11. Radovanović Spurnić AP, Stevanović G, Dakić Z, Ofori Belić I, Spurnić I, Pelemiš M. Human subcutaneous dirofilariasis - case report. *Med Pregl*. 2015; 68(7-8):273-276.
12. Stone M, Dalal I, Stone C, Dalal B. 18-FDG Uptake in Pulmonary Dirofilariasis. *J Radiol Case Rep*. 2015; 9(4):28-33.
13. Kim MK, Kim CH, Yeom BW, Park SH, Choi SY, Choi JS. The first human case of hepatic dirofilariasis. *J Korean Med Sci*. 2002; 17(5):686-690.
14. Soussi A, Farah Klibi F, Zermani R, Rammeh S, Ismail O, Zakraoui A et al. Subcutaneous dirofilariasis due to *Dirofilaria repens* in Tunisia: a case involving the scrotum. *Med Trop (Mars)*. 2004; 64(4):375-378.
15. Bertozzi M, Rinaldi VE, Prestipino M, Giovenali P, Appignani A. Dirofilariasis mimicking an acute scrotum. *Pediatr Emerg Care*. 2015; 31(10):715-716.
16. Fleck R, Kurz W, Quade B, Geginat G, Hof H. Human dirofilariasis due to *Dirofilaria repens* mimicking a scrotal tumor. *Urology*. 2009; 73(1):209.
17. Desai RS, Pai N, Nehete AP, Singh JS. Oral dirofilariasis. *Indian J Med Microbiol*. 2015; 33(4):593-594.

18. Kramer LH, Kartashev VV, Grandi G, Morchon R, Nagornii SA, Karanis P et al. Human subcutaneous dirofilariasis, Russia. Emerg Infect Dis. 2007; 13(1):150-152.

Access this article online

<http://pediatricurologycasereports.com>

Quick Response Code

