

## Symptomatic simple renal cyst managed by laparoscopic unroofing in a child

Mete Kaya<sup>1</sup>, Serpil Sancar<sup>1</sup>, Hakan Erdogan<sup>2</sup>, Omer Yalcin<sup>3</sup>

<sup>1</sup>Yuksekk İhtisas Education and Research Hospital, Department of Pediatric Surgery, Bursa.

<sup>2</sup>Yuksekk İhtisas Education and Research Hospital, Department of Pediatric Nephrology, Bursa.

<sup>3</sup>Yuksekk İhtisas Education and Research Hospital, Department of Pathology, Bursa.

### Abstract

Simple renal cysts (SRC) in children are uncommon, usually asymptomatic, and discovered incidentally during investigation for other urinary or abdominal symptoms. The management of SRC in children depends on the symptoms and imaging. Patients can be followed by ultrasonography or other imaging or may be decided an intervention. The available procedures for the treatment of symptomatic cysts are percutaneous aspiration with or without sclerotherapy and open or laparoscopic approaches of the lesions. Only a few small series have been published SRC in children, and is not sufficient data available regarding laparoscopic approach. In this case report, we present a case of symptomatic SRC who underwent laparoscopic unroofing.

### Keywords

Renal cyst; laparoscopy; unroofing; children.

Copyright © 2016 [pediatricurologycasereports.com](http://www.pediatricurologycasereports.com).

**Corresponding Author:** Mete Kaya, M.D.,  
Yuksekk İhtisas Education and Research Hospital,  
Department of Pediatric Surgery, Bursa.  
E-mail: [kayamete@yahoo.com](mailto:kayamete@yahoo.com)  
Accepted for publication: 15 October 2015

### Introduction

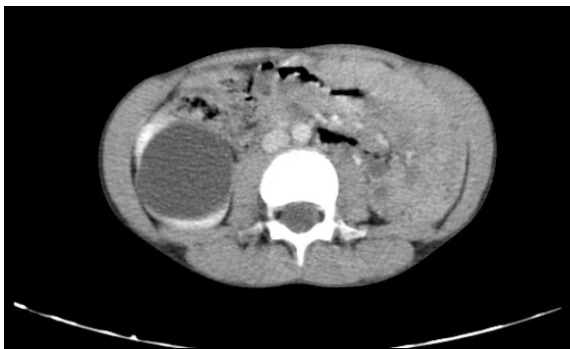Simple renal cysts (SRC) are rare in children [1]. They are usually asymptomatic and are diagnosed incidentally during the investigation of other urinary tract or abdominal symptoms [1,2]. The available procedures for the treatment of symptomatic

SRC are percutaneous aspiration with or without sclerotherapy, endoscopic ablation, and open or laparoscopic procedures [2-4]. We aim to present a case of symptomatic SRC, who underwent laparoscopic unroofing, along with a literature review of this disease in pediatric patients.

### Case report

An 8 year-old-male presented with a 6-month history of recurrent right flank pain during follow-up of SRC by pediatric nephrology department, diagnosed as SRC,

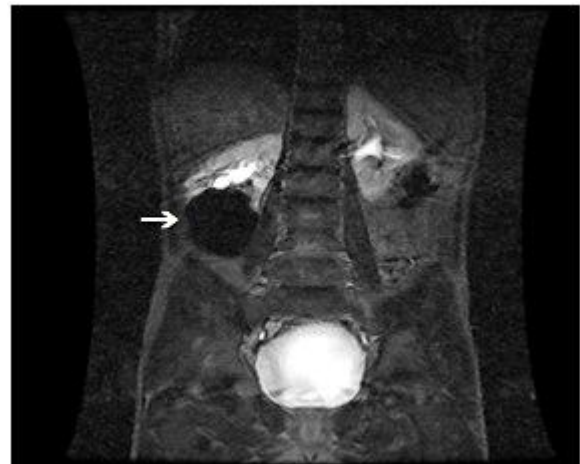
and transferred to our clinic for further treatment. On physical examination, the patient was afebrile with normal vital signs and good growth parameters, and a mild right upper quadrant and right costovertebral angle tenderness was detected. The blood tests and urine analysis were normal. Ultrasound (US) showed a simple cyst measuring 65x52 mm in lower pole of the right kidney. A computerized tomography (CT) scan identified a right SRC measuring 56×43×32 mm in lower pole, which was not communicating with the collecting system [Fig. 1].



**Fig. 1.** CT scan showing right renal cyst without septa and calcification.

On magnetic resonance urography (MRU), a large renal cyst which originated from lower pole of the right kidney [Fig.2]. Technetium-99m mercaptoacetyltriglycine (MAG3) renal scintigraphy with lasix demonstrated normal function of right kidney. Because of cyst has become complicated, we decided to manage the cyst with laparoscopic intervention. We did not consider an aspiration with

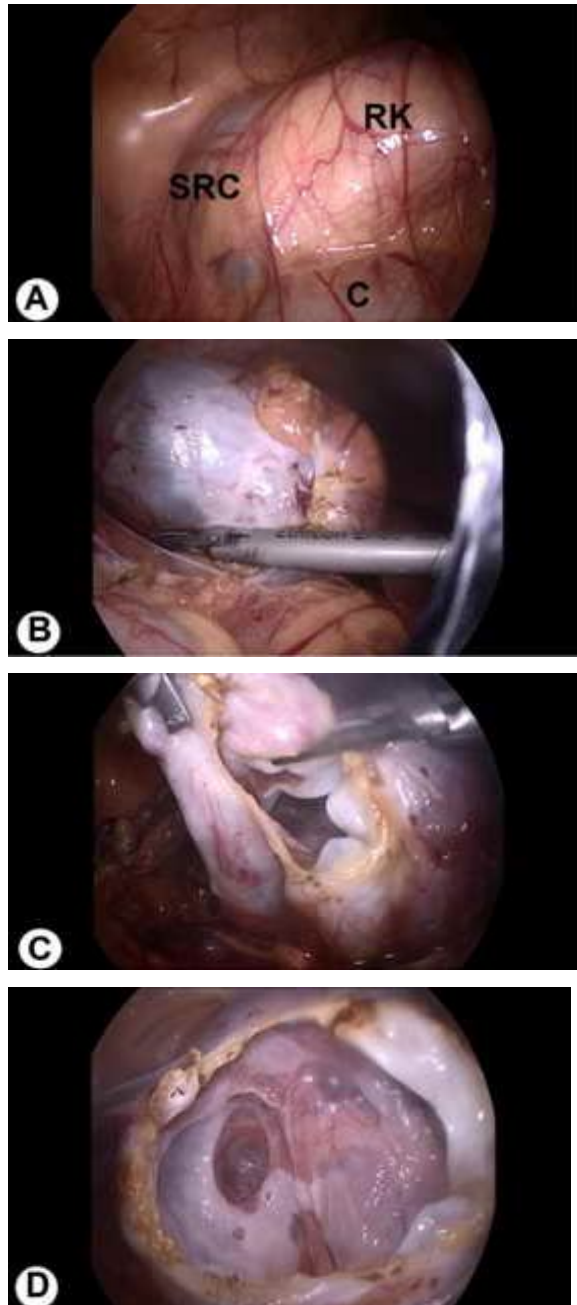
sclerosant due to possible complication and risk of recurrence [3].



**Fig. 2.** MRU showing a renal cyst which is not communicated with the renal collecting system in the lower pole of the right kidney.

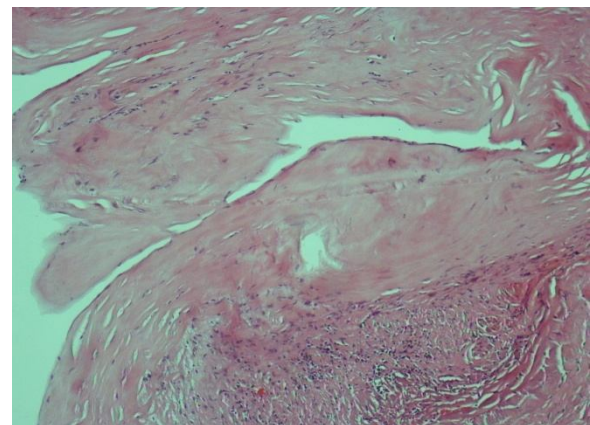
A written informed consent prior to surgery was obtained from the parents. Laparoscopy with 0° telescope and 10 mmHg pneumoperitoneum was performed under general anesthesia on the right decubitus position. Upon examination, the protruded cyst was noted to originate from the right retroperitoneum [Fig. 3A]. The peritoneum was incised over the cyst by using the Harmonic scalpel [Fig. 3B]. A laparoscopic needle was introduced percutaneously into the cyst under direct vision, and aspirated. The cyst did not have a regular capsule. The cyst wall was grasped, and excised using Harmonic scalpel from normal renal tissue border [Fig. 3C]. Following laparoscopic unroofing, the cyst wall was retrieved for histopathologic evaluation. The telescope

was inserted into the cyst cavity for exploration, and there was seen some septas and white plaques which are not recognized in imaging studies [Fig. 3D].



**Fig. 3.** A. Laparoscopic view of the simple renal cyst (SRC) which is originated from right kidney (RK) and protruded from behind of hepatic flexura of colon (C) during operation. B. Appearance of the cyst after incision of the peritoneum. C. Intraoperative image of the laparoscopic unroofing of renal cyst by using Harmonic scalpel. D. Laparoscopic view of inside of the unroofed cyst with septas and white membranes.

Laparoscopy terminated, and no drains were placed. The patient had an eventless postoperative course, was discharged on the following day, and remained asymptomatic during a 6-month follow-up period. Follow-up ultrasound study revealed a fluid collection in the lower pole of right kidney suggesting residual cavity. The histopathological examination showed that simple renal cyst having a fibrous wall and lined by single layer flattened epithelial cells showing no atypia and no mitosis in all specimens [Fig. 4].



**Fig. 4.** Histopathologic slide shows the fibrous cyst wall lined by benign flattened epithelial cells (Hematoxylin and eosin stain,  $\times 100$ ).

### Discussion

SRC are usually unilateral and solitary lesions, the prevalence in adults varied from 5% to 40%, and there is a increase in cyst occurrence with aging [5-7]. SRC are also rarely detected by antenatal US, and most of them resolves spontaneously before delivery. In a study, SRC were diagnosed by US at 14-16 weeks' gestation in 28 fetuses -

a frequency of 1 in 1100 pregnancies (0.09%), in most of whom the cysts resolved by birth, and only two of them persisted as simple benign cysts [8]. It has been reported that the occurrence of new cysts is very rare until the age of 20 years, but thereafter begins to increase in frequency, and male-to-female ratio of approximately 2:1 [1,6,7]. In children, SRC tend to slowly increase in size [1,6]. Additionally, the rate and frequency of increase in size of simple renal cysts and the frequency of complication are higher in large cysts and young patients [1]. Our 8 years old male patient was suffering from right flank pain since 6 months. There were no imaging study in patient before it become symptomatic; therefore, we did not have information about any previous characteristic of the cyst.

The causes of disease may be genetic or acquired, but the Etiology and pathogenesis is unclear. It is suggested that SRC originate from a diverticula of the distal convoluted tubules or collecting ducts [7,9].

Simple cysts are usually asymptomatic and detected incidentally during investigation for other symptoms. Occasionally, they become symptomatic and might present with abdominal discomfort, flank pain, a palpable mass, hypertension, or hematuria as abdominal and/or flank pain, hematuria. These clinical symptoms may be a result of

complications such as bleeding, infection, or rupture of cyst (2–4%); a consequent to an enlarging cyst; compressive collecting system obstruction; or may be due to development of malignancy [1,2]. In our patient, persistent right flank pain for the last six months had developed, and no other complications related to SRC were detected. The diagnosis of SRC is made on the basis of typical imaging findings with surrounding normal renal parenchyma, normal renal function and no associated systemic diseases [3]. In adults, renal cysts are classified according to the Bosniak classification, and divided into five categories based on imaging characteristics on contrast-enhanced CT or MRI [10]. Although this classification can be helpful to predict risk of malignancy in the management of the renal cysts, but it may vary depending on quality of the imaging, interpretation of images, the operator's experience, and the health status of the patients. Recently, Karmazyn et al. [11] have developed an US-based grading system for children. Nevertheless, on the basis of contrast-enhancing CT findings, our patient was diagnosed as a Bosniak category I renal cyst. Although the patients with category I cysts can be followed according to Bosniak classification, we think that surgical approach is indicated in symptomatic cysts as in our patient.

Symptomatic and complex SRC can be treated by various methods such as the percutaneous aspiration with or without sclerosants, percutaneous decortication, antegrade or retrograde endoscopic ablation, and open, transperitoneal or retroperitoneal laparoscopic marsupialization [2-4,12]. Percutaneous aspiration of the renal cyst with or without sclerosant in adults is common practice. Aspiration alone has the disadvantage of a high recurrence rate. Compared with open surgery, percutaneous aspiration with sclerosant is much less invasive; however, we did not prefer percutaneous techniques. Laparoscopic unroofing of a SRC was performed in our patient. Laparoscopic management of renal cyst was first attempted by Hulbert [13]. Different laparoscopic procedures, such as marsupialization, decortication, and unroofing, have been successful in providing long-term results in adult patients with SRC. Although there have been a number of studies on laparoscopic management of SRC in adults in the literature, but it has not been

## References

1. Bayram MT, Alaygut D, Soylu A, et al. Clinical and radiological course of simple renal cysts in children. *Urology*. 2014;83(2):433-7.
2. Yang D, Xue B, Zang Y, Liu X, Zhu J, Chen D, et al. A modified laparoendoscopic single-site renal cyst decortication: single-channel

extensively used in children and hence experience is limited. In our case experience, the cyst was exposed easily, and the border between the cyst and normal kidney was well defined with standard transperitoneal laparoscopic approach, and excised successfully by unroofing method using Harmonic Scalpel. Another advantage of laparoscopic approach to SRC was that the telescope can be inserted inside the cystic cavity, allowing its inspection.

In conclusion, symptomatic SRC is rare condition in childhood. Laparoscopic unroofing of SRC was performed safely and effectively in a child. Along with the widespread use of laparoscopy in children, laparoscopic unroofing will also become the preferred treatment method for SRC because of its exact therapeutic effect, the shorter hospital stay, and other advantages such as limited dissection, good cosmetic appearance, etc.

## Acknowledgements

The author(s) declare that they have no competing interests and financial support.

- retroperitoneal laparoscopic decortication of simple renal cyst. *J Laparoendosc Adv Surg Tech A*. 2013;23(6):506-10.
3. Murthi GV, Azmy AF, Wilkinson AG. Management of simple renal cysts in children. *J R Coll Surg Edinb*. 2001;46(4):205-7.
  4. Tadayon A, A'Yanifard M, Mansoori D. Endoscopic renal cyst ablation. *Urol J*. 2004;1(3):170-3.
  5. Akuzawa N, Osawa T, Totsuka M, Hatori T, Imai K, Kitahara Y, et al. Secondary brain abscess following simple renal cyst infection: a case report. *BMC Neurol*. 2014;14: 130.
  6. Terada N, Arai Y, Kinukawa N, Terai A. The 10-year natural history of simple renal cysts. *Urology*. 2008;71(1):7-11.
  7. Chang CC, Kuo JY, Chan WL, Chen KK, Chang LS. Prevalence and clinical characteristics of simple renal cyst. *J Chin Med Assoc*. 2007;70(11):486-91.
  8. Blazer S, Zimmer EZ, Blumenfeld Z, Zelikovic I, Bronshtein M. Natural history of fetal simple renal cysts detected in early pregnancy. *J Urol*. 1999; 162(3 Pt 1): 812-4.
  9. Baert L, Steg A. Is the diverticulum of the distal and collecting tubules a preliminary stage of the simple cyst in the adult? *J Urol*. 1977;118(5):707-10.
  10. Israel GM, Bosniak MA. Calcification in cystic renal masses: is it important in diagnosis? *Radiology*. 2003;226(1):47-52.
  11. Karmazyn B, Tawadros A, Delaney LR, et al. Ultrasound classification of solitary renal cysts in children. *J Pediatr Urol*. 2015;11(3):149.e1-6.
  12. Lee JY, Lee SW. Laparoendoscopic single-site renal cyst marsupialization using a homemade single-port device has a role as a feasible treatment option. *Urol Int*. 2011;87(3):309-13.
  13. Hulbert JC. Laparoscopic management of renal cystic disease. *Semin Urol*. 1992;10(4):239-41.

**Access this article online**

<http://pediatricurologycasereports.com>

**Quick Response Code**

