


**PEDIATRIC UROLOGY CASE REPORTS**

ISSN 2148-2969

<http://www.pediatricurologycasereports.com>**The first reported contralateral ectopic kidney with ectopic ureteral insertion revealed by septicemia and pyelonephritis caused by Staphylococcus aureus in a 5-year old boy: A case report****Ashley Griswold***Department of Pediatrics, Lehigh Valley Hospital, Allentown, PA, USA***ABSTRACT**

Staphylococcus aureus rarely causes pyelonephritis or cystitis in children. S. aureus-induced urinary tract infection usually develops after an instrumentation or secondary causes such as renal abscess, osteomyelitis or bacterial endocarditis. Additionally, urinary tract colonization by S. aureus may also be the source of staphylococcal bacteremia associated with urinary tract abnormalities and vesico-ureteral reflux. Here, a 5-year-old boy with urinary tract anomaly detected S. aureus in both blood and urine cultures. Diagnosis and treatment process of the patient were presented.

Key Words: Staphylococcus aureus; septicemia; pyelonephritis; urinary tract anomalies: child.

Copyright © 2019 pediatricurologycasereports.com

*Correspondence: Dr. Ashley Griswold,
Department of Pediatrics, Lehigh Valley Hospital,
Allentown, PA, USA*

E mail: Ashley.Griswold@lvhn.org

ORCID ID: <https://orcid.org/0000-0001-8285-3979>

Received 2019-01-03, Accepted 2019-01-15

Publication Date 2019-03-01

Introduction

Urinary tract infection (UTI) is one of the most common bacterial infections encountered in childhood. However, Staphylococcus aureus (S. aureus) rarely causes pyelonephritis or cystitis in children. Therefore, it is uncommonly isolated in 0.13-1% of all urine cultures and in 0.5-6% of positive urine cultures [1-3]. In addition, S. aureus-induced urinary tract infection usually develops after an instrumentation or secondary causes such as renal abscess, osteomyelitis or bacterial endocarditis. Furthermore, urinary tract

colonization by S. aureus may also be the source of staphylococcal bacteremia associated with urinary tract abnormalities and vesico-ureteral reflux [4-7]. In the rare case presented here, after of S. aureus was discovered in both the blood and urine cultures of a 5-year-old male, in the imaging studies of the genitourinary system, the left pelvic kidney, the right vesicoureteral reflux, and the right and left ectopic ureter were detected.

Case report

A 5-year old male presented with 2 days of fever (above 38.5°C), nausea, vomiting, abdominal pain, and altered mental status. Parents report he acutely worsened in the preceding hours: barely waking up, refusing to eat or drink, and barely making any urine output.

He has a history of well-controlled eczema and left kidney anomalies. His prenatal ultrasounds revealed hydronephrosis. His post-natal ultrasound showed a left pelvic kidney with moderate left pelvicalectasis. His post-natal voiding cystourethrogram showed no signs of reflux (Fig. 1). He has no history of urinary tract infections, constipation issues, recent trauma, or sick contacts. He is not taking any medications.

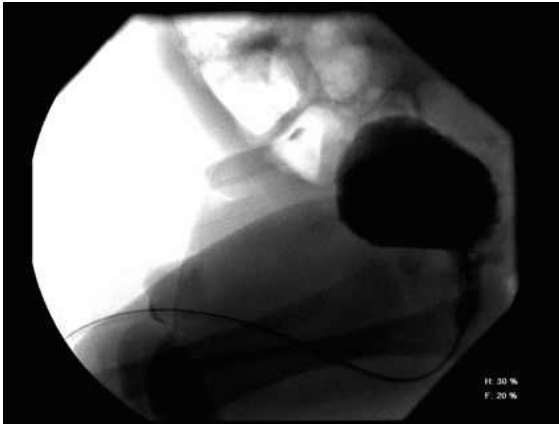


Fig. 1. Post-natal voiding cystourethrogram - interpreted as left pelvic kidney with moderate left pelvicalectasis.

The initial physical exam reveals a temperature of 98.5F, heart rate of 88 beats per minute, respiratory rate of 18 breaths per minute, blood pressure of 100/54 mmHg, and a SpO₂ of 99% on room air. He is in no acute distress but is very sleepy and appears to be in mild discomfort. His abdominal exam reveals a soft, non-distended, non-tender abdomen with no palpable masses and no costovertebral angle tenderness. His genitourinary exam reveals a circumcised male with bilaterally descended testes with no palpable masses. His skin exam reveals small eczematous patches on both knees. The remaining exam is completely unremarkable.

Initial blood work reveals a normal white blood cell count of 8,200 / μ L (5,500-15,500

/ μ L) with neutrophilic predominance (79%), an elevated creatinine of 0.82 mg/dL (0.44-0.65 mg/dL), and an elevated C-reactive protein 216 mg/L (<7.0 mg/L). The remainder of his bloodwork is unremarkable. His urine reveals proteinuria 100-499 mg/dL (negative), hematuria 11-20 RBC/HPF (0-2/hpf), pyuria 6-10 WBC/HPF (0-5/hpf), and positive for nitrites. His CSF is unremarkable. *S. aureus* was isolated from the blood and urine cultures (> 10⁵ CFU/ml from a midstream voided specimen). In order to treat his septicemia, he was treated with intravenous antibiotics until his repeat urine culture and blood cultures showed no growth at 5 days. Then, he received oral antibiotic therapy.

Computed tomography abdominal imaging reveals a left pelvic kidney with severe pelvicalectasis (Fig. 2) and pyelonephritis of the right kidney (Fig. 3).

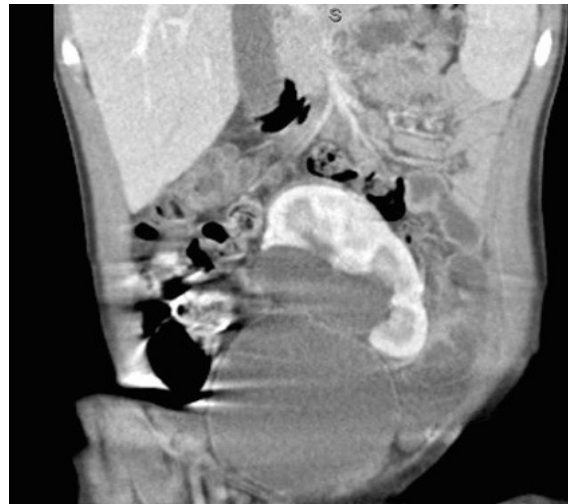

Fig. 2. Computed Tomography of the Abdomen - Interpreted as left pelvic kidney with severe pelvicalectasis.

Subsequent imaging was obtained to explore how *S. aureus* was growing in both his blood and urine cultures. A voiding cystourethrogram revealed a grade 4 vesicoureteral reflux on the right, a distal right

ureter that has an ectopic insertion into the prostatic urethra, a distal left ureter that has an ectopic insertion into the right inferior aspect of the bladder, and mild trabeculation of the urinary bladder contour (Fig. 4).

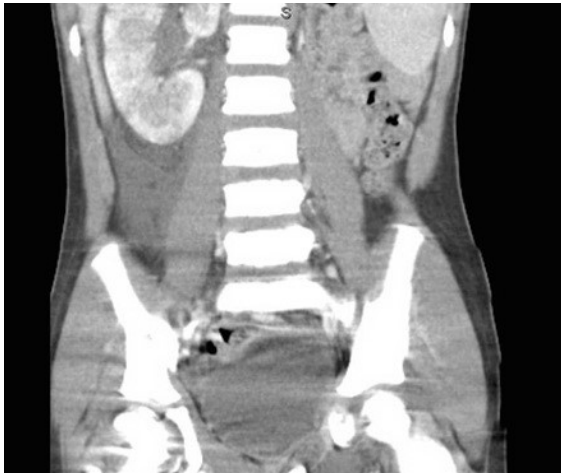

Fig. 3. Computed Tomography of the Abdomen – Interpreted as pyelonephritis of the right kidney.

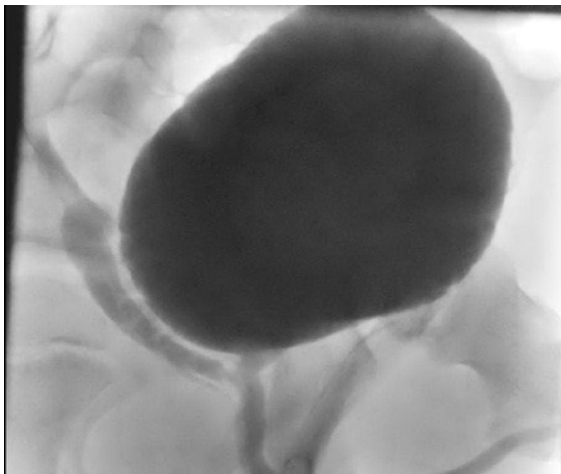


Fig. 4. Voiding cystourethrogram during hospitalization – interpreted as grade 4 vesicoureteral reflux on the right, a distal right ureter that has an ectopic insertion into the prostatic urethra, a distal left ureter that has an ectopic insertion into the right inferior aspect of the bladder, and mild trabeculation of the urinary bladder contour.

Additionally, since there was evidence of hematogenous spread to the kidney, the echocardiogram was performed for our patient, which revealed an incidental finding of a bicuspid aortic valve and no signs of any vegetation.

Discussion

S. aureus is rarely, if ever, considered an uropathogen [8]. If it is present in the urine, it is thought to be caused by hematogenous spread (e.g. bladder catheterization, instrumentation, surgery) in the setting of bacteremia [4]. However, in this case, there was evidence of *S. aureus* in both the blood and the urine. As this organism is not considered an uropathogen, we must consider the blood as the primary source of the bacteria and that it spread hematogenously to the urine. In order to have this spread, we must consider iatrogenic causes such as an indwelling catheter, but we know that no catheter is present on physical exam, nor has there been one in the past based on history. There was no other source of bacteremia such as a skin infection, osteomyelitis, or pneumonia [9]. Therefore, it was felt that the vesico-ureteral reflux was causing stagnant urine that could become infected and then seed the blood.

Further, in a child with a known left pelvic kidney, one must consider the possibility that there are other genitourinary anomalies [10]. Such anomalies could account for a site that would be a target for hematogenous spread. Moreover, in order for this patient to have a clearer explanation of pyelonephritis already seen on computed tomography, one would have to consider urinary reflux because the longstanding reflux of urine would provide both the continued presence of the urinary pathogen as well as the long-term destruction

of normal anatomy that leaves it susceptible to hematogenous seeding [8].

This is the first-ever reported case of contralateral ectopic kidney with ectopic ureteral insertion. In a brief literature review via PubMed, there are small numbers of ipsilateral ectopic kidney and ectopic ureters, but there are no case reports published regarding contralateral ectopy such as was found in this patient. The reported cases in the available literature are either detected from an incidental finding or due to the presence of a febrile urinary tract infection that warranted imaging via voiding cystourethrogram.

This patient's urinary reflux caused by his anomalous genitourinary anatomy explains how *S. aureus* was detected in his urine in the setting of septicemia. Ultimately, he was diagnosed with *S. aureus* septicemia with bacteriuria secondary to a left pelvic ectopic kidney as well as right ectopic ureteral implantation into the prostatic urethra that caused grade IV urinary reflux.

In order to treat his septicemia, he was treated with intravenous antibiotics until his repeat urine culture and blood cultures showed no growth at 5 days. He was then transitioned to oral antibiotics. Because our patient had low risk of invasive disease (no prosthetic material, negative follow-up cultures within 5 days and defervescence within 72 h), oral therapy was switched in the early period.

In the interval days he remained in the hospital, he also underwent a nuclear medicine renal scan with furosemide. This imaging modality helps assess how much each kidney is contributing to overall renal function. The patient's scan showed no evidence of high grade obstruction of the pelvic left kidney, but did reveal a mild right renal parenchymal disease with no evidence of obstruction. And, most importantly, the split renal function was

within normal limits; the kidneys are working equally in their function.

Since there was evidence of hematogenous spread to the kidney, there should also be concerns for seeding on the heart. He had an echocardiogram performed, which revealed an incidental finding of a bicuspid aortic valve and no signs of any vegetation. Therefore, he did not meet criteria for continued antibiotics for vegetation, nor does he meet criteria for sub-acute endocarditis prophylaxis in the future.

Ultimately, he was discharged home on oral antibiotics with close follow up with pediatric urology surgery as well as pediatric infectious disease. Continued oral antibiotics were required because of the persistent genitourinary anomalies that were creating urinary reflux. This patient requires urinary prophylaxis until there is no more evidence of urinary reflux after surgical correction.

Following his discharge from his initial hospitalization, he has undergone two main urologic surgeries. First, he had bilateral ureteral implantation with bilateral ureteral stents. Then, more than a month post-operatively, his retroperitoneal ultrasound showed significant improvement. He subsequently underwent a second surgery involving cystoscopy and ureteral stent removal. Repeat imaging performed more than 1 month post-operatively from this operation revealed a left pelvic kidney with interval improvement. The ultrasound was interpreted as improved, mild distension of the left renal pelvis, a normal right kidney, and mild wall thickening of the partially distended urinary bladder. It was at this time that his oral antibiotics were discontinued.

In conclusion, when there is an atypical uropathogen present in a urine culture, it is imperative to consider anomalous anatomy. In

this case report, *S. aureus* ultimately revealed an extremely unique underlying anatomy with the first reported case of a contralateral ectopic kidney and ectopic ureteral insertion.

Compliance with ethical statements

Conflicts of Interest: None.

Financial disclosure: None.

Consent: All photos were taken with parental consent.

References

- [1] Al Mohajer M, Musher DM, Minard CG, Darouiche RO. Clinical significance of *Staphylococcus aureus* bacteriuria at a tertiary care hospital. *Scand J Infect Dis.* 2013;45(9):688–95.
- [2] Arpi M, Renneberg J. The clinical significance of *Staphylococcus aureus* bacteriuria. *J Urol.* 1984;132(4):697–700.
- [3] Demuth PJ, Gerding DN, Crossley K. *Staphylococcus aureus* bacteriuria. *Arch Intern Med.* 1979;139(1):78–80.
- [4] Muder RR, Brennen C, Rihs JD, Wagener MM, Obman A, Stout JE, et al. Isolation of *Staphylococcus aureus* from the urinary tract: association of isolation with symptomatic urinary tract infection and subsequent *Staphylococcal* bacteremia. *Clin Infect Dis.* 2006;42(1):46–50.
- [5] Karakonstantis S, Kalemaki D. Evaluation and management of *Staphylococcus aureus* bacteriuria: an updated review. *Infection.* 2018;46(3):293-301.
- [6] Schlager TA. Urinary tract infections in children younger than 5 years of age: epidemiology, diagnosis, treatment, outcomes and prevention. *Paediatr Drugs.* 2001;3(3):219-27.
- [7] Lee BK, Crossley K, Gerding DN. The association between *Staphylococcus aureus* bacteremia and bacteriuria. *Am J Med.* 1978;65(2): 303–306.
- [8] Megged, O. *Staphylococcus aureus* urinary tract infections in children are associated with urinary tract abnormalities and vesico-ureteral reflux. *Pediatr Nephrol.* 2014;29(2):269-72.
- [9] Tong SYC, Davis JS, Eichenberger E, Holland TL, Fowler VG. *Staphylococcus aureus* Infections: Epidemiology, Pathophysiology, Clinical Manifestations, and Management. *Clinical Microbiology Reviews.* 2015;28(3): 603-61.
- [10] Berrocal T, Lopez-Pereira P, Arjonilla A, Gutierrez J. Anomalies of the Distal Ureter, Bladder, and Urethra in Children: Embryologic, Radiologic, and Pathologic Features. *Radio Graphics.* 2002;22(5): 1139-164.

Access this article online

<http://pediatricurologycasereports.com>

Quick Response Code

