



## PEDIATRIC UROLOGY CASE REPORTS

ISSN 2148-2969

<http://www.pediatricurologycasereports.com>

## Unilateral renal cystic disease in a 15-year-old female: A left huge kidney associated with significant morbidity

**Hulya Ozturk<sup>1</sup>, Emine Dagistan<sup>2</sup>, Fahri Yilmaz<sup>3</sup>***Abant İzzet Baysal University, Medical School, Pediatric Surgery<sup>1</sup>, Radiodiagnostic<sup>2</sup> and Pathology<sup>3</sup>, Bolu, Turkey***ABSTRACT**

Unilateral renal cystic disease (URCD) is a rare nonfamilial, nonprogressive disorder of one kidney and is not related with autosomal dominant polycystic kidney disease. The present case is a report of a 15-year-old female who had a huge multicystic mass involving the lower and middle part of the left kidney with normal minimal residual renal parenchyma at the upper pole. All the laboratory tests were within normal limits. The right kidney was entirely normal. Left nephrectomy was performed because of a significant morbidity. Here, the clinic, radiologic and pathologic findings are described and their differential diagnosis is discussed.

**Key Words:** Unilateral renal cystic disease; huge kidney; morbidity; children.

*Copyright © 2017 pediatricurologycasereports.com*

**Corresponding Author:** Dr. Hulya Ozturk,  
Abant İzzet Baysal University, Medical School,  
Pediatric Surgery, Bolu, Turkey  
Email: [hulya\\_ztrk@yahoo.com](mailto:hulya_ztrk@yahoo.com)  
Accepted for publication: 11 Jun 2017

**Introduction**

Unilateral renal cystic disease (URCD) is an uncommon condition, non-familial and non-progressive characterized by the replacement of the parenchyma of one kidney by multiple cysts [1,2]. It may involve from part to most or even the whole of the renal parenchyma [3]. The gross and microscopical findings of URCD are indistinguishable from those of autosomal dominant polycystic kidney disease (ADPKD) except for its unilaterality [1-3]. Furthermore, ADPKD is a multisystem disorder that includes abnormalities in other

abdominal organs (liver, pancreas and intestinal tract) as well as in the heart and vasculature [4].

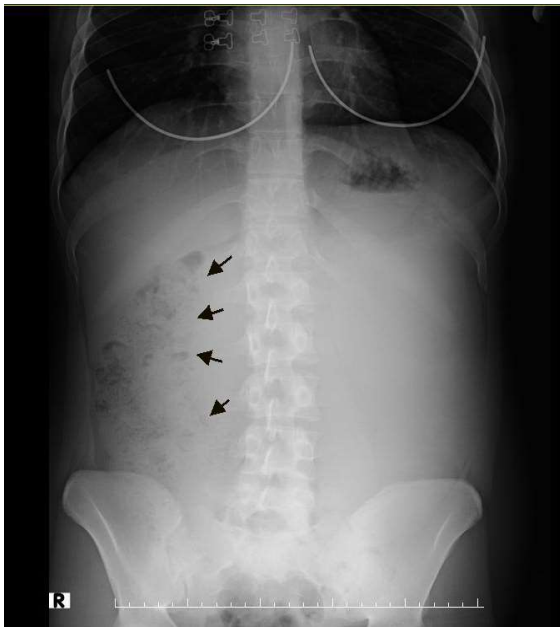Here, we describe a 15 year-old female child with URCD who was presented with a huge left kidney and associated with significant morbidity. Additionally, she had no family history of renal disease or syndromes known to be associated with renal cystic diseases such as liver or pancreas.

**Case report**

A 15-year-old female presented with the complaints of abdominal pain and serious abdominal mass. The physical exam of the abdomen is as follows: A rigid and painful mass that completely filled the upper left and lower abdomen, passes through the midline of

the abdomen. Serum BUN and creatinine was 57 mg/dL and 0.6 mg/dL, respectively. Serum biochemistry including renal and liver functions, electrolytes, calcium, phosphorus, and alkaline phosphatase was normal. Additionally, she had a history of right ovarian cyst surgery.

Abdominal radiograph demonstrated displacement of bowel gas due to mass effect in the right abdomen [Fig. 1].



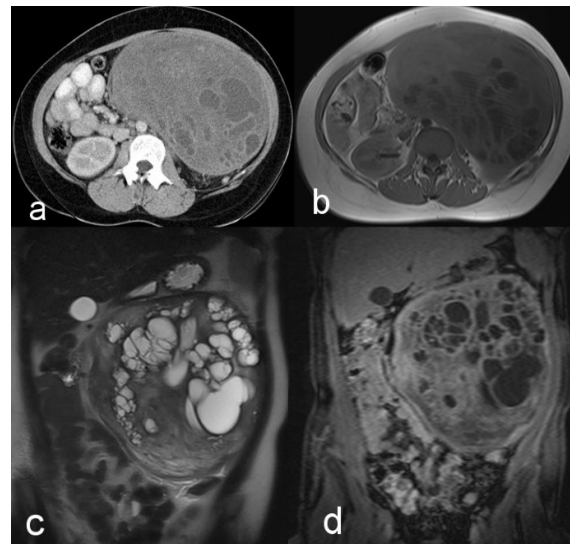
**Fig. 1.** Plain abdominal x-ray.

Abdominal ultrasonography showed a giant solid mass with cystic areas completely filled the left abdominal quadrant, extending into the midline, to the left lumbar area, and the left pelvic region.

On the abdominal tomography, there was a well-defined solid lesion with uniform contour and capsular appearance, with an average of 30 HU densities, with cystic areas reaching the largest 5 cm diameter, measuring the size of approximately 130x200x215 mm at its widest point and extending from the middle to lower end of the left kidney. On magnetic resonance imaging, cystic lesions were hypointense in

T1A, contrast enhancement in hyperintense postcontrast sections in T2A, but not axial T1A, coronal T2A, and coronal contrast T1A images. Heterogeneous contrast enhancement was observed in the solid parts of the lesion [Fig. 2a-d].

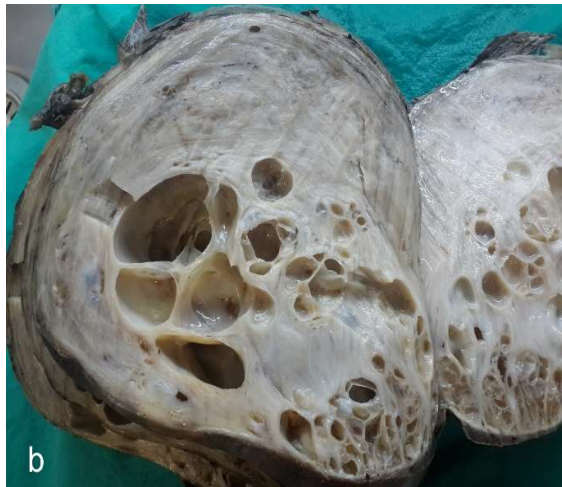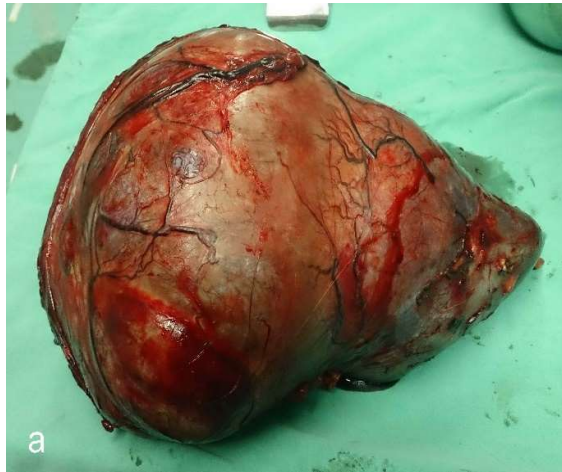There was no family history forthcoming and evaluation revealed ADPKD in his father, and he had normal renal function.



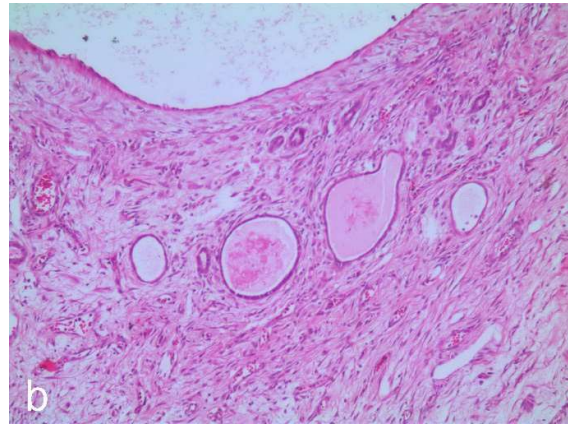
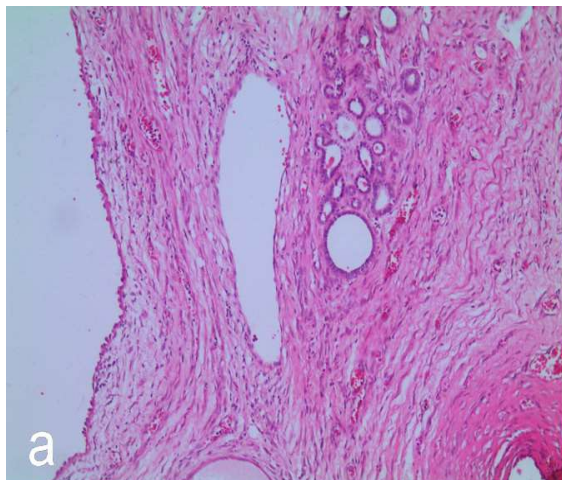
**Fig. 2.** Oral + IV contrast-enhanced CT with axial contrast (a), the right kidney is normal, the giant mass with a very limited number of cystic structures of different sizes in the left kidney (or left kidney lozenge), passing through the midline. The cyst wall is seen in an annular enhancement. Cystic lesions are hypointense in T1A, contrast enhancement in hyperintense postcontrast sections in T2A, but not axial T1A (b), coronal T2A (c), and coronal contrast T1A (d) images. Heterogeneous contrast enhancement was observed in the solid parts of the lesion.

The patient was hospitalized and the huge mass that contains the middle and lower pole of the kidney was completely removed [Fig. 3a, b]. Histopathological evaluation of the mass was defined as URCD [Fig. 4a, b].

She was discharged on 7th postoperative day without any complications.



**Fig. 3.** (a) Postoperative and (b) cross-sectional view of the mass.



**Fig. 4.** (a) Cystic structure with atrophic tubules and single rowed flattened cubic epithelium with fibrocollagenous wall. (b) Fibrocollagenic small cyst structures filled with flattened cubic epithelium lined fluid in the stroma.

### Discussion

URCD poses a diagnostic dilemma because it is rare and poorly understood. It is first described in 1979 by Cho et al. as segmental cystic disease of the kidney [3,5]. Multiple unilateral renal cysts, segmental polycystic kidney disease, and unilateral polycystic renal disease are synonyms for URCD [3]. URCD is an uncommon, non-familial, non-progressive, and distinct entity that is one of the renal cystic diseases, not exhibit extra-renal signs or symptoms [1,3]. Although most of the patients were diagnosed in adulthood, URCD was also reported in newborn infants and in childhood. The patients usually presented with flank or abdominal pain, a palpable abdominal mass, gross or microscopic hematuria or hypertension.

ADPKD, multicystic dysplastic kidney, multilocular cystic renal neoplasm, and simple cysts should be considered in differential diagnosis of URCD [1,3,6]. The cysts are not different from those in ADPKD, histopathologically. However, URCD involves from part to most or even the whole kidney and

numerous, variously sized cysts are scattered throughout the kidney, separated by normal or compressed renal parenchyma [3]. Additionally, unlike ADPKD, URCD has a unilateral involvement, negative family history, no progression to end-stage renal disease (ESRD), lack of genetic background and absence of cysts in other organs such as liver or pancreas [7,8], as in the case presented here.

In the present case, a huge mass filling the mid-abdominal cavity and pressing the intestinal organs was removed by operation because of the significant morbidity.

### Acknowledgements

The author(s) declare that they have no competing interest and financial support.

### References

- [1] Lee S, Park SK, Kang SK, Kim W. A case of unilateral renal cystic disease. *Nephrology (Carlton)*. 2004;9(1):31-2.
- [2] Lin SP, Chang JM, Chen HC, Lai YH. Unilateral renal cystic disease--report of one case and review of literature. *Clin Nephrol*. 2002;57(4):320-4.
- [3] Bisceglia M, Galliani CA, Senger C, Stallone C, Sessa A. Renal cystic diseases: a review. *Adv Anat Pathol*. 2006 ;13(1):26-56.
- [4] Akoh JA. Current management of autosomal dominant polycystic kidney disease. *World J Nephrol*. 2015;4(4):468-79.
- [5] Cho KJ, Thornbury JR, Bernstein J, Heidelberger KP, Walter JF. Localized cystic disease of the kidney: angiographic-pathologic correlation. *AJR Am J Roentgenol*. 1979;132(6):891-5.
- [6] Hwang DY, Ahn CR, Lee JG et al. Unilateral renal cystic disease in adults. *Nephrol Dial Transplant*. 1999; 14(8): 1999–2003.
- [7] Glassberg KI. Unilateral renal cystic disease. *Urology*. 1999; 53(6): 1227–8.
- [8] Middlebrook PF, Nizalik E, Schillinger JF. Unilateral renal cystic disease; a case presentation. *J. Urol*.1992; 148(4): 1221–3.

Access this article online

<http://pediatricurologycasereports.com>

Quick Response Code

