

Unilateral undescended testicle with ipsilateral fixed-matted inguinal mass: A case report

Jan Michael A Silangcruz¹, Michael E Chua¹, Michael John Francis V Gaston^{1,2}

¹*Institute of Urology, St. Luke's Medical Center, Philippines.*

²*Department of Surgery, Section of Urology, The Medical City, Philippines.*

Abstract

We described a rare occurrence of unilateral undescended testis with an ipsilateral fixed matted inguinal mass in a 15 month old male with normal tumor markers. Doppler ultrasound showed calcified masses with no obvious color blood flow. We discussed considerations in the management of the case and reiterated the importance of basic thorough medical history taking and physical examination as a vital step to prevent unnecessary surgical procedures as well as arriving at a correct diagnosis.

Keywords

Undescended testis; cryptorchidism; BCG adenitis; inguinal mass; child.

Copyright © 2016 pediatricurologycasereports.com.

Corresponding Author

Jan Michael A. Silangcruz, MD

*Institute of Urology- St. Luke's Medical Center,
Philippines*

Email: jmsilangcruz@gmail.com

Accepted for publication: 27 November 2015

Introduction

Undescended testis is one of the most common male pediatric disorders identified at birth [1]. On the other hand, managing an inguinal mass should have several considerations to make, both benign and malignant lesions may come into the picture

with significantly different management. Algorithms and differential diagnosis for pediatric inguinal mass include inguinal hernia, lymphadenopathies and various benign and malignant conditions [2]. To our knowledge, we report the first case of matted calcified mass in an ipsilateral undescended testis with normal tumor markers. We described the findings and management of our case and discussed considerations.

Case Report

A 15 month old male, born term to a 35-year-old gravid 4 para 4 mother. He was

diagnosed at birth to have non palpable undescended right testis with normal external genitalia and descended left testis. At 5 months of age, he began to develop right inguinal mass. Consult was done in a local clinic and given oral antibiotics and was lost to follow up. Gradual increase in size and number of the inguinal masses were noted. At 15 months of age, persistence of the right inguinal masses and undescended testis with no other associated symptoms prompted consult at our institution. Review of systems was unremarkable. Pertinent physical examination revealed right inguinal hernia with no peritoneal content. The right testicle was not appreciated in the right scrotum with no fluid noted. Left testicle was palpable at the left scrotum. Matted right inguinal masses, firm and immobile in character measures approximately 3-4cm in aggregate, non-tender [Fig. 1].

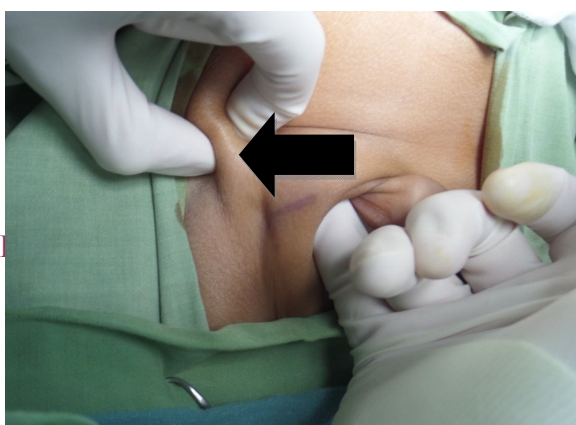


Fig. 1. Right inguinal mass on the arrow with inguinal hernia as noted in physical examination

No notable firm mass on the femoral, perineal or inguinal area that is suggestive of ectopic testis. Ultrasound doppler was done and was not able to locate the right testicle; however, calcified mass, suggestive of lymph nodes, were noted in the right inguinal area with no obvious color blood flow [Fig. 2].

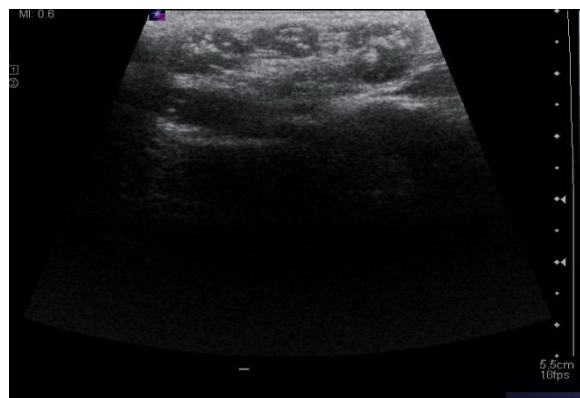


Fig. 2. Ultrasound Doppler of right inguinal mass showing Multiple nodular densities with calcifications in the right inguinal region most likely represent calcified inguinal nodes largest 1.2 x 0.7 x 1.0 cm.

Total serum human chorionic gonadotropin (hCG) and alpha-fetoprotein (AFP) were found to be <0.10 mIU/mL and 2.04 ng/mL, respectively. Chest x-ray was unremarkable.

A thorough history taking and physical examination was done in our institution and noted that the patient had a BCG vaccine at right gluteus maximus at birth which left an induration scar [Fig. 3].

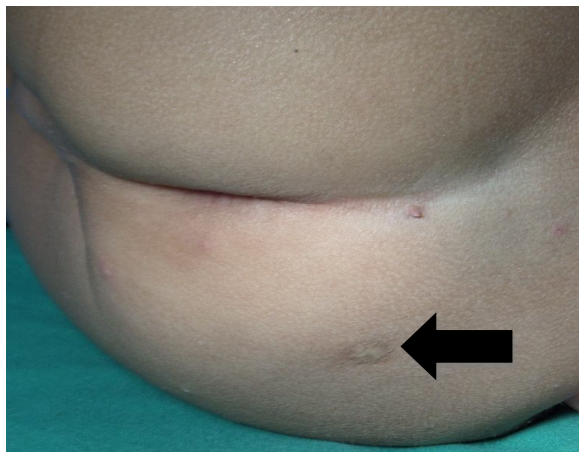


Fig. 3. BCG Vaccine scar right gluteus maximus

At this point, the impression was BCG adenitis at right inguinal area with concomitant ipsilateral abdominal undescended testis versus a nubbin. Inguinal exploration was done on the right and noted an infracanalicular testis [Fig. 4], orchidopexy done with herniotomy; inguinal lymph nodes were dissected [Fig. 5] and sent for histopathology, which consequently confirmed the diagnosis of BCG adenitis [Fig. 6,7].

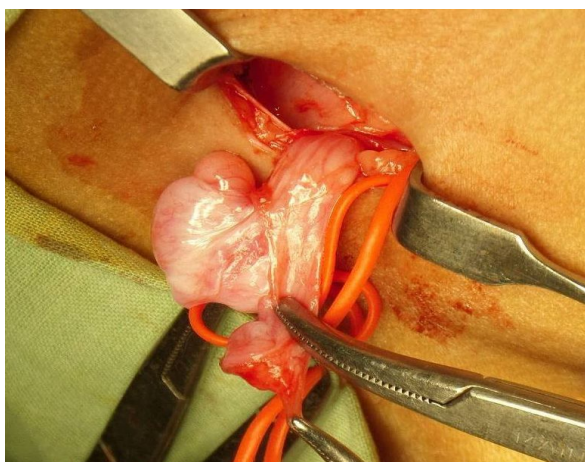


Fig. 4. Infracanalicular right testis.

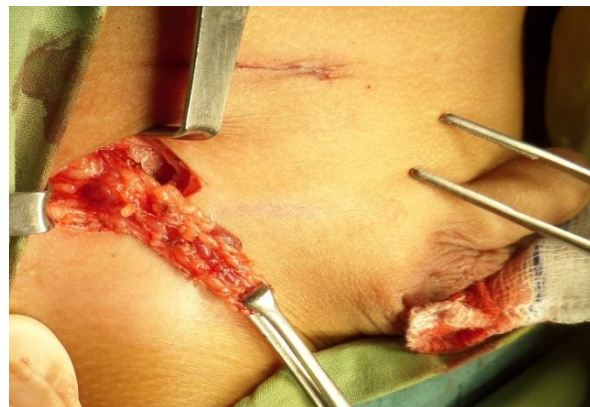

Fig. 5. Right inguinal mass, gross image.

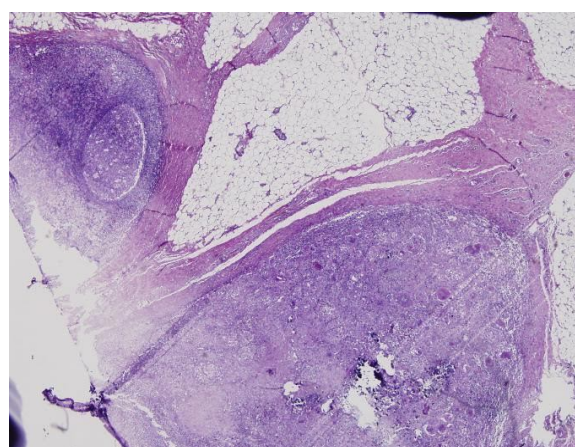


Fig. 6. Right inguinal mass on low power field. Chronic granulomatous lymphadenitis with caseous necrosis.

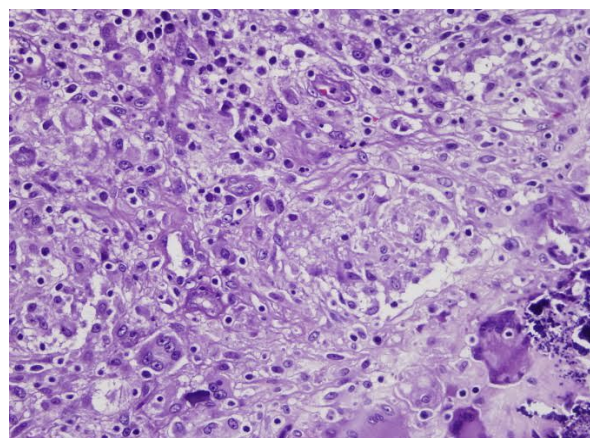


Fig. 7. Right inguinal mass on high power field.

Discussion

Approximately 70% of undescended testes are palpable [1]. For testes that are not palpable, approximately 30% will be found in the inguinal-scrotal area, 55% will be intra-abdominal, and 15% will be absent or vanishing [1]. Spontaneous descent of undescended testes may occur in the first six months of life [1]. However in patients with persistence of undescended testis after six months, location varies such as in the abdomen, the inguinal canal, the superficial inguinal pouch, the upper scrotum, or, may rarely be in an ectopic location (perineum, contralateral scrotum, or femoral) [1].

For an undescended testis, the ultrasound is non-contributory and is not recommended for routine use; however in the diagnostic approach for inguinal mass in children such as in our case, ultrasound with Doppler is the optimum diagnostic study [2]. Ultrasound can readily differentiate the features of hernias, hydroceles and undescended or ectopic testis, atypical masses of testis and reproductive organs [2]. In our patient, he began to develop right inguinal mass at 5 months of age, and gradual increase in size was noted after even oral antibiotics. Specific differential diagnosis for consideration in an inguinal mass are listed in Table 1 [2].

Table 1. Differential diagnosis of inguinal swelling in children.

Inguinal hernia
Inguinal lymphadenopathies/ granuloma inguinale
Femoral hernia
Appendicitis within the hernia sac/ Amyand hernia
Benign/ malignant tumor*
Hydrocoele of the spermatic cord
Retractile testicles
Undescended or ectopic testicle
Traumatically dislocated testicle

**Benign lesions of the inguinal canal can include, but are not limited to: lipomas, hematomas, mesothelial cyst, dermoid cysts. Soft tissue sarcomas comprise the most common malignant tumors of the groin. However, testicular tumors may be considered.*

The dilemma of our case was settled by thorough history taking and physical examination done in our institution, where a post BCG vaccine scar was noted on the ipsilateral gluteus maximus area and ultrasound findings suggestive of calcified lymph node with normal serum tumor markers. All of which were supportive of ruling out the presence of testicular malignancy.

Development of pathological reactions at the

site of inoculation and in the regional nodes after BCG injection is expected [3]. The finding of isolated enlarged axillary (rarely supraclavicular or cervical) lymph nodes ipsilateral to the site of BCG vaccination, with no other identifiable cause for adenitis, is usually sufficient for making the diagnosis [3]. In our case, since the injection site is gluteus maximus, then ipsilateral inguinal lymph node was the site of lymphatic drainage.

The original BCG vaccine is a live-attenuated form of *Mycobacterium bovis*. A series of 638 BCG-related lymphadenitis in infants was reported due to the change in the vaccine strain from Tokyo-172 to Pasteur-1173. The incidence of lymphadenitis was then declined after the Tokyo strain was reintroduced and awareness of this condition was commenced [4]. Bacille Calmette-Guérin (BCG) lymphadenitis is the most common complication of BCG vaccination [3]. There are two forms of this condition. Simple or non-suppurative lymphadenitis, which usually regresses spontaneously over a period of few weeks, and suppurative form, distinguished by the formation of swelling, with erythema and edema of overlying skin which frequently forms spontaneous perforation and sinus formation, followed by closure of the sinus

by cicatrization [3]. Non-suppurative BCG lymphadenitis is best managed with expectant follow ups only, because medical treatment with erythromycin or anti-tuberculous drugs do not hasten the regression or prevent development of suppuration [3,4]. Surgical excision is rarely needed and is meant for cases of failed needle aspiration or for draining BCG nodes. In our case, the surgical excision of the inguinal mass was done to only confirm diagnosis of BCG adenitis and rule out possible malignancy. A separate incision was made over the inguinal mass in order to avoid extension of BCG infection to the inguinal incision made for the orchidopexy. This is a rare occurrence of both undescended testis with an ipsilateral calcified inguinal lymph nodes which turned out to be a BCG adenitis. The importance of this report is to carefully take time to do history and physical examination in order not to miss a diagnosis of importance. Neglect of an important detail in the physical exam and history may lead to erroneous treatment.

Acknowledgements

The author(s) declare that they have no competing interests and financial support.

References

1. Kolon, TF., et al. "Evaluation and treatment of cryptorchidism: AUA guideline." *J Urol*. 2014;192(2): 337-5.
2. Mathison, DJ. Evaluation of Inguinal Swelling in Children. In: UpToDate, (accessed on July 10, 2015)
3. Goraya, J. S., and V. S. Viridi. "Bacille Calmette-Guérin lymphadenitis." *Postgraduate Medical Journal*. 2002; 78(920):327-9.
4. Govindarajan, KK and Feng, YC. "BCG adenitis—need for increased awareness." *The Malaysian journal of medical sciences: MJMS*. 2011;18(2): 66.

Access this article online

<http://pediatricurologycasereports.com>

Quick Response Code

