



Ureteral orifice opening into the bladder diverticulum in a boy:

A case report

Metin Tahaoglu

Abstract Bladder diverticulum is a rare malformation characterized by an outpouching with a diameter greater than 2 cm of the mucosa due to a defect in the detrusor musculature. In the case of this study, in a 2,5 year old boy, the bladder diverticulum and the left ureteral orifice opened into diverticulum the was detected. This case was discussed with the experience of literature.

Key Words Bladder diverticulum; diverticulectomy; vesicoureteral reflux; ureterovesical reimplantation

© 2014 pediatricurologycasereports.com. All Rights Reserved

Corresponding Author: Metin Tahaoglu, M.D. Abant Izzet Baysal University Training and Research Hospital, Department of Pediatric Surgery, Bolu, Turkey
E mail: metin1161@yahoo.com
Accepted for publication 12 August 2014

INTRODUCTION

Bladder diverticulum developing congenital or acquired occurs in approximately 1.7% of the pediatric population [1]. Bladder diverticulum is thought to be a result of a smooth muscle defect and it is frequently associated with the ureter [2]. They are found by findings such as acute urine

retention, recurrent urinary tract infections, or a pelvic mass [3]. Bladder diverticulum are situated most commonly cephalad and lateral to the ureteral opening [4]. One of the first to recognize this distinction was Hutch and the title of one of his papers "Saccule Formation at the Ureterovesical Junction in Smooth Walled Bladders" [5] bears witness to his surprise at this discovery. Diverticula at or near the ureterovesical junction in patients who are otherwise normal, bear his

name. The treatment of bladder diverticula is surgical based on diverticulectomy by intra or extravascular way with ureterovesical reimplantation if a vesicoureteral reflux (VUR) is present [3].

In the case of this study, in a 2,5 year old boy, the bladder diverticulum and the left ureteral orifice opened into diverticulum the was detected. This case was discussed with the experience of literature.

CASE REPORT

A 2,5-year-old boy presented with urinary tract infection and abdominal pain. Excretory urogram and voiding cystourethrogram (VCUG) showed VUR and a diverticulum of the bladder on the left side. X-ray examinations were based on the abdominal ultrasound which showed a cystic formation adjacent and retro the bladder associated with thickening of the bladder wall. Renal function was normal in patient and the urinalysis was positive. Patient was operated by classical surgery preceded by a primary endoscopic exploration in case which showed no urethral obstruction. The left ureteral orifice was opened into the

diverticulum. Ureter and diverticulum relationship is observed bladder behind (Fig 1). Diverticulectomy and left ureteroneocystostomy (by Ledbetter technique) were performed. Post-surgical recovery was very good.

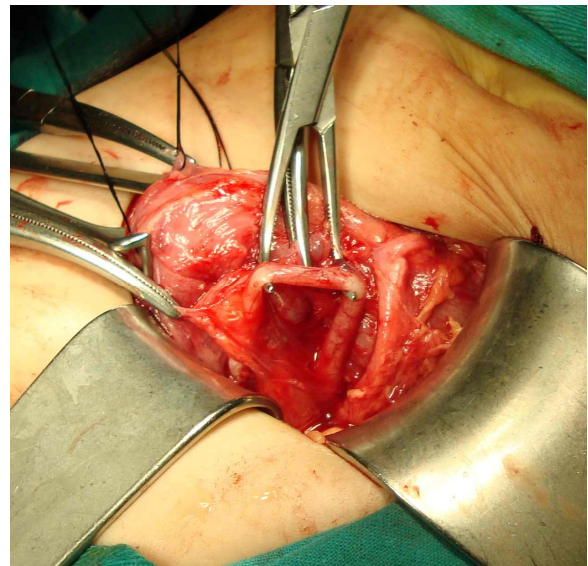


Fig. 1. Ureter and diverticulum relationship is observed bladder behind.

DISCUSSION

Bladder diverticulum is a rare malformation characterized by an outpouching with a diameter greater than 2 cm of the mucosa due to a defect in the detrusor musculature [6]. Bladder diverticula are congenital, acquired or iatrogenic and they occur at any age [7-9]. In a series of symptomatic patients evaluated by cystography in

children, congenital bladder diverticulum was reported as an incidence of 1.7%. Most of bladder diverticula are single, unilateral, and paraureteral/posterolateral in location, some of them have the ureteric orifice incorporated in it [10,11]. Congenital bladder diverticula are commonly a consequence of an inherent weakness such as Ehlers-Danlos syndrome and connective tissue disorder and sometimes may cause bladder outlet obstruction and acute urinary retention [12,13]. Increased pressure in the bladder causes vesical mucosa to insinuate itself between hypertrophied muscle bundles; thereafter a mucosal extravasational sac develops [14]. Urine in a diverticula may not be evacuated completely after micturition and cause complications such as infection and stone [11].

A diverticulum relationship with the ureterovesicular junction is generally called as periureteric diverticulum, conventionally known as Hutch diverticulum [15], and there is often VUR in patients. A diverticulum associated with ureter alters the normal

anatomical insertion of the ureter into the bladder. Most bladder diverticula may be incidentally diagnosed during the evaluation of patients for recurrent urinary tract infection, incontinence, or urine retention [16]. VCUG is an important diagnostic tool in the diagnosis of diverticulitis. The sonographic findings of diverticulum known as round or oval anechoic fluid collections that arise from the base of the bladder or around the ureteric orifice. Bladder diverticulum may be spontaneously to rupture [17]. When incidentally discovered congenital bladder diverticulum, no treatment is needed unless the diverticulum cause complications such as VUR, infection or obstruction. Otherwise, bladder diverticula should be excised. Prophylactic excision of the diverticulum can be performed because of the risk of developing carcinoma in bladder [16,18].

As mentioned above, malformation in a high percentage of cases with bladder diverticula are located at or near the ureterovesical junction [19]. The orifices of the

diverticulum and the ureter may be at distinct points, in this situation; the ureteral opening will retain its integrity. When the ureter is opens into or on the diverticulum rim, incompetent ureteral opening and vesicoureteral reflux will be present [20]. As a result of the growth of diverticula, ureteral orifice may be incorporated into the diverticulum [21].

In the case presented here, the ureteral orifice was opening into the diverticulum.

This rare malformation was detected in the operation and transvesical diverticulectomy was performed. In children with urinary tract infection and urinary retention would be useful to investigate the case of bladder diverticula.

CONFLICT OF INTEREST

None declared.

REFERENCES

1. Gearhart JP. Exstrophy, epispadias, and other bladder anomalies. In: Walsh PC, Retik AB, Vaughan Jr ED, et al, (eds). Campbell's urology. 8th ed. Philadelphia 7 Saunders Co; 2002. pp. 2189- 90.
2. Caldamone AA. Anomalies of the bladder and cloaca. In: Gillenwater JT, Grayhack JT, Howards SS, et al, (eds). Adult and pediatric urology. 2nd ed. St Louis (Mo)7 Mosby-Year Book, Inc; 1991. pp. 2024- 5.
3. Khemakhem R, Ghorbel S, Jlidi S, et al. Management of congenital bladder diverticulum in children: A report of seven cases. Afr J Paediatr Surg. 2013;10:160-3.
4. Mitra SK, Chakraborty JN. Congenital bladder diverticulum presenting as bladder outflow obstruction and obstructive uropathy-report of 6 cases and review of literature. J Indian Assoc Pediatr Surg 2002;7:25-28

5. Hutch JA. Saccule formation at the ureterovesical junction in smooth walled bladders. *J Urol.* 1961;86:390-9.
6. Kelalis PP. Obstructive uropathy: Bladder. In: Kelalis PP, King LR, (eds). 1st ed. *Clinical pediatric urology, Vol. 1.* Philadelphia: Saunders; 1976. pp. 282-91.
7. Pace AM, Powell C. Congenital vesical diverticulum in a 38-year-old Female. *Int Urol Nephrol.* 2005;37:473-5.
8. Appeadu-Mensah W, Hesse A, Yaw MB. Giant bladder diverticulum: A rare cause of bladder outlet obstruction in children. *Afr J Paediatr Surg.* 2012;9:83-7.
9. Bogdanos J, Paleodimos I, Korakianitis G, Stephanidis A, Androulakakis PA. The large bladder diverticulum in children. *J Pediatr Urol.* 2005;1:267-72.
10. Rawat J, Abdul K. Rashid, Kanojia RP, Kureel SN, Tandon RK. Diagnosis and management of congenital bladder diverticulum in infancy and childhood: Experience with nine cases at a tertiary health center in a developing country. *Int Urol Nephrol.* 2009;41:237-42.
11. Shakeri S, Rasekhi AR, Yazdani M, Kheradpezhohu E. The incidence of diverticula of urinary bladder in patients with benign prostatic hypertrophy and the comparison between cystoscopy and cystography in detecting bladder diverticula *IRCMJ* 2007;9:36-41.
12. Shukla AR, Bellah RA, Canning DA, et al. Giant bladder diverticula causing bladder outlet obstruction in children. *J Urol.* 2004;172:1977-9.
13. Oge O, Gemalmaz H, Ozeren B. Acute urinary retention in a child caused by a congenital bladder diverticulum. *J Endourol.* 2004;18:69-72.
14. Gerridzen RG, Futter NG. Ten-year review of vesical diverticula. *Urology.* 1982;20:33-5.
15. Pieretti RV, Pieretti-Vanmarcke RV. Congenital bladder diverticula in children. *J Pediatr Surg.* 1999;34:468-73.

16. Zia-Ul-Miraj M. Congenital bladder diverticulum: a rare cause of bladder outlet obstruction in children. *J Urol.* 1999;162:2112–13.
17. Bachiller Burgos J, Varo Solís C, Báez JM, et al. Congenital bladder diverticulum and Ehlers-Danlos syndrome: an unusual association. *Actas Urol Esp.* 2000;24:673-6.
18. Berrocal T, López-Pereira P, Arjonilla A, Gutiérrez J. Anomalies of the distal ureter, bladder, and urethra in children: embryologic, radiologic, and pathologic features. *Radiographics.* 2002;22:1139-64.
19. MacKeller A, Stephens FD. Vesical diverticula in children. *Austr N Z J Surg.* 1960;30: 20-31.
20. Barrett DM, Malek RS, Kelalis PP. Observations on vesical diverticulum in childhood. *J Urol.* 1976;116:234-6.
21. Boechat MI, Lebowitz RL. Diverticula of the bladder in children. *Pediatr Radiol.* 1978;7:22-8.