



PEDIATRIC UROLOGY CASE REPORTS

ISSN: 2148–2969

Journal homepage: <http://www.pediatricurologycasereports.com>

## Urinary ascites from spontaneous bladder perforation in female neonate

Ankur Arya, Vikash Kumar, Prakash Pawar, Ashwin Tamhankar

Department of Urology, LTMMC & LTMGH, Sion, Mumbai, India

### Abstract

Urinary ascites from bladder perforation in neonate is a rare event reported to occur more commonly following umbilical artery catheterization. Other causes include bladder perforations in neonates with bladder abnormalities, following bladder instrumentation or idiopathic bladder perforations. The present manuscript describes a full-term female neonate with spontaneous bladder perforation who was successfully managed with early operative intervention. We also present a review of the current literature and also discuss the pathogenesis, diagnosis and management of this rare entity.

### Keywords

Urinary ascites; bladder; spontaneous perforation; neonate.

Copyright © 2015 [pediatricurologycasereports.com](http://www.pediatricurologycasereports.com).

**Corresponding Author:** Ankur Arya, M.D.

Department of Urology, Room 219, College building,  
LTMMC & LTMGH, Sion Hospital, Sion, Mumbai,  
India

E mail: [drankurarya8@gmail.com](mailto:drankurarya8@gmail.com)

Accepted for publication: 26 October 2015

## INTRODUCTION

Ascites in neonatal period is a rare event and in about one fourth of cases urinary system

is implicated as a cause [1]. Still uncommon is the bladder perforation as a cause for urinary ascites. Neonatal bladder perforations, though rare, appears to be increasingly reported in latter half of last century due to larger number of premature infants being admitted to the neonatal intensive care unit that require umbilical artery catheterization or cut down and

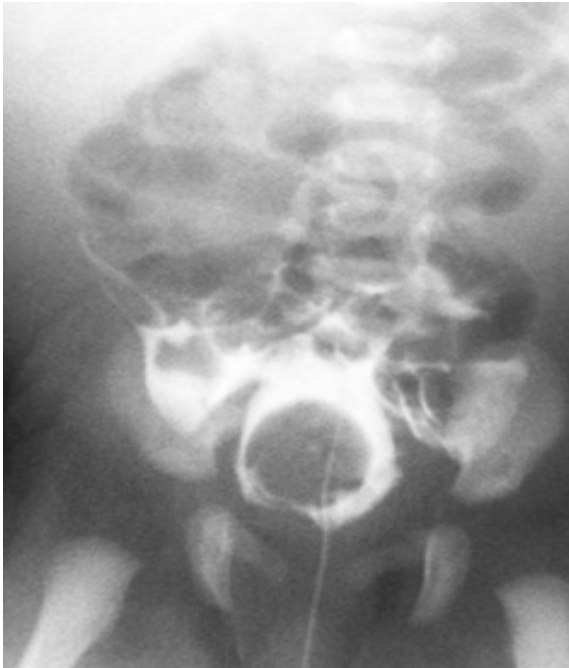
bladder perforations occurring as a complication of the procedure [2,3]. One review reported about 75% cases of bladder perforations was secondary to umbilical artery catheterization [2]. However, the condition can have varied etiology. From available existing literature, neonatal bladder perforations can etiologically be categorized into four broad groups: those occurring following umbilical artery catheterization, perforations following bladder instrumentation (e.g. bladder catheterization) [4], those occurring in patients with bladder abnormalities like posterior urethral valves, neurogenic bladder, congenital bladder diverticulum, and rarely anterior urethral valve [5], and spontaneous idiopathic bladder perforations [5-10]. There are isolated reports of bladder perforations occurring secondary to necrotizing enterocolitis [11] and secondary to severe UTI [12].

Idiopathic bladder perforation is relatively uncommon cause of neonatal urinary ascites with only isolated case reports [5-10]. The entity most commonly observed in preterm neonates and supposed to be ischemic in origin. Here, we describe a full-term female neonate with urinary ascites secondary to spontaneous bladder perforation who was successfully managed with early operative intervention.

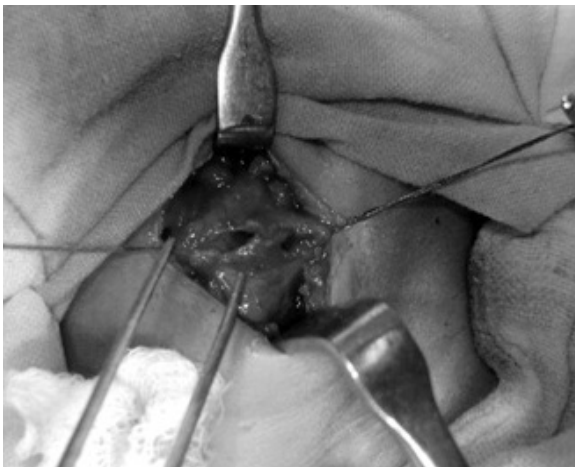## CASE REPORT

A full term, 2.7 kilograms female neonate presented on fifth day of life with progressive abdominal distension and failure to pass urine since birth. Prenatal history and antenatal sonogram at 28th week of gestation was unremarkable. There was no previous attempt of bladder or umbilical vessel catheterization. Baby cried well after birth and there was no history of any hypoxic event. On examination, the baby was hemodynamically stable but had marked abdominal distension. There were no other contributory findings. Her blood urea and creatinine levels were 49.7 mg% and 1mg% respectively. Initial catheterization with no. 6-infant feeding tube drained 300 ml of clear urine which relived abdominal distension completely. Urine was sterile. Subsequent ultrasonography showed normal kidneys with ascites and infant feeding tube was seen passing through bladder up to inferior pole of spleen. Voiding cystourethrography (VCUG) showed free flow of contrast medium into peritoneum through intra-peritoneal perforation (Fig. 1).

Considering a large defect on VCUG, immediate laparotomy was performed. There were two side-by-side perforations on posterior aspect of bladder dome with thinned out surrounding bladder wall (Fig.2).



**Fig. 1.** Cystogram showing extravasation of contrast from bladder into peritoneum.



**Fig. 2.** Intraoperative photograph showing two large side-by-side perforations on the posterior aspect of bladder dome.

Closure of perforation was done in two layers. Supra-pubic catheter was placed and thorough peritoneal wash was given. Histopathology of excised margin of bladder

wall revealed necrotic fibro-muscular wall with denuded bladder urothelium, submucosal edema and leukocyte infiltrates in all layers. Her postoperative period was uneventful. She was on full diet at earliest. Follow up VCUG done on 14th day showed no extravasation. Supra-pubic catheter was removed. She was perfectly normal in six month follow up.

### DISCUSSION

Idiopathic bladder perforation in newborns is exceedingly uncommon entity. Even after an extensive search of available English literature we can trace only fourteen cases of this condition [5-10]. Patient related variables in this cohort were peculiar. No information is available regarding the gestational age of three previously published cases but nine of eleven babies with known gestational age were preterm. Of eight patients whose birth weight were known, only one had birth weight more than 2.5-kg, like our patient. It is peculiar to note that both these good birth weight babies with bladder perforation had complaints since birth. While the time of presentation varied from day-1 to day-24 in preterm babies. The condition appears to affect both sexes equally.

Profound hypoxia, birth trauma, and urinary retention with raised vesical pressure, can be

the predisposing conditions. The most accepted explanation for spontaneous bladder rupture is prolonged exposure to hypoxia resulting in ischemic visceral damage to bladder, leading to perforation [9]. In our case bladder rupture must have occurred perinatally as antenatal sonogram at 28 weeks gestation was normal and also baby was well preserved and BUN/serum creatinine were not grossly deranged. During operative exploration no bladder pathology capable of inducing rupture was detected. Also, there was no history of any hypoxic episode. Thus it was an idiopathic presentation.

Only Morrell et al. [8] has previously described the histological appearance of such bladder which classically showed ischemic injury without intramural inflammation. Histopathology in our case was consistent with those described by Milles [13]. He proposed pressure necrosis as the pathological mechanism for bladder perforations. Crede's maneuver for prolonged urinary retention has been reported to cause similar perforations [14].

The diagnosis of urinary ascites in a neonate can be challenging and must be considered in neonatal ascites and renal failure until proven otherwise. Ultrasound in some cases, as in our case, may reveal ascites with the lesion to the bladder wall. VCUG remains

the most valuable technique for demonstrating bladder perforation and associated other bladder pathologies.

The optimal management of neonatal bladder rupture has yet to be defined. It has been suggested that the management is dependent upon the mode of injury and whether the defect is intraperitoneal or extraperitoneal. In either case the mortality and morbidity can be reduced by early recognition and management. It has been suggested that extraperitoneal ruptures can be managed with catheter drainage, but intraperitoneal ruptures mandate laparotomy and repair. If a large perforation is demonstrated on VCUG, early surgery not only takes care of urinary leak but also reduces the convalescence period. The choice of bladder drainage postoperatively would likely be a temporary suprapubic tube, but in patients with neurogenic bladder, outlet obstruction, and/or significant hydronephrosis, a vesicostomy may be planned.

Diamond and Ford reported a mortality of 18% among bladder ruptures from umbilical artery catheterization [2]. However, Spontaneous bladder perforation appears to have better prognosis as only one patient in this group has expired and there is no long term reported morbidity.

To conclude, spontaneous bladder perforation, though rare should be considered in differential diagnosis of neonates with ascites with oliguria. Early

and prompt intervention results in favorable outcome.

## REFERENCES

1. Griscom NT, Colodny AH, Rosenberg H K, Fliegel CP, Hardy BE. Diagnostic aspects of neonatal ascitis: report of 27 cases. *AJR Am J Roentgenol.* 1977; 128(6):961-9.
2. Diamond DA, Ford C. Neonatal bladder rupture: a complication of umbilical artery catheterization. *J Urol.* 1989; 142(6):1543-4.
3. Dmochowsky RR, Crandell SS, Corriere JN. Bladder injury and uroascitis from umbilical artery catheterization. *Pediatrics.* 1986;77(3):421-2.
4. O'Brien WJ, Ryckman FC. Catheter induced urinary bladder rupture presenting with pneumoperitoneum. *J Pediatr Surg.* 1994;29(10):1397-8.
5. Upadhyaya VD, Gangopadhyaya AN, Pandey A, Gupta DK. Neonatal urinary ascites from idiopathic rupture of the bladder. *The Internet Journal of Urology.* 2007;5(1):1-4.
6. Murphy D, Simmons M, Guiney EJ. Neonatal urinary ascites in the absence of urinary tract obstruction. *J Pediatr Surg.* 1978;13(6):529-31.
7. Trulock TS, Finnerty DP, Woodard JR. Neonatal bladder rupture: case report and review of literature. *J Urol.* 1985;133(2): 271-3.
8. Morrell P, Coulthard MG, Hey EN. Neonatal urinary ascites. *Arch Dis Child.* 1985;60(7):676-8.
9. Limas C, Soultanidis C, Deftereos S Skordala M, Sigalas J. A case of spontaneous rupture of the bladder. *The Turk J Pediatr.* 2007;49(2):196-8.
10. Vasdev N, Coulthard MG, De la hunt MN, Starzyk B, Ognjanovic M, Willetts IE. Neonatal urinary ascites secondary to urinary bladder rupture *J Pediatr Urol.* 2009;5(2):100-4.
11. Swanson J R, Ciambotti J M, Rodgers B M, Roth J A, Gordon P V. Bladder wall necrosis in an extremely low-birth-weight infant: a thought-provoking complication of necrotizing enterocolitis. *J Pediatr Surg.* 2004;39(4):623-5.
12. Tran H, Nguyen N, Nguyen T. Neonatal bladder rupture. *Indian J Pediatr.* 2009;76(4):427-9.

## Acknowledgements

The author(s) declare that they have no competing interests and financial support.

13. Milles G. Catheter-induced hemorrhagic pseudopolyps of the urinary bladder. JAMA. 1965;193:968-9.
14. Roth DR, Krueger RP, Barraza M. Bladder disruption in the premature male neonate. J Urol. 1987;137(3):500-1.

**Access this article online**

<http://pediatricurologycasereports.com>

**Quick Response Code**

