

Xanthogranulomatous pyelonephritis in pediatric patients: A case report and literature review

Carolina Talini¹, Leticia Alves Antunes¹, Bruna Cecília Neves de Carvalho¹, Douglas Fagundes Teixeira¹, Michael Malca Sepúlveda², Murilo da Silva Padilha², Maria Helena Camargo Peralta del Valle^{1,2,3}

¹Hospital Pequeno Príncipe, Curitiba/PR, Brasil

²Departamento de Medicina, Universidade Estadual de Ponta Grossa/PR, Brasil

³Universidade Federal do Paraná, Curitiba/PR, Brasil

Abstract

Xanthogranulomatous pyelonephritis (XGPN) is a rare and severe variation of chronic pyelonephritis characterized by suppurative destruction of renal parenchyma and its substitution with chronic inflammatory infiltrate. Male, 8 years old, admitted to the pediatric urology service at 7 years of age, with bladder and renal lithiasis. First symptoms started when he was 2 years old but presented no relapse until he turned 7 years old. During two years, he had recurrence of renal lithiasis and underwent multiple surgical procedures. He remained asymptomatic for a short period of time and when presented fever and urinary symptoms again and underwent CT scanning that demonstrated left kidney enlargement associated with calculi and air bubbles in its interior, suggesting xanthogranulomatous pyelonephritis. Urethrostomy was performed and the patient had good clinical improvement. Renal exclusion was documented through scintigraphy and total left nephrectomy was performed, with a large amount of pus drained. Histopathology confirmed XGPN diagnosis. One year after surgery, there has been no recurrent renal lithiasis or urinary tract infection. Despite being a rare condition in children, XGPN has great importance as it can be often confused with pediatric renal tumors. Early diagnosis is important in order to promote better survival and clinical outcomes.

Keywords

Xanthogranulomatous pyelonephritis; diagnostic imaging; children.

Copyright © 2016 [pediatricurologycasereports.com](http://www.pediatricurologycasereports.com).

Corresponding Author: Maria Helena Camargo

Peralta del Valle. Departamento de Medicina,
Universidade Estadual de Ponta Grossa/PR, Brasil

E-mail: mhperalta@gmail.com

Accepted for publication: 22 Jun 2016

Introduction

Xanthogranulomatous pyelonephritis (XGPN) is a rare and severe variation of chronic pyelonephritis with poorly understood etiology. It is usually associated with recurrent urinary tract infections and renal calculi causing obstructive uropathy. The disease process is characterized by the suppurative destruction of the renal parenchyma and surrounding tissues and replacement with lipid-laden macrophages [1-3]. The first pediatric case was described in 1963. XGPN can involve the entire kidney or may be localized, mimicking a renal tumor [4]. Most of XGPN cases were diagnosed by histopathologically after nephrectomy, because the clinical and radiologic features are difficult to describe [5]. It was found in about 0,6 % of histologically documented chronic pyelonephritis cases, and accounts of 19,2% of pyelonephritis nephrectomies [6,7]. This article aims to report a rare case of XGPN in a pediatric patient, diagnosed after multiple episodes of renal lithiasis and multiple urinary tract procedures.

Case Reports

EAS, 8 years old, first admitted to the pediatric urology service in 2013 with bladder and renal lithiasis. First symptoms

started when he was 2 years old, when he spontaneously expelled two calculi. Since then, no symptoms or other calculi were detected. In 2013, when he was 7 years old, he was referred to our service and underwent endoscopic nephrolithotripsy due to left renal lithiasis. Six months later, he was readmitted with hydronephrosis and fever, and underwent pigtail catheter insertion and parenteral antibiotic treatment. Twenty days after pigtail catheter removal, left ureterolithotripsy was performed and a new pigtail was placed. As the patient presented good outcome, the pigtail catheter was removed 30 days after the intervention.

In the first semester of 2014 he returned with fever and urinary symptoms, and workup showed calculi and hydronephrosis in left kidney again [Fig. 1,2], this time with renal lithiasis also on right kidney.

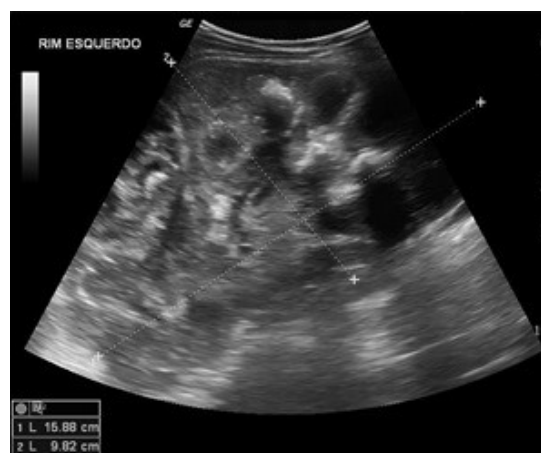

Fig. 1. Abdominal ultrasound – left kidney hydronephrosis, measuring 15,88 x 9,82cm.

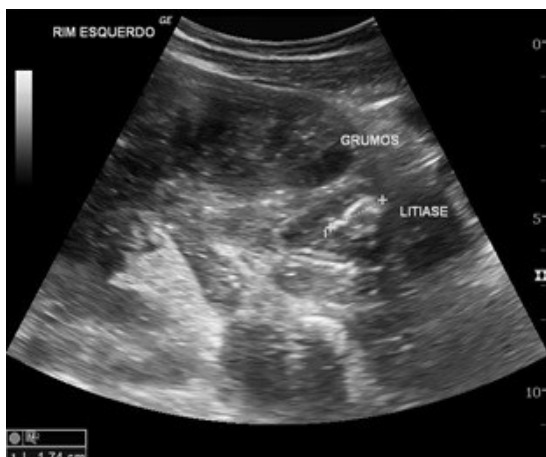

Fig. 2. Abdominal ultrasound – debris in collector system and hyperechogenic image with acoustic shadow - staghorn calculus measuring 1,74 cm.

Urine culture was positive (*Proteus mirabilis* > 100.000 UFC/mL), and patient was treated again with pigtail insertion and antibiotics. Two weeks after hospital discharge, he returned to the emergency service with urinary tract infection symptoms. New ultrasound was performed and suggested pyonephrosis. CT scan was performed [Fig. 3].

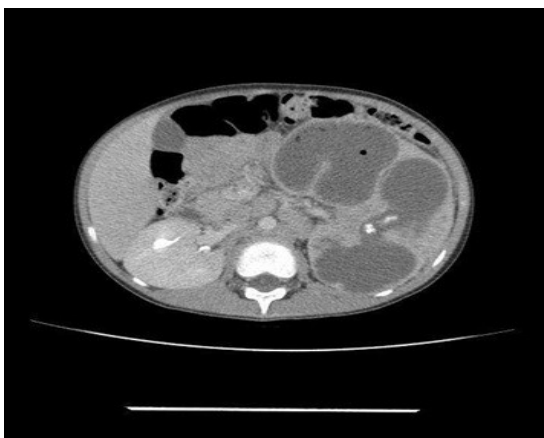


Fig. 3. CT scan demonstrating left kidney enlargement associated with calculi and air bubbles in its interior, suggesting xanthogranulomatous pyelonephritis.

Due to the clinical conditions and great amount of pus inside the left kidney collector system, decision was taken to perform external drainage of the renal pelvis. Urethrostomy was performed and the patient had good clinical improvement [Fig. 4].

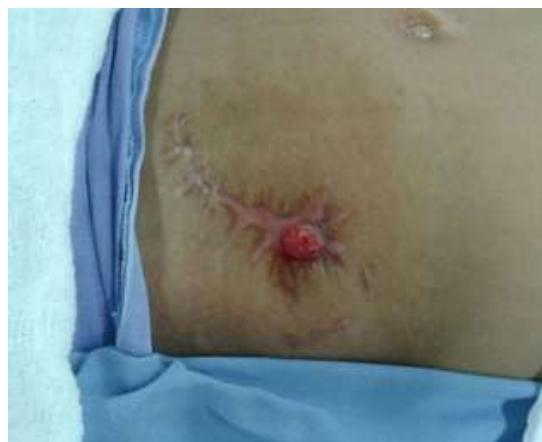

Fig. 4. Final abdominal aspect after urethrostomy surgery.

In order to continue investigation, a scintigraphy was performed and functional exclusion of left kidney was demonstrated. According to current literature and existent protocols, the attending surgeon decided to perform total left nephrectomy. A large amount of pus was drained and the kidney measured about 14 cm in length [Fig. 5].

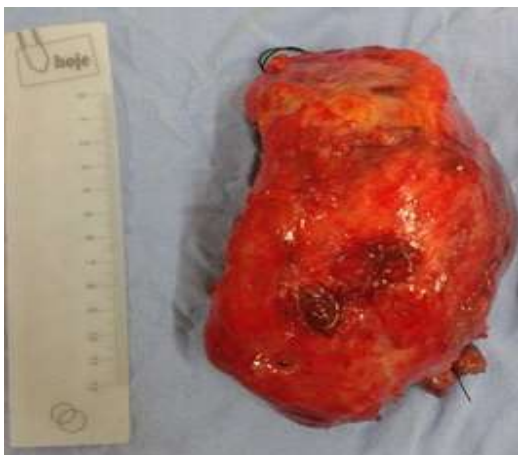

Fig. 5. Product of total left nephrectomy.

Histopathology confirmed XGPN diagnosis. The patient had good evolution after surgery and was discharged from hospital two weeks after the procedure. The patient remains in follow up with nephrologist and urologist, with good outcome at this time. One year after surgery, there has been no recurrent renal lithiasis or urinary tract infection.

Discussion

This case report is about an 8-year-old male patient with XGPN. As he presented multiple renal lithiasis and recurrent urinary tract infections XGPN was a suspected diagnosis, but that was only confirmed after multiple procedures and urinary tract manipulation.

XGPN is a chronic disease that affects more often adults with higher prevalence in females. It is usually unilateral and most frequent on the left side [8,9]. Little is

known about the etiology but it is related to chronic obstruction and recurrent urinary tract infections by *Proteus mirabilis* and *Escherichia coli*. It is a rare condition in children. Most common symptoms are fever, abdominal pain, palpable mass, anorexia, antibiotic-resistant urinary tract infection, hematuria and dysuria [10]. This patient in particular did not have lower urinary tract symptoms, but in physical examination there was pain and palpable mass in left flank.

Laboratory studies can demonstrate anemia, leukocytosis, increased erythrocyte sedimentation rate, changes in liver function tests and pyuria on urinalysis. This patient had all those alterations except for liver function and erythrocyte sedimentation rate – those exams were not performed because they are not part of the hospital protocol.

Preoperatively diagnosis is difficult. The best imaging study is CT scan. Some authors suggest that ultrasound can be used as the first line exam in the investigation. Beside those tests that suggested XGPN diagnosis, this patient also underwent renal scintigraphy that showed functional absence of left kidney. He presented the classical triad reported by Arvind [11]: inflammatory mass, nonfunctional kidney and presence of calcification. Reported signs of XGPN in CT scanning are hydronephrosis, renal lithiasis, pyonephrosis, intraparenchymatous collection,

renal failure, abscess and increase in perirenal fat [11,12]. Some of these signs were present in this patient's CT scan.

Definitive diagnosis is determined by histopathology: granulomatous inflammatory infiltrate with xanthomatous histiocytes, neutrophils, lymphocytes, plasma cells and giant multinuclear cells [13]. All these findings were present in this patient's pathological study.

Surgery is considered the gold standard treatment. Total nephrectomy associated or not with antibiotic therapy is treatment of choice for the diffuse form, while the localized form can be treated with partial nephrectomy and antibiotic therapy. There are reports in which the localized form was treated nonoperatively with good results, but in those particular cases renal function was intact and XGPN was bilateral. Antibiotic treatment before and after surgery is related to treatment success [14]. This patient underwent total nephrectomy due to functional loss of the kidney, received parenteral antibiotic treatment before and after surgery and had a good outcome. Unfortunately this disease is associated with high rates of renal loss, as by the time of diagnosis there is not much to do in order to

save the kidney. This report shows an experience with a patient that lost his kidney due to XGPN. Maybe if he had earlier diagnosis, for example when he started manifesting urinary symptoms and renal lithiasis, adequate treatment could have been established earlier and there might have been a chance to save the kidney.

Conclusion

Despite being a rare condition in children, XGPN has great importance as it can be often confused with pediatric renal tumors. Technological advances in imaging studies, particularly in CT scanning, and a high index of clinical suspicion lead to correct diagnosis and preoperative staging. Diagnostic confirmation requires histopathology. Treatment of choice still is nephrectomy. According to current literature, early diagnosis is important in order to promote better survival and clinical outcomes.

Acknowledgements

The author(s) declare that they have no competing interests and financial support.

References

1. Pastore V, Niglio F, Basile A, et al. Laparoscopic-assisted nephroureterectomy for shaped urolithiasis and xanthogranulomatous pyelonephritis: case report and review of literature. *Afr J Paediatr Surg.* 2013;10(3):285–8.
2. Berenguer A, Pilar C, Smit M, Nunes JL. Xanthogranulomatous pyelonephritis presenting as a pseudotumour in a 5-year-old boy. *BMJ Case Rep.* 2012;12;2012. pii: bcr2012006920.
3. Ghoz HM, Williams M, Perepletchikov A, James N, Babeir AA. An unusual presentation of xanthogranulomatous pyelonephritis: psoas abscess with renocolic fistula. *Oxf Med Case Reports.* 2016;2016(7):150-3.
4. Tüysüz G, Tayfun F, Canpolat F, Zeytun H, Goya C, Keleş AN, Özdemir N. A case of xanthogranulomatous pyelonephritis mimicking Wilms tumor. *Turk J Pediatr.* 2015;57(4):409-412.
5. Nam JK, Park SW, Lee SD, Chung MK. Xanthogranulomatous pyelonephritis in Korean children. *Yonsei Med J.* 2012;53(6):1159-64.
6. Filho VNH, Filho FAW, Souza HAM, Leal TA, Luciano A. Pielonefrite Xantogranulomatosa. *J Pediatr (Rio J).* 1994;70(5):302–304.
7. Zugor V, Schott GE, Labanaris AP. Xanthogranulomatous Pyelonephritis in Childhood: A Critical Analysis of 10 Cases and of the Literature. *Urology.* 2007;70(1):157–60.
8. Li L, Parwani A V. Xanthogranulomatous Pyelonephritis. *Arch Pathol Lab Med.* 2011;135(5): 671-4.
9. Brown PS, Dodson M, Weinrub PS. Xanthogranulomatous Pyelonephritis: Report of Nonsurgical Management of a Case and Review of the Literature. *Clin Infect Dis.* 1996;22(2):308–14.
10. Rodrigues WM, Carolina A, Gonçalves DA, Sakamoto S, Sato MH, Fucci A. Pielonefrite xantogranulomatosa - relato de caso. *Arq Med Hosp Fac Cienc Med Santa Casa São Paulo.* 2009;54(2):76–80.
11. Arvind NK, Singh O, Ali Q, Gupta SS, Sahay S. Laparoscopic nephrectomy in xanthogranulomatous pyelonephritis: 7-year single-surgeon outcome. *Urology.* 2011;78(4):797–801.
12. Kim SW, Yoon B Il, Ha U-S, Sohn DW, Cho Y-H. Xanthogranulomatous pyelonephritis: clinical experience with 21 cases. *J Infect Chemother.* 2013;19(6):1221–4.
13. Buttice S, Antonino I, Giorgio A, Valeria B, Stefano P, Giuseppe M, et al.

- Xanthogranulomatous Pyelonephritis Can Simulate a Complex Cyst: Case Description and Review of Literature. Urol Case Reports. 2014;2(3):113–5.
14. Hussein N, Osman Y, Sarhan O, El-Diasty T, Dawaba M. Xanthogranulomatous Pyelonephritis in Pediatric Patients: Effect of Surgical Approach. Urology. 2009;73(6):1247–50.

Access this article online

<http://pediatricurologycasereports.com>

Quick Response Code

