



Pediatric penoscrotal degloving injury by a cordless drill: A case report and literature review

Bahiyah Binti Abdul Jabar, Ariffuddin Bin Ishak*

Department of General Surgery, Hospital Tengku Ampuan Afzan, 25100 Kuantan, Pahang, Malaysia

ABSTRACT

To report a case of pediatric penoscrotal injury and review of the literature for similar cases to evaluate the prevalence, etiology of injuries, methods of reconstruction, surgical complications and end results.

Key Words: Degloving, pediatric penoscrotal, laceration

✉ Bahiyah binti Abdul Jabar

Department of General Surgery, Hospital Tengku Ampuan Afzan, 25100 Kuantan, Pahang, Malaysia

E-mail: bahiyahjabar3@gmail.com

Received: 2021-04-26 / Accepted: 2021-05-10

Publication Date: 2021-05-17

Introduction

Penoscrotal degloving injury is a rare surgical emergency [1]. These injuries normally only reach the skin, causing minimal bleeding without producing damage to the cavernous body or the testes. Machines or equipment such as pulleys, chains and rotary discs, are responsible for genital injury, when they are in direct contact with the organ or snagging the operators' clothes and pull out the skin of the penis and scrotum [2]. We present a unique case of pediatric degloving injury caused by cordless drill.

Case presentation

A 2-year-old Malay boy was playing with his father's cordless drill at home alone when his trousers were caught into the drill bit whereby penile and scrotal skin entrapped in the trousers. His mother panicked and pulled the cordless drill. On our examination, the penile skin was stripped from the base and hanging over the corona sulcus with minimal bleeding noted from the degloved skin. Penile shaft was found to be swollen with superficial laceration wound over the right scrotum. Patient was rushed to the operating theatre for exploration under general anesthesia.

Results

Intraoperatively, the penile corpora were uninjured and the penile skin circumferentially degloved from the base until the corona sulcus of glans (Fig 1). Glans penis and urethra were preserved. There is also a linear laceration wound over right scrotum measuring 1.5cm. Foley catheter size 10 was inserted to establish urinary outflow. The degloved skin edges was debrided and left with healthy viable skin. The skin over penis and scrotum was approximated with absorbable suture in interrupted manner (Fig 2 and 3). Dressing was done as per full thickness skin graft protocol.

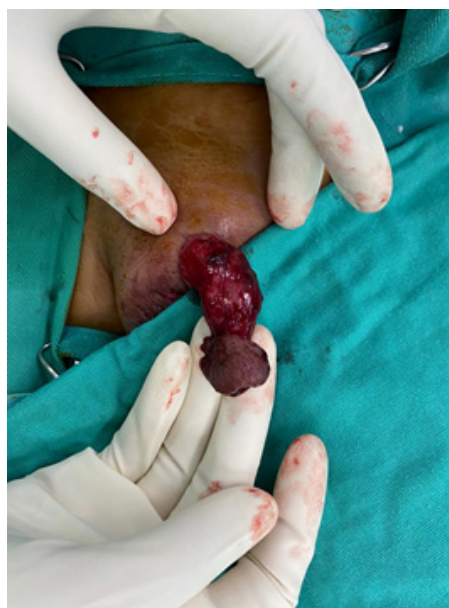

Fig. 1. Pre-operative findings show penile skin circumferentially degloved from its base up to the corona.

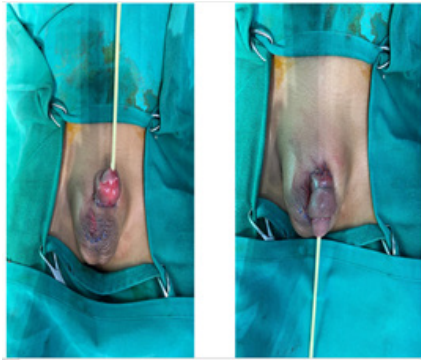


Fig. 2. (Left) and Fig 3 (Right): The avulsed skin flap is reduced and sutured over the base after unhealthy skin flap debrided. Superficial laceration wound over right scrotum sutured in a single layer.

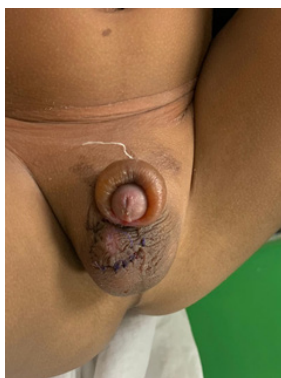

Fig. 3. Wound inspection on day 5 showed the penis foreskin appeared swollen with pink glans.

Day 5 post operation, during wound inspection, the penis appeared mild swollen with pink glans. The skin otherwise well and healthy (Fig 4). Patient was discharged after one week of hospitalization.

A 2- month follow up shows a normal penis with no

contracture and no skin necrosis. The scrotum was also healed with minimal scar. Urinary flow was uninterrupted and parents were satisfied with the cosmetic outcome. (Fig 4).



Fig. 4. A 2-month follow up shows a normal penis without edematous skin or contracture. The scrotum was also healed with acceptable scar.

Method: A literature review was done using PubMed and Google Scholar by searching the keyword “degloving”, “penis”, “scrotum” and “pediatric”. The articles are reviewed by taking note of the causes, modalities of treatment, complications and end result done in each case. Articles were also searched based on the list of references in these articles. The results were presented and summarized into a table (Table 1).

Results: A total of 9 reports on degloving penile injury in pediatric age group (from birth to 18 years old) were found dating from year 2000 to 2020. 3 cases (33.3%) of penoscrotal degloving injury were caused by dog bite, 2 cases (22.2%) were due to motor vehicle accident, 2

Table 1. Report on prevalence of degloving penoscrotal injury in pediatric population, treatment and complications over 20 years period from year 2000-2020.

Number	Author, Year	Age	Cause of Injury	Treatment	Complication	End result
1	Sarin, Y. K., Sinha, A., & Ojha, S. (2004)	9 years old	Motor vehicle accident	Primary closure	-	- Normal voiding
2	Sarin, Y. K., Sinha, A., & Ojha, S. (2004)	10 years old	Motor vehicle accident	Split skin graft with posterior flap of scrotal skin	Necrosis	- Acceptable cosmesis
3	Mathur, R. K., Lahoti, B. K., Aggarwal, G., et al (2010)	8 years old	Dog bite	Primary closure	-	Normal penis, no phimosis, no skin necrosis
4	Kiffin, C., Porcelli, M., Prychyna, O., et al (2012)	17 years old	Dog bite	Primary closure	Flap necrosis Proceed with FTSG	- Not stated
5	Kihiko, D. K. (2012)	12 years old	Domestic injury by father	Primary closure and scrotal flap	Mild painful erection	- No cicatrification, minimal scarring, cosmetically good results - Preserved sensitivity to touch

6	Onumaegbu, O. O., & Okechukwu, O. C. (2015)	10 years old	Milling machine	Full thickness skin graft	Graft loss	- Patient loss to follow up
7	Anastasiadis, K., Kepertis, C., Sfoungaris, D., et al (2019)	10 years old	Sports injury (Bicycle chain)	Primary closure	-	- Good urinary flow - No erectile dysfunction
8	Thompson, H., Burdall, O., & Lakhoo, K. (2019)	14 years old	Sports injury (Handlebar)	Primary closure	-	- Normal voiding, normal sensation
9	Raina, P., Sharma, G. K., Barwal, K. C., et al (2020)	11 years old	Dog bite	Primary closure	Swelling, edema	- Minimal scarring - No urinary complaint

cases (22.2%) by sports injury, 1 case (11.1%) each by domestic injury and one case (11.1%) caused by machinery. For the treatment done, 6 cases (66.6%) were treated with primary closure, 2 cases (22.2%) were treated with multimodal approach using primary closure and scrotal flap and one case (11.1%) with full thickness skin graft. Amongst all the modalities of treatment, one case (16.6%) treated with primary closure was complicated with skin necrosis.

Report on prevalence of degloving penoscrotal injury in pediatric population, treatment and complications over 20 years period from year 2000-2020.

Discussion

The penis is a vital male organ which functions to channel urine and semen out of the body. Subcutaneous tissue for penis is made by areolar tissue, deep fascia (Bucks' fascia) and superficial fascia (Dartos' fascia) and lastly the penile skin. The Dartos fascia attached freely to the underlying Buck's fascia which makes them glide easily onto the Buck's fascia and exposed the penis to soft tissue injury. The skin of the penis is lax and flexible [3-4]. This characteristic allow penis to maintain its erect and flaccid state and at the same time render it vulnerable to degloving injuries [4].

Penile injury is uncommon because the penis is largely guarded by its' position. Genital injury in pediatrics made up 0.6% of all pediatric injury[10]. Most of the cases manifested as laceration (43%), followed by abrasion and contusion (42%) [10]. Degloving penile injury in pediatric age group has various causes and forms which is different from adults[5].It may be caused by botched circumcision, pet attack, mistreatment by parents or caregiver, automobile accident, zipper injury

and penile strangulation by thread or hair [6-10]. Penile degloving injury frequently happen when operating rotary-type machine typical distinctly found in farming and industrial machinery described as power take-off injury [1]. The rotary mechanism entrapped loose clothing together with lax penile skin tearing it causing avulsion injury [1,9].

Our case demonstrated total penile skin degloving injury from its base extending to corona. Proximal skin flap was crushed a few millimeters. After adequate debridement until bleeding skin edge, the residual skin still adequate to close the wound without causing anatomical distortion. By utilizing patient's own penile skin flap we manage to preserve and achieve good and excellent cosmesis result.

In managing a case of degloving penoscrotal injury, various treatment methods are available. These methods can be of single modality or multimodal that are individualized for each patient based on the type and severity of injury, age, time passed, causative agent and associated trauma contributing to the injury [1,7]. The aim of treatment in penoscrotal injury is resuscitation, re-establish normal urinary and sexual function with the best cosmetic outcome [1]. Urgent referral to surgeon in charge of these injuries is indicated to achieve good results [1]. A meticulous debridement and irrigation play an essential role in the operation which aims to remove the unhealthy tissue and preserve the viable skin for primary closure and grafts for reconstruction to achieve acceptable results and reduce further morbidity [1,3]. Degloved penoscrotal wound is best reconstructed using the patient's avulsed skin if achievable provided there is no delay in treatment which reduced the viability of tissue, thus minimizing the opportunity for simple reconstruction using avulsed tissue flap [4].

Skin graft are frequently used as they are simple and can cover wound of any sizes from small to large defect [11]. However, they are known to have complications such as altered sensitivity, lymphoedema, contracture, stiffness and unstable scars which can affect patient's sexual function such as erectile pain, and erectile dysfunction due to suboptimal coverage of the penis to accommodate its function both during lax and during erection [5,11]. Grafts can also be esthetically unacceptable as it often results in volume deficiency [11]. Thus, with the increase risk of complication as compared to primary closure, skin graft should only be used in cases whereby the original genital skin is irreparable [5].

Split thickness skin graft is a simple procedure in which the graft can be harvested easily and can easily survive [13]. Full thickness skin graft is superior than split thickness skin graft both in functional and aesthetic value [4]. Apart from being cosmetically desirable, full thickness skin graft is more elastic, has better quality and texture, more resistant to trauma and has less risk from developing contracture [4,12]. These will reduce the potential for shortening or phimosis and painful erections [4]. Nevertheless, the difficulty to harvest graft with less chance of graft survival are the biggest drawback of full thickness skin graft [4,13].

Scrotal flap is another alternative to cover the penile shaft and primary closure can be attained if up to 50% of scrotal skin is lost [7]. The scrotal skin validates its status as the most suitable reconstructive option for penile shaft skin defect which contributes to cosmetic and practical benefit as compared to other reconstructive options such as skin grafts, local flap and free flap [11]. Scrotal flap has the same skin color and quality as the real penile skin and provide a stable and flexible skin enabling it to withstand erection and friction as per original penile skin with no risk of contracture [11,13]. The major drawback for scrotal flap is transposition of scrotal hair onto penile shaft and simultaneously reduce the scrotal size [13-14]. Scrotal reconstruction includes banking testicles in the medial thigh pocket and the usage of tissue expander to obtain extra tissue for

enveloping the testes can result in better outcome than split skin grafting but require prolonged time to achieve desirable result [7].

Conclusion

Degloving penoscrotal injury in a pediatric population is quite uncommon. Various etiologies can contribute to the pattern of the injury. Nonetheless, most of these etiologies considered preventable. The method of reconstruction is best achieved when using the remaining viable tissue. The end result usually excellent unless erectile tissue, neurovascular bundle and urinary flow are affected.

References

- [1] Shah SA, Khan F, Aslam M, et al. Penoscrotal degloving and amputation injuries. *Pakistan J Surg.* 2011;27(1), 18-23.
- [2] Mathur RK, Lahoti BK, Aggarwal G, Satsangi B. Degloving injury to the penis. *Afr J Paediatr Surg.* 2010; 7:19.
- [3] Sarin YK, Sinha A, Ojha S. "Snapped in" penis: An unusual presentation of degloving injury of the penis. *Indian J Urol.* 2004; 20: 56-57.
- [4] Kiffin C, Porcelli M, Prychyna O, et al. Penile Degloving Injury in an Adolescent with Congenital Hypothyroid. *Case Rep Med.* 2012; 2012: 464670
- [5] Kihiko DK. Degloving Penile Trauma In A 12 Year Old Boy: Case Report. *Ann Afr Surg.* 2012; 9.
- [6] Onumaegbu OO, Okechukwu OC. Isolated penile degloving from milling machine injury in a child. *Ann Med Health Sci Res.* 2015; 5: 139-141.
- [7] Anastasiadis K, Kepertis C, Sfoungaris D, Spyridakis I. Injury of the external genitalia in 10-year-old boy. *Afr J Paediatr Surg.* 2019; 16:35-37.
- [8] Thompson H, Burdall O, Lakhoo K. Degloving injury to groin, scrotum and penis due to low-velocity handlebar injury. *BMJ Case Rep.* 2019; 12.
- [9] Raina P, Sharma GK, Barwal KC. Penile Degloving injuries, a quagmire riddled out: A case series. *Int. j. med. health res.* 2020; 3: 28-32.

- [10] Casey JT, Bjurlin MA, Cheng EY. Pediatric Genital Injury: An Analysis of the National Electronic Injury Surveillance System. *Urology.* 2013; 82:1125-1131.
- [11] El-Bahnasawy MS, El-Sherbiny MT. Paediatric penile trauma. *BJU Int.* 2002; 90:92-96.
- [12] Lee HG, Lim SY, Yoon CS, Kim KN. Circumferential penile defect reconstruction with pull-up double-opposing keystone-designed perforator island flaps. *Medicine.* 2020; 99: 18762.
- [13] Fang JJ, Li PF, Wu JJ, Zhou HY, Xie LP, Luet H. Reconstruction of massive skin avulsion of the scrota and penis by combined application of dermal regeneration template (Pelnac) and split-thickness skin graft with vacuum-assisted closure: A case report. *World J. Clin. Cases.* 2019; 7: 4349-4354.
- [14] Putra IB, Wahyudi I, Rodjani A et al. Penile Paraffinoma Reconstruction With Scrotal Flap And Surgical Outcome: A Case Report. *Indonesian J Urol.* 2019; 26.